

Intra Ventricular Migration of External Ventricular Drain Tube

MUHAMMAD SOHAIL UMERANI,¹ AISHA ALHAJJAJ²

ASAD ABBAS,³ GABR AHMED MOSTAFA⁴

Department of Neurosurgery, ^{1,4}King Fahd Military Medical Complex, Dhahran

²Dammam Medical Center, KSA

³Department of Neurosurgery, Jinnah Postgraduate Medical Centre, Karachi, Pakistan

ABSTRACT

Migration of the proximal end of the External Ventricular Drain (EVD) tubing in the ventricular system of a hydrocephalic brain is a rare complication. This event could be multi factorial; and measures, including appropriate careful nursing and securing of the anchoring knot are to be employed to avoid this potential complication. We report a case of an infant with intra ventricular hemorrhage, gross hydrocephalus and fits.

After an initial management with anti-epileptic and repeated fontanelle tap, a Ventriculo. Peritoneal (VP) Shunt was placed which over drained the Cerebrospinal Fluid (CSF); resulting in subdural hygromas. The VP Shunt was replaced with an EVD. On the seventh post-operative day, the Computed Tomography (CT) Scan revealed the proximal intra ventricular migration of the EVD tube with no clinical signs of obstruction. The scalp dressing was removed to reveal that the non-absorbable anchoring knot of the tube had cut through the skin. The EVD tube was pulled till the desired length within the ventricle and was properly anchored. Post procedural CT scans showed the desired length of intra ventricular EVD tube. It is recommended for the neurosurgical nursing staff to be vigilant enough during feeding them and especially while changing posture for nursing to prevent such mishaps. Daily assessment of the wound dressing would assist in insuring a secured knot over the tubing on the scalp.

Keywords: Proximal intraventricular migration, external ventricular drain tube, CT scans.

INTRODUCTION

Placement of CSF diversion construct is a simple neurosurgical procedure, but, immense precaution is required in its every step to prevent untoward complications. Migration of the proximal end of the External Ventricular Drain (EVD) tubing in the ventricular system of a hydrocephalic brain is a rare complication ranging from simple telescoping to complete migration of the tip for example, in the subgaleal space.¹ This event could be multi factorial. Different measures, including appropriate securing of the anchoring knot are to be employed to avoid this potential complication.

CASE REPORT

We report a case of an infant with intra ventricular

hemorrhage, gross hydrocephalus and fits, born via caesarean section. He was managed with anti-epileptic and repeated fontanelle tap.

Later Ventriculo Peritoneal Shunt with medium pressure valve was placed which over drained the CSF with resultant subdural hygromas and ultimately was replaced with External. Ventricular Drain (EVD). Hygromas disappeared, but the EVD was revised twice because of documented bacterial meningitis with antibiotic coverage. The first dressing was changed on the second post-operative day. EVD was functioning adequately and the patient started to improve clinically as well as hemodynamically. Repeat Computed Tomography (CT) scans was done on the seventh post-operative day, which revealed the proximal intra ventricular migration of the EVD tube with no clinical signs of obstruction (Figure 1).

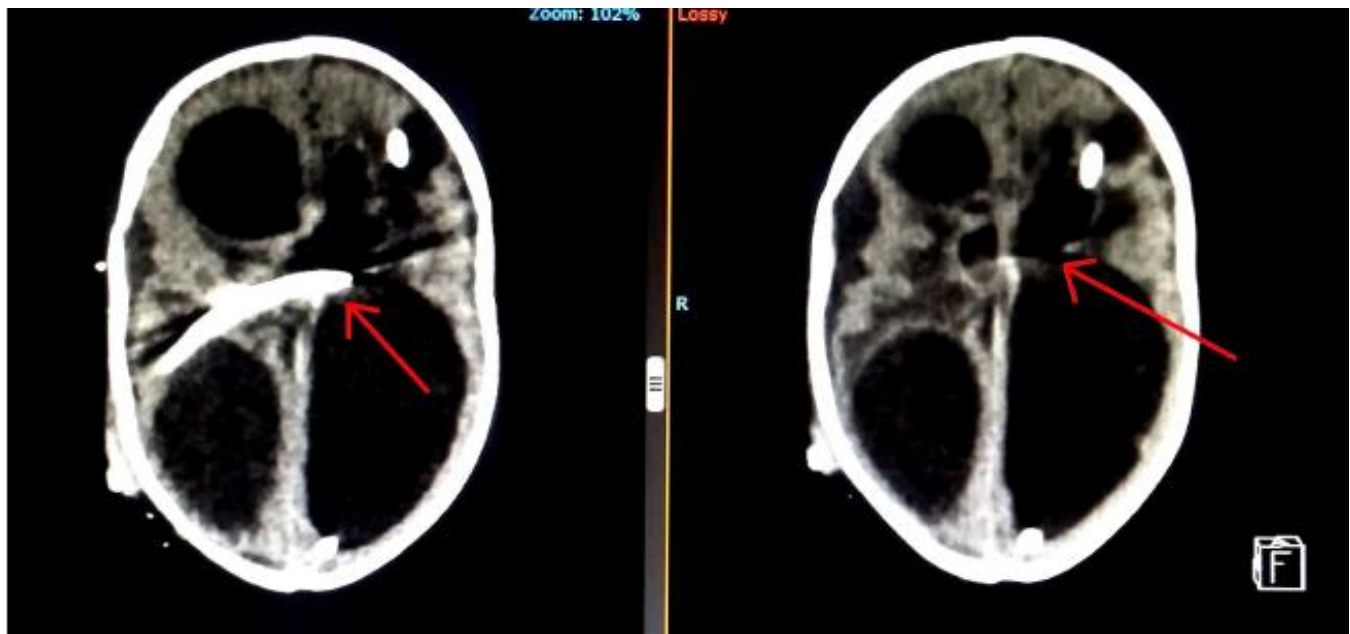


Fig. 1: CT Scan Axial Images Showing Intra Ventricular Migration of External Ventricular Drain tube.

After confirmation of the radiological diagnosis and multi-planar CT scans to detect the migration of tube as seen in Figure 2, the scalp dressing was removed and to our surprise the non-absorbable anchoring knot of the tube had cut through the skin (Figure 3).

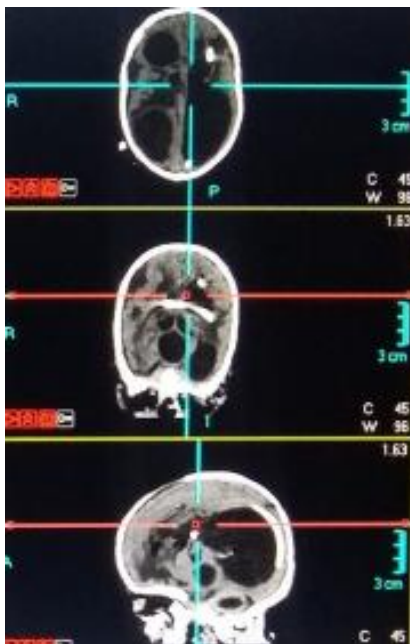


Fig. 2: CT Scan with Multi Planar Reconstruction (MPR) Views of EVD Tube Migration.

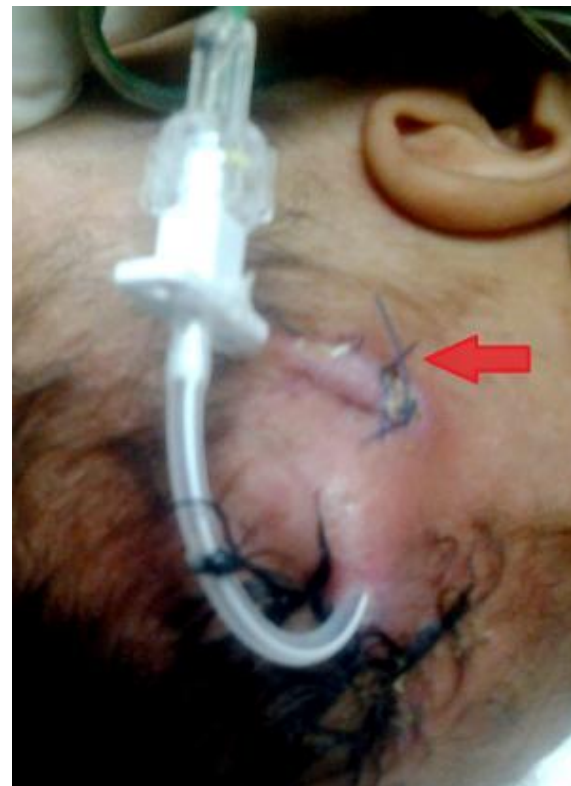

Fig. 3: Anchoring knot of the tube has cut through the skin with proximal migration of EVD tubing.

Soon after under sterile circumstances the EVD tube was pulled till the desired length had remained

within the ventricle and was properly anchored. The patient tolerated the procedure and post-procedural CT scan showed the desired length of intra ventricular EVD tube.

DISCUSSION

There are many complications related to ventricular drainage tubes. Most of them are reported in literature, while few being potential threats are only mentioned in textbooks. Proximal intra ventricular migration of EVD tube is one of them.

Much of the current literature is available is regarding the migration of shunt catheters to various sites, including ventricles, sub dural spaces, pleural and peritoneal cavities and cardiac chambers.¹⁻³ Its proximal migration has been more so intra cranially (intra ventricular) and infrequently in the subgaleal cavity.^{1,4} Partial or complete shunt migration, although being a rare entity, have been seen in the past, with more cases being reported for the uni-shunt system without a reservoir which was introduced by Raimondi.^{5,6} Rarely would they also migrate with a reservoir.² In the literature this experience is quoted to be multi factorial depending upon the diameter of burr hole, the extent of the dural incision and the technique of anchoring the reservoir with the tubing particularly in a growing child. Infants are more prone to this potential complication since they are being nursed in supine position for most of the time and their energetic flexion, extension and lateral movements of the head may facilitate this by acting as a windlass.⁷ This is especially true if there is gross hydrocephalus with widely separated fontanelle, where the high intra-abdominal pressure will cause the proximal migration as now the CSF pressure in the ventricular system is close to the atmospheric pressure.

Intra ventricular migration of the EVD tube requires a potential space with no resistance to movement. This is made available by the dilated ventricles of a hydrocephalic brain; more so if there is improper anchoring of the drain at its exit from the scalp after tunnelling. The extent of migration may vary from simple telescoping of the tube because of improper anchoring to complete migration as a result of anchor-knot cutting through skin. Although theoretically mentioned in text books, but so far, to the best of our knowledge, there is no single case report ever published mentioning the intra ventricular migration of the tip of EVD. There is no age specificity, but can be expected more in pediatric age

group particularly in infancy. This is because of the difference in scalp thickness in both age groups which matters while securing the EVD tube. A modified roman sandal technique has been mentioned in the literature and is commonly used to secure EVD tubing to avoid such a potential complication.⁸

CONCLUSIONS

Proximal intraventricular migration of the tubing of EVD is rare, but fortunately a preventable complication which warrants a daily close observation and meticulous care of the anchored drain tubing site by a dedicated nurse. Although can occur in any age group but is expected more in infants. Due to reduced thickness of scalp in infants, over dissection of the soft tissues for tunnelling the EVD tube should be avoided and tubing should be anchored appropriately with non-absorbable sutures. All neonatal intensive care unit nurses must be trained to care for infants with hydrocephalus undergoing shunt placement. Educating families can also help detect early cases of shunt failure. Much research is warranted to develop appropriate guidelines and improve patient outcome.

Additional Information

Disclosures: Authors report no conflict of interest.

Human Subjects: Consent was obtained by all participants in this study.

Conflicts of Interest: In compliance with the ICMJE uniform disclosure form, all authors declare the following:

Payment/Services Info: All authors have declared that no financial support was received from any organization for the submitted work.

Financial Relationships: All authors have declared that they have no financial relationships at present or within the previous three years with any organizations that might have an interest in the submitted work.

Other Relationships: All authors have declared that there are no other relationships or activities that could appear to have influenced the submitted work.

Address for Correspondence:

Dr. Aasid Abbas

Consultant, Neurotrauma Unit

Department of Neurosurgery

*Jinnah Postgraduate Medical Centre,
Rafiqi Shaheed Road, Karachi
Email: asad.abbas@live.com
Cell: +92 333 3183523*

ROLE OF AUTHORS

Dr. Muhammad Sohail Umerani, Paper Writing.
Dr. Aisha Alhajjaj, Data Collection.
Dr. Asad Abbas, Pictures
Dr. Gabr Ahmed Mostafa, Overall Supervision

REFERENCES

1. Al Hinai QS, Pawar SJ, Sharma RR, Devadas RV: Subgaleal migration of a ventriculoperitoneal shunt. *J Clin Neurosci.* 2006; 13: 666-9. 10.1016/j.jocn.2005.07.020
2. Acharya R, Bhutani A, Saxena H, Madan VS: Complete migration of ventriculoperitoneal shunt into the ventricle. *Neurol Sci.* 2002, 23: 75-7. 10.1007/s100720200029
3. Cerrón-Rojas VR, Vega-Basulto S, Varela-Hernández A, Montejo-Montejo J, Gutiérrez-Muñoz FG: Simultaneous cephalic migration of a ventriculoperitoneal shunt into the intraventricular and subdural spaces. A case report. *Rev Neurol.* 2001, 1: 437-9.
4. Dominguez CJ, Tyagi A, Hall G, Timothy J, Chumas PD: Sub-galeal coiling of the proximal and distal components of a ventriculo-peritoneal shunt. An unusual complication and proposed mechanism. *Childs Nerv Syst.* 2000; 16: 493-5.
5. Raimondi AJ, Robinson JS, Kuwamura K: Complications of Ventriculo-peritoneal Shunting and a Critical Comparison of the Three-Piece and One-Piece Systems. *Pediatr Neurosurg.* 1977; 3: 321-342. 10.1159/000119684
6. Eljamel MS, Sharif S, Pidgeon CN. Total intraventricular migration of unisystem ventriculoperitoneal shunt. *Acta Neurochir Wien.* 1995; 136: 217-8.
7. Scott M, Wycis HT, Murtagh F, Reyes V: Observations on ventricular and lumbar subarachnoid peritoneal shunts in hydrocephalus in infants. *J Neurosurg.* 1955; 12: 165-75. 10.3171/jns.1955.12.2.0165
8. Whitney NL, Selden NR: Pullout-proofing external ventricular drains. *J Neurosurg Pediatr.* 2012; 10: 320-3. 10.3171/2012.7.PEDS1280

Date of Submission: 1-1-2019
Date of Printing: 15-3-2019