

Outcome of Endoscopic Treatment of Intracranial Arachnoid Cysts

AMIR AZIZ, ZUBAIR AHMED KHAN, SHAHRUH RIZVI
TOQEER AHMED, SARFARAZ KHATTAK,* MUHAMMAD ANWAR

Department of Neurosurgery Unit III, Postgraduate Medical Institute, Lahore General Hospital, Lahore
Khyber Medical University, Kohat Institute of Medical Sciences, Kohat

ABSTRACT

Objective: To analyze the outcome of endoscopic treatment of intracranial Arachnoid Cysts.

Materials and Methods: The study was conducted from July 2015 to September 2016 at the department of Neurosurgery Unit III, PGMI, Lahore General Hospital, Lahore. A total number of 13 patients were included in the study of both gender and age range of 05-45 years. Detailed history, neurological examination, preoperative CT and MRI scans were performed in all patients. Karl Storz (Lotta system) endoscope was used in all patients. Postoperative CT scan and follow up MRI scans were done in all patients.

Results: Out of 13 patients, there were 08 (60%) male and 05 (40%) female patients. Their age ranged from 05 - 45 years. The majority of patients in our study were in their second and third decade of life. In this study, the symptomatic relief and reduction in cyst size was gained in most of the patients with minimal recurrence and fewer number of side effects.

Conclusion: Endoscopic treatment Of intracranial Arachnoid Cysts proved to be an effective and a very safe technique, provides the best results, avoids shunt dependency with minimal recurrence and fewer side effects.

Abbreviations: CSF: Cerebrospinal Fluid. ICP: Intracranial Pressure. MRI: Magnetic Resonance Imaging. CT: Computed Tomography.

Keywords: Arachnoid cyst, Endoscopic technique.

INTRODUCTION

Arachnoid cyst is benign intra-arachnoid collections of cerebrospinal fluid (CSF).¹ It is considered as a developmental abnormality of the arachnoid membrane, arising from the splitting and duplication of the arachnoid membrane.² Arachnoid cysts most probably arise from incomplete separations of perimedullary mesh (endomeninx) during the early stages of embryogenesis.³ The natural history of Arachnoid cysts remain to be elucidated although some mechanisms are suggested to explain this phenomenon.^{4,5}

The most Arachnoid cyst is usually asymptomatic and those that become symptomatic usually do so in early childhood.⁶ Their presentation varies with the

location of cyst and often appear mild considering the large size of the cyst. Typical presentations are headache, fit and hemiparesis in middle fossa arachnoid cyst and intracranial hypertension, craniomegaly and developmental delay in suprasellar and diffuse supra or infratentorial cyst with hydrocephalus. The most common locations of Arachnoid cysts are Sylvain fissure followed by cerebellopontine angle, vermian, suprasellar, interhemispheric, cerebral convexity and clival areas.⁷

The exact mechanism of expansion of Arachnoid cyst is still not known, although different theories are postulated to explain this mechanism. Some suggested that expansion of the cyst are due to secretory capacity of arachnoid cells in cyst wall while another suggests

expansion due to the osmotic gradient theory.^{8,9,10} Although ball-valve theory in the expansion of Arachnoid cyst has got road agreement.^{11,12} Arachnoid cyst can be diagnosed by getting CT scan brain plain with or without contrast, MRI brain plain and with IV contrast, DWI and recently cine PC MR imaging.^{13,14,15}

There is a controversy regarding the treatment of Arachnoid cysts. Surgical management is recommended for cases with increased ICP and corresponding clinical sign & symptoms due to mass effect of Arachnoid cyst.¹⁶ Few authors are of the view that all Arachnoid cysts are producing a mass effect even if they are not symptomatic or found incidentally and should be managed surgically to prevent potential risks of pressure effects on normal adjacent brain structures.¹⁷ The surgical treatment of Arachnoid cyst includes open craniotomy followed by marsupialization of the cyst, burr-hole aspiration of the cyst, cystoperitoneal shunting and more recently is the fenestration of Arachnoid cyst into the ventricles or adjacent cisterns by the use of a neuro endoscope.^{18,19,20} Among these different surgical techniques, endoscopic techniques is considered as a minimal invasive technique with better results and less postoperative complications and regarded as first surgical treatment option in Arachnoid cysts by many authors.^{21,22}

MATERIALS AND METHODS

Study Design

This descriptive type of study was conducted in July 2015 to September 2016 at the department of Neurosurgery Unit 1, PGMI, Lahore General Hospital, Lahore, with total duration of 15 months.

Inclusion Criteria

A total number of 13 patients were included in this study of both male and female gender and age range of 05-45 years as shown in Table 1.

Exclusion Criteria

Previously operated cases performs spend was utilized for data collection.

All the patients were admitted in the department of Neurosurgery followed by a detailed history, neurological examination and preoperative CT and MRI scans were performed in all patients.

Procedure of Data Collection

All the patients were prepared for surgery, seizure & antibiotic prophylaxis was given pre-operatively in each patient. Karl Storz (Lotta system) endoscope was used in all patients with double sterilization as shown in figure 1.

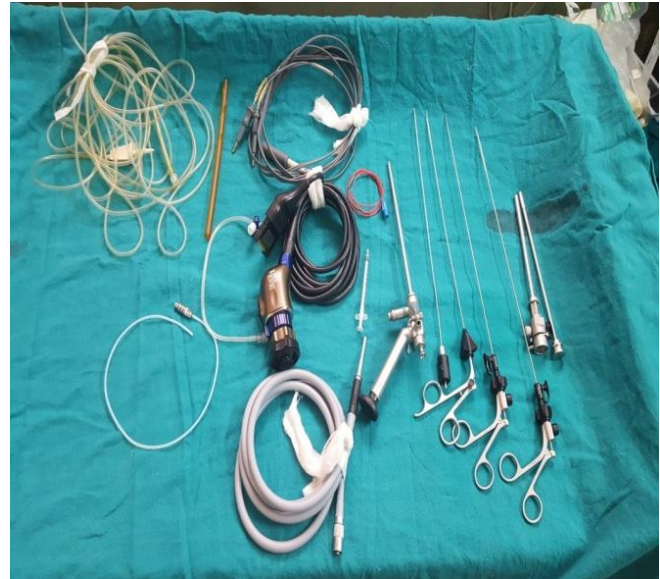

Fig. 1: Karl Storz (Lotta System).

Surgical Procedure Endoscope

A single burr-hole was made in each patient and fenestration was done following a thorough inspection of the cystic surface with the help of Ventriculostomy forceps, diathermy aided balloon, Fogarty catheter or micro-scissors. Hemostasis was secured with thorough irrigation, diathermy or balloon tamponade. Postoperative CT scan brain (plain) and follow up MRI brain scans after 2 months were done in all patients.

Data Analysis

Data was arranged in tables, number and percentage is are calculated.

RESULTS

Gender Distribution

Out of total 13 patients, there were 08 (60%) males and 05 (40%) female patients Table 1.

Table 1: Sex Distribution.

| Sex | Number | Percentage | Accumulative % |
|--------|--------|------------|----------------|
| Male | 8 | 60% | 60% |
| Female | 5 | 50% | 100% |
| Total | 13 | 100% | |

Age Range

Their age ranged from 05 - 45 years. The maximum numbers of patients were in their second and third decade of life.

Table 2: Locations of the Arachnoid Cysts.

| Site | Number | Percentage | Accumulative % |
|----------------|--------|------------|----------------|
| Suprasellar | 3 | 23% | 23% |
| Supratentorial | 6 | 46% | 69% |
| Intratentorial | 4 | 31% | 100% |
| Total | 13 | 100% | 100% |

Locations

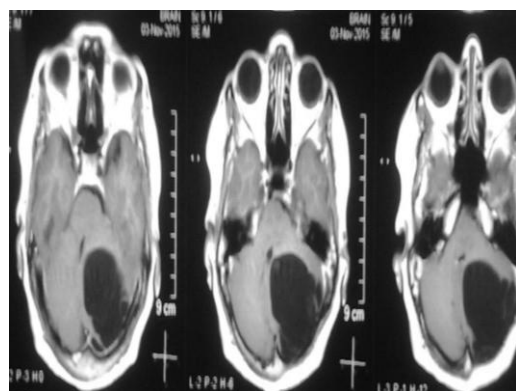
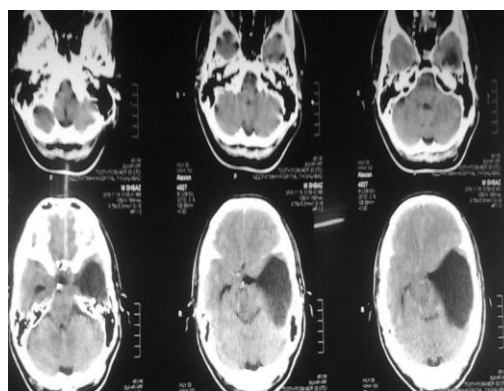
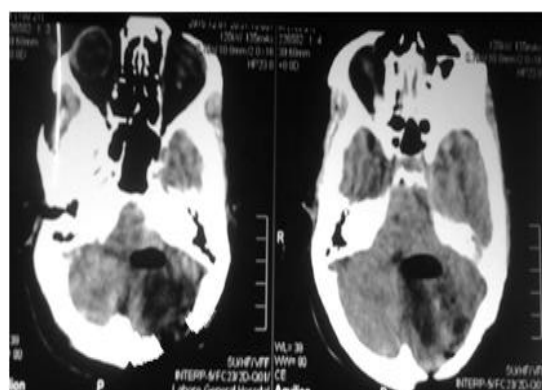
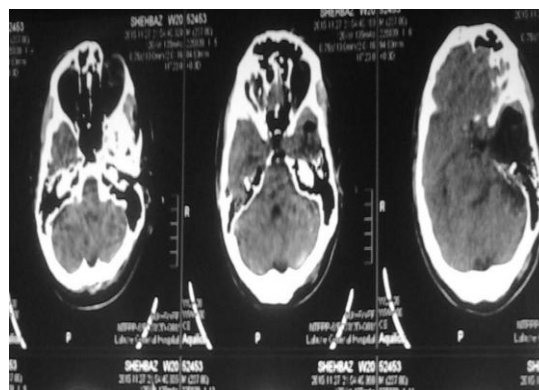
In our study, endoscopic fenestration was done in arachnoid cyst located in different parts of brain as shown in Table 2.

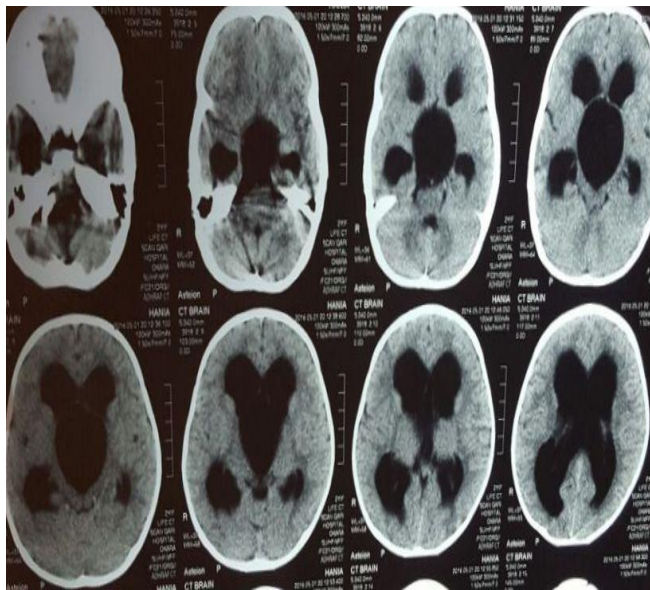
Outcome

In all patients, symptomatic relief and reduction in cyst size was gained in the majority of patients with minimal recurrence and fewer side effects as shown in figures 2 & 3.

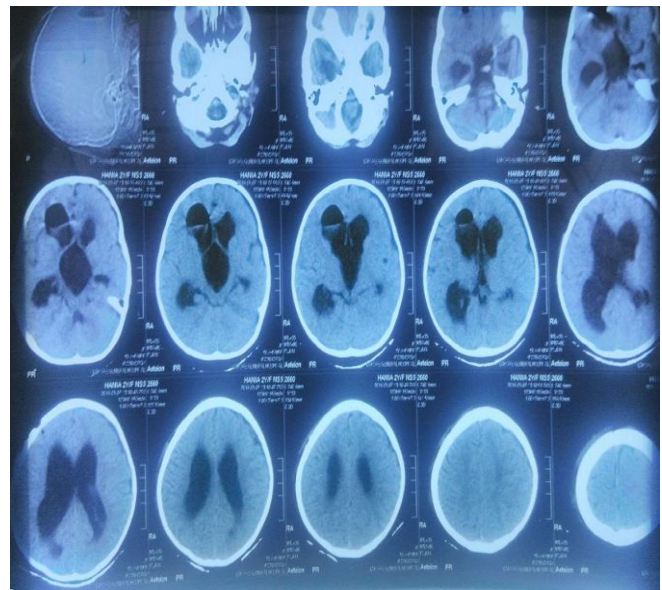
Table 3: Outcome.

| Outcome | Number | Percentage | Accumulative % |
|-----------|--------|------------|----------------|
| Excellent | 10 | 77% | 77% |
| Good | 2 | 15.3% | 92.3% |
| Fair | 1 | 7.6% | 100% |
| Total | 13 | 100% | 100% |

**A****C****B****D****Fig. 2: Pre (A+B) & Post-Op Scans (C+D).**



A: Pre-operative



B: Post-operative

Fig. 3: Pre (a) & Post-Op Scans (b).

In our study,¹³ patients, including 8 male and 5 female patients conducted in the Lahore General Hospital, Lahore within 15 months duration, all of them undergone endoscopic fenestrations of Arachnoid Cyst located in different locations of the brain like supra-tentorial compartment, infratentorial compartment and suprasellar cisterns. Adequacy of fenestration was judged by the size of fenestration (approx. 1-2cm) and to and fro motion of the fenestrated edges.

In our study, all patients had undergone immediate postoperative CT scan brain (plain) and follow up MRI brain scans after 2 months. Symptomatic relief and reduction in cyst size was gained in the majority of patients with a minimal recurrence and fewer side effects. Only one patient (7.6%) had a CSF leak postoperatively which was settled with suture re-enforcement.

DISCUSSION

Arachnoid cyst is a benign pathology in which an arachnoid-lined cavity is filled with a CSF fluid. It usually causes disturbance in an intracranial dynamics due to displacement of nearby structures and intracranial hypertension.²³ Previously Arachnoid cyst was treated by either cystoperitoneal shunt or by cyst fenestrations.²⁴ However, there is a continuous controversy regarding which procedure is best for

treating arachnoid cyst until endoscopic procedures has replaced open as well as shunting procedures with even same or better results with added advantages of minimal invasiveness, better visualization and less postoperative complications.²⁵

In 1999, *Kim, et al* conducted study on seven patients with arachnoid cyst located in different location of brain and proved that signs / symptoms as well as cyst size was reduced at 6, 12 and 18 months of follow up after endoscopic arachnoid cyst fenestration. There was no mortality or morbidity except one case of intra-cisternal bleeding intra operatively.²⁶ *Yadav, et al* in 2010 also conducted study on 12 patients with supra-sellar arachnoid cysts and proved that endoscopic fenestration of arachnoid cyst is a safe and effective treatment for supra-sellar arachnoid cysts.²⁷

CONCLUSION

Endoscopic treatment of intracranial Arachnoid Cysts has proved to be an effective and a very safe technique, providing best results, avoiding shunt dependency with minimal recurrence and fewer side effects.

ROLE OF AUTHORS

Amir Aziz: Surgeries.

Sarfraz Khattak: Literature review.

Zubair Ahmed Khan: Paper Editing and Results Writing.

Shahruh Rizvi, Toqeer Ahmed: Data Collection.

Muhammad Anwar: Surgeon and Supervision.

Additional Information

Disclosures and Conflict of Interests:

Authors report no conflict of interest.

Human Subjects: Consent was obtained by all patients/ participants in this study.

In compliance with the ICMJE uniform disclosure form, all authors declare the following:

Financial Relationships: All authors have declared that they have no financial relationships at present with any organizations that might have an interest in the submitted work.

Other Relationships: All authors have declared that there are no other relationships or activities that could appear to have influenced the submitted work.

Address for Correspondence:

Dr. Zubair Khan

Department of Neurosurgery Unit 1, Postgraduate Medical Institute, Lahore General Hospital, Lahore

Email: zoobby@yahoo.com

REFERENCES

1. Ciricillo SF, Cogen PH, Harsh GR, Edwards MSF. Intracranial arachnoid cyst in children: a comparison of the effects of fenestration and shunting. *J Neurosurg.* 1991; 74: 230-5.
2. Santamarta D, Aguas J, Ferrer E. The natural history of arachnoid cysts: endoscopic and cine view MRI evidence of slit-valve mechanism. *Minim Invas Neurosurg.* 1995; 38: 133-7.
3. Brackett CE, Rengachary SS. Arachnoid cysts. In: Youmans JR, ed. *Neurological surgery*, 2nd ed. Philadelphia: Saunders, 1982: 1436-1446.
4. Geissinger JD, Kohler WC, Robinson BW, Davis FM. Arachnoid cysts of the middle cranial fossa: surgical considerations. *Surg Neurol.* 1978; 10: 27-33.
5. Krawchenko J, Collins GH. Pathology of arachnoid cyst. Case report. *J Neurosurg.* 1979; 50: 224-8.
6. Harsh GR, Edwards MSB, Wilson CB. Intracranial Arachnoid Cysts in Children. *J Neurosurg.* 1986; 64: 835-842.
7. Rengachary SS, Watanabe I. Ultrastructure and Pathogenesis of Intracranial Arachnoid Cysts. *J Neuropathol Exp Neurol.* 1981; 40: 61-83.
8. Dei-Anang K, Voth D. Cerebral arachnoid cyst: A lesion of the child's brain. *J Neurosurg. Rev.* 1989; 12: 59-62.
9. Go KG, Houthoff HJ, Blaauw EH, Havinga P, Hartsuiker J. Arachnoid cysts of the sylvian fissure: Evidence of fluid secretion. *J Neurosurg.* 1984; 60: 803-813.
10. Oberbauer RW, Haase J, Pucher R. Arachnoid cysts in children: A European co-operative study. *Childs Nerv Syst.* 1992; 8: 281-286.
11. Kumagai M, Sakai N, Yamada H, Shinoda J, Nakashima T, Iwama T, Ando T. Postnatal development and enlargement of primary middle fossa arachnoid cyst recognized on repeat CT scans. *Child's Nerv Syst.* 1986; 2: 211-5.
12. Hoffman HJ, Hendrick EB, Humphreys RP, Armstrong EA. Investigation and management of suprasellar arachnoid cysts. *J Neurosurg.* 1982; 57: 597-602.
13. Santamarta D, Aguas J, Ferrer E. The natural history of arachnoid cysts: endoscopic and cine-mode MRI evidence of a slit- valve mechanism. *Minim Invas Neurosurg.* 1995; 38: 133-7.
14. Galassi E, Piazza G, Gaist G, Frank F. Arachnoid cysts of middle cranial fossa: a clinical and radiological study of 25 cases treated surgically. *Surg Neurol.* 1980; 14: 211-9.
15. Becker T, Wagner M, Hofmann E, Warmuth- Metz M, Nadjimi M. Do arachnoid cysts grow? : A retrospective CT volumetric study: *Neuroradiology*, 1991; 33: 341-5.
16. Beltramello A, Mazza C. Spontaneous disappearance of large middle cranial fossa arachnoid cyst. *Surg Neurol.* 1985; 24: 181-3.
17. Geissinger JD, Kohler WC, Robinson BW, Davis FM. Arachnoid cysts of middle cranial fossa: surgical considerations. *Surg Neurol.* 1978; 10: 27-33.
18. Auer LM, Holzer P, Ascher PW, Heppner F. Endoscopic neurosurgery. *Acta Neurochir (wien).* 1988; 90: 1-14.
19. Caemaert J, Abdullah J, Calliauw L, Carton D, Dhooge C, van Coster R. Endoscopic treatment of suprasellar arachnoid cysts. *Acta Neurochir (Wein).* 1992; 119: 68-73.
20. Kim MH. The role of endoscopic fenestration procedures for cerebral arachnoid cysts. *J Korean Med Sci.* 1999; 14: 443-447.
21. Schroeder HW, Gaab MR, Niendorf WR. Neuroendoscopic approach to arachnoid cysts. *J Neurosurg.* 1996; 85: 293-298.
22. Spacca B, Kandasamy J, Mallucci CL, Genitori L. Endoscopic treatment of middle fossa arachnoid cyst: a series of 40 patients treated endoscopically in two centres. *Childs Nerv Syst.* 2009; 24.
23. Santamarta D, Aguas J, Ferrer E. The natural history of arachnoid cysts: endoscopic and cine-mode MRI evidence of a slit-valve mechanism. *Minim Invasive Neurosurg.* 1995; 38: 133-137.

24. Caemaert J, Abdullah J, Callauw J. Endoscopic treatment of suprasellar arachnoid cysts. *Acta Neurochir.* 1992; 119: 68-73.
25. Auer LM, Holzer P, Ascher PW. Endoscopic neurosurgery. *Acta Neurochir.* 1988; 90: 1-14.
26. Kim MH. The role of endoscopic fenestration procedures for Cerebral Arachnoid Cysts. *J. Korean Med Sci.* 1999; 14: 443-7.
27. Yadav YR, Parihar V, Sinha M, Jain N. Endoscopic treatment of the suprasellar arachnoid cyst. *Neurol India*, 2010; 58: 280-3.

Date of Submission: 1-4-2019

Date of Revision: 23-04-2019

Date of Online Publishing: 01-06-2019

Date of Print: 15-6-2019