

Outcome of Anterior Cervical Fusion Technique for Multilevel Cervical Spondylotic Myelopathy

MUHAMMAD HASSAN RAZA, NABEEL CHAUDHARY, MUHAMMAD AKMAL
ADEEB-UL-HASSAN, KHALID MAHMOOD

Punjab Institute of Neurosciences (PINS), Lahore – Pakistan

DOI: <https://doi.org/10.36552/pjns.v23i4.373>

ABSTRACT

Objective: *The anterior approach for More than one level Cervical Spondylotic Myelopathy has been established for long times, having excellent Outcomes and post-operative results. But operative difficulties, invasiveness and other operative threats increase when more than one level are encountered.*

Materials and Methods: *Total ninety patients with Two, Three or Four-level Cervical Spondylotic Myelopathy were included who had anterior decompression and fusion. They were categorized into 3 special Groups, the Two-stage group (sixty-five sufferers), the three-level Group (20 sufferers) and the four-level group (five patients). Clinical and radiographic tests such as fusion frequency and Neck Disability Index (NDI) score, blood loss, stay in the hospital, surgical time, cervical lordosis, cervical movement range (ROM) and complications have been measured between different procedures.*

Results: *No statistical variations were observed among the 3 categories in the Neck Disability Index Ranking, stay in the Hospital, frequency of Fusion and lordosis of cervical spine at a minimum of 1-year follow-up. Nevertheless, the mean postoperative Neck Disability Index value of the Four-level category was expressively higher than that of the other two groups and the Three-level group was higher than the Four-level group and lower than the Two-level group in terms of maximum cervical range of motion after operative procedure. In the Three-level group, the frequency of decrease in ROM was ominously higher than in the Two-level group and lower than in the Four-level group.*

Conclusions: *As the number of active level increases, the working time, blood loss, the Neck Injury Scale, cervical ROM and postoperative complication rates got worsened. A Suitable Surgical Technique for multilevel cervical spondylotic myelopathy should be selected on the basis of a thorough medical assessment prior to surgery, thus minimizing rates of fusion and decompression where necessary.*

Keywords: *Cervical Spondylotic Myelopathy, Neck Injury Scale, Cervical Movement range*

INTRODUCTION

It is a common condition that occurs in old patients. ACDF is a reliable operative procedure for this disease¹. Nevertheless, multilevel disease is a medical issue that causes concern about proper management. The best multi-level disease's surgical solution remains controversial. Both anterior, posterior and combination of the anterior and posterior surgical approaches were described and promoted for multilevel cervical spondylotic myelopathy.²⁻⁹ Although subsequent procedures such as laminectomy

and laminoplasty are considered effective in the treatment of spondylotic myelopathy of multiple levels, progressive cervical Kyphosis. Anterior cervical corpectomy and fusion (ACDF) should repair cervical lordosis and actively decompress the spinal cord by separating from the ventral cord portion the offending soft or hard disks.¹⁰

MATERIALS & METHODS

Study Design

It is prospective case series. This research was conducted between January 2017 to October 2018,

Inclusion Criteria

Included 90 patients. Two, Three and Four Level Cervical spondylotic myelopathy surgery after taking written consent and approval from hospital ethical committee.

Exclusion Criteria

Recurrent cases were excluded for the study.

The criteria of removal were the patients, whose major signs were axial stress and radicular disorders, not symptoms of myelopathy.

Even omitted from the study were extreme stenosis cases. Patients, respiratory diseases or people with prior cervical spine operations and treatment for bones, cancers and infections were also removed.

Data Collection

The study group consisted of 37 females and 53 males, median-age 60.2 years. Most of the patients showed clinical signs of synaptic pressure and progressive refractory symptoms. The judgment on the quantity of surgical rates was based upon degree of compression on the spinal cord, Signals of MRI Modifications for spinal cord, segmental and cervical orientation.

Table 1: Number of patients and procedure done for Two, Three and Four level cervical Spondylotic Disease.

Procedure	2 Level	3 Level	4 Level
Anterior Cervical Corpectomy and Fusion	28	07	0
Anterior Cervical discectomy and Fusion	37	11	03
Discontinuous Corpectomy and fusion with reservation of the middle vertebra	0	0	02
Anterior Cervical Hybrid Decompression and Fusion	0	02	0
Total	65	20	05

Surgical Technique

Depending upon spinal cord compression procedure to be done is selected. Corpectomy decoded large osteophytes and clusters of disks. If there is anterior compression on the cord only discectomy is sufficient. ACHDF protocol requires One-level ACDF and One-level ACCF. The PPL was also cut to reveal the dura matter for complete decompression. Cartilaginous end plates have been separated from the neighboring vertebral bodies for the corpectomy. The bone has been placed into a titanium mesh of the appropriate size. The PEEK Interbody cage was placed at discectomy site. Finally, plate and screw were applied. Two-level ACDF and one-level ACCF has been conducted for 2-level infection. For three-level, three-level ACDF, ACHDF or two-level ACCF (**Figure 1**).

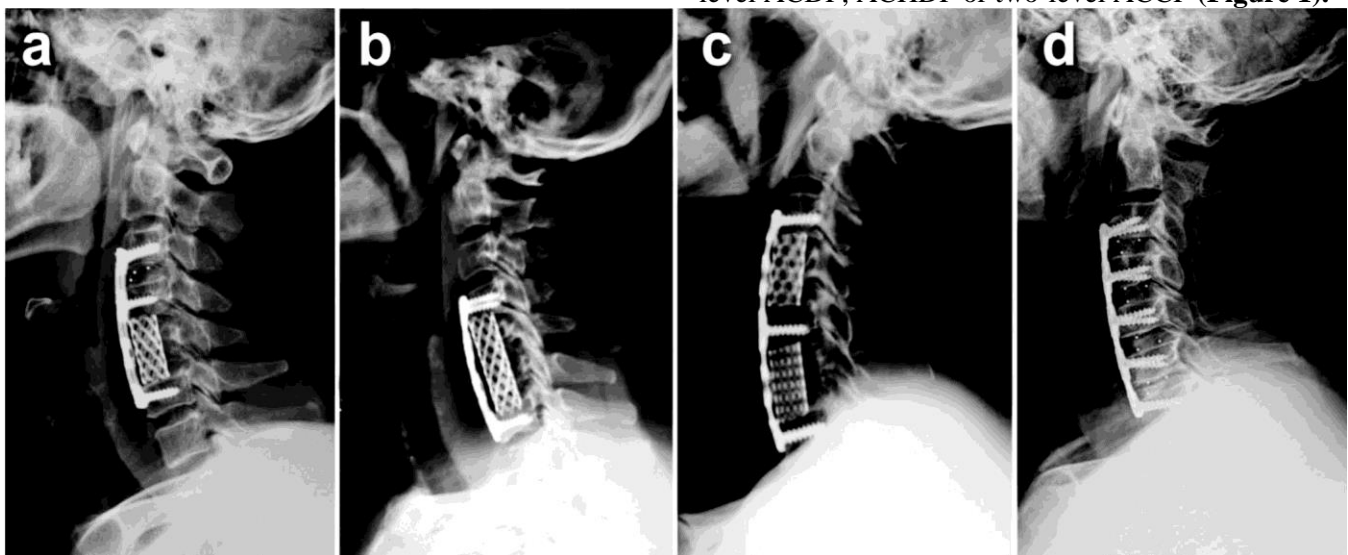


Fig. 1.a: ACHDF **b)** ACCF **c)** DCF **d)** ACDF.

Outcome Measures

NDI scores calculated to assess the Pain level. Pre-operative and post-operative follow-up of C2–C7 fusion segmental lordosis are determined using the Cobb test. Before and after the operation, lateral flexion and extension radiographs were checked. Using Cobb's test maximum motion range was defined as the angle between the lower end plate of the C2 and the upper end plate of the C7. ROM's decrease frequency was determined after the process. Bone fusion was determined between the spinous processes on flexion–extension lateral radiographs by absence of rotation of more than 2 degrees. During 3 M, 6 M, 12 M, postoperative follow-up assessments were performed on a regular basis. Follow-up for 12 M.

Statistical Analysis

Data was evaluated by the software version 19.0 for Microsoft Excel 2003 and SPSS. Upon treatment, the Wilcoxon rank-sum test examined improvements in medical signs and symptoms and cervical lordosis for each class. The Kruskal-Wallis H test and the chi-square test (for p values) were used for complexity correlations between the various groups.

RESULTS

Perioperative Parameters

The median follow-up period was between 09 and 12

months (on average 10.1). At diagnosis Symptoms ranged between 6 months and 4 years. (The main signs of diagnosis are arm numbness and paresthesia), shoulder, arm rigidity, muscle fatigue and gait dysfunction (**Table 2**).

Clinical and Radiological Outcomes

As far as the Neck disability index is concerned, there is was a normal range of motion and there is no difference between different groups preoperatively. Between the three categories of cervical lordosis there were no significant differences. Nonetheless Post-Operative Neck disability index score is higher for four level group as compared to other groups and the Three-level group was higher than the Four-level group and lower than the Two-level group in terms of the total post-operative ROM.

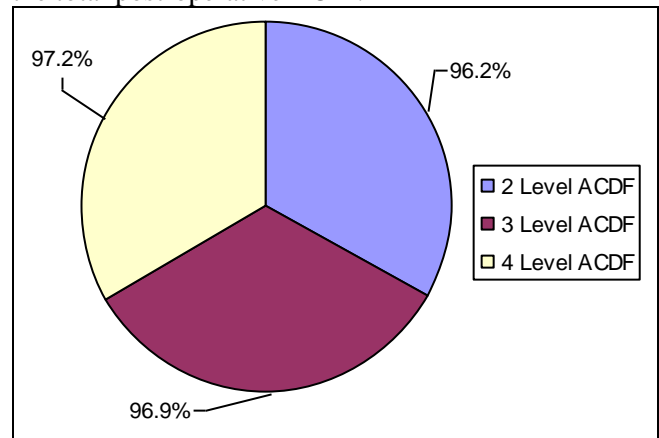


Fig. 2: Distribution of Rate of Fusion.

Table 2: Two, Three, Four Level ACDF and comparative status of different variable.

	Two-level Group (n = 65)	Three-level Group (n = 20)	Four-level Group (n = 05)	P
Age	59.24 ± 9.60	60.60 ± 9.84	61.50 ± 10.00	0.451
Gender (Male/Female)	35/30	12/08	03/02	0.883
Active smokers(yes/no)	20/45	06/04	02/03	0.676
Patient with diabetes	13	04	01	0.354
Hypertensive Patients	12	04	02	0.821
Stay in Hospital (day)	11.71 ± 2.67	11.59 ± 3.00	12.41 ± 2.56	0.074
Operative time (min)	106.51 ± 17.90	129.64 ± 16.87	166.14 ± 20.65	0.000
Loss of Blood (mL)	126.42 ± 28.86	154.00 ± 30.32	194.77 ± 42.34	0.000

The removal rate of ROM was substantially higher in the three-level than in the two-level and lower than in the four-level. The rate of fusion is 96.2% in the Two-level, 96.9% in the Three -level and 97.2% in the

Four-level. On radiology level of fusion in the Two-level group was 89.6%, 91.2% in the Three-level group and 87.8% after 3 months in the Four-level group.

Complications

4 Patients (20.0%) had complications after operation in the 3-level group involving dysphagia (2 case), dysphonia (0 case), C5 palsy (0 case), cerebral fluid leakage (0 cases), pseudarthrosis (1 case), graft displacement (1 case) and subsidence (0 case).

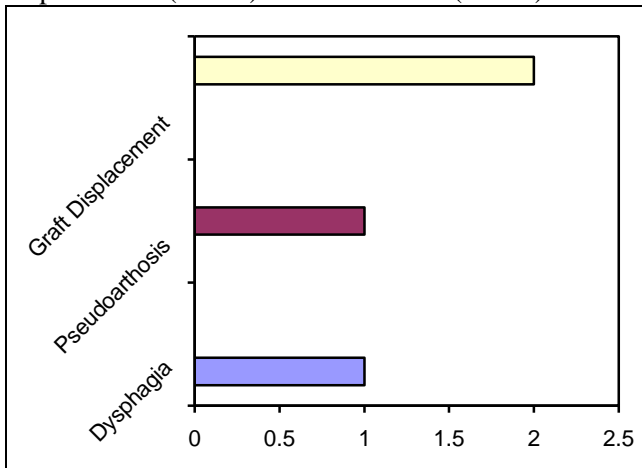


Fig. 3: Complications in 3 Level Group.

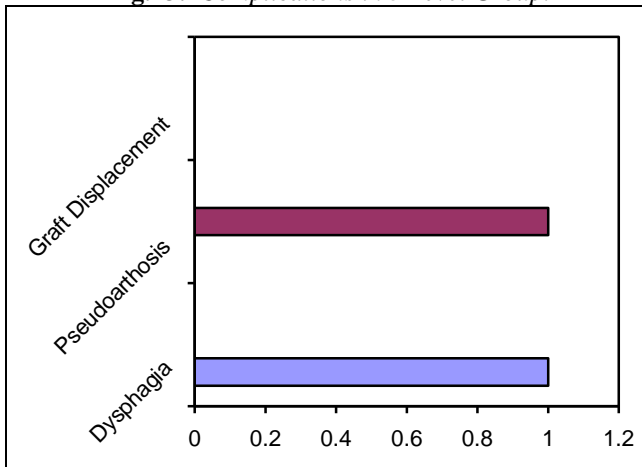


Fig. 4: Complications in 4 Level Group.

A total of 2 (40.0%) patients in the 4-level having postoperative complications involving dysphagia (1 case), dysphonia (0 case), C5 palsy (0 case), cerebral fluid leakage (0 cases), pseudarthrosis (1 case) and subsidence (0 case).

In the Three-level group, statistical analysis found a higher incidence of postoperative complications than in the Two-level group and the lowest post-operative complications in the Four-level group.

DISCUSSION

A significant difference in the NDI score and average cervical ROM were observed in all three categories based on our retrospective study of 90 patients. The NDI score was substantially higher in the 4-level

category than in the remaining 2 classes assessed. But, as the number of fused rates increases, most patients still suffered at follow-up hours with varying neck ache and rigidity. It might be due to excessive interference. Disc degeneration in multi-level disease patients is more severe. Because of subsidence, intervertebral disk space is very small.⁶ As the number of fused vertebra increases, the frequency of practical problems also increased. Kang et al. indicated that the risk of dysphagia was higher in the population, which experienced a multi-levels compared to one level treatment. It was observed that incidence of dysphagia increases with increase in number of involved vertebrae.

In the 3 level and 4 level categories, they have found a higher incidence of accidents than in the 2-level groups.⁵ As the number of fused levels rises, it is not easy to prevent these issues. Bone and/or plate related problems were reported at high rates following multilevel surgery, even when internal fixation was used during surgery. It was observed that that discectomy and fusion at multilevel provide more fixation points to keep the build rigid.⁵

Cord compression is a very important factor for the decision of operative technique. Corpectomy has a higher failure rate in term of Subsidence.¹¹⁻²⁰ The treatment choice will be decided on the basis of the extent of the strain, clinical needs and medical condition. Every patient received complete radiography of the cervical spine, CT and MRI.²¹⁻²²

Kou et al, reported that the risk of epidural hematoma associated with multilevel therapy was large following surgery.² In a complex anterior approach to cervical surgery, Grabowski et al reported a higher risk of damage to the esophageal or vertebral arteries. It was also noted that lengthy procedures showing more than three vertebral levels, such as C2, C3, and C4 were closely performed for respiratory insufficiency.⁴

In this study, there were also some shortcomings. First of all, it was a historical examination. The number of clients in the 4 level band was relatively small. Second, different methods in the same system may influence the fusion stage and the related instrumentation and graft complications. In the end, the occurrence of adjacent segment disease cannot be monitored as the follow-up period was 1 year. Therefore, it may be appropriate to have others trial as well.

CONCLUSION

Based on our findings, we conclude that operating time, loss of blood, NDI score after operative procedure, Cervical Range of motion after operation, and complications are getting worse as the amount of fused surgical levels increases. A suitable operative technique for multilevel pathology should be selected on the basis of full preoperative medical evaluation, thus raising the need for fusion and decompression

REFERENCES

1. Reitman CA, Hipp JA, Nguyen L, Esses SI. Changes in segmental intervertebral motion adjacent to cervical arthrodesis: a prospective study. *Spine*, 2004; 29 (11): E221–E226.
2. Konya D, Ozgen S, Gercek A, Pamir MN. Outcomes for combined anterior and posterior surgical approaches for patients with multisegmental cervical spondylotic myelopathy. *J Clin Neurosci*. 2009; 16: 404–409.
3. Jiang JL, Li XL, Zhou XG, Lin H, Dong J. Plate-only open-door laminoplasty with fusion for treatment of multilevel degenerative cervical disease. *J Clin Neurosci*. 2012; 19 (6): 804–809.
4. Manzano GR, Casella G, Wang MY, Vanni S, Levi AD. A prospective, randomized trial comparing expansile cervical laminoplasty and cervical laminectomy and fusion for multilevel cervical myelopathy. *Neurosurgery*, 2012; 70 (2): 264–277.
5. Lin Q, Zhou X, Wang X, Cao P, Tsai N, et al. A comparison of anterior cervical discectomy and corpectomy in patients with multilevel cervical spondylotic myelopathy. *Eur Spine J*. 2012; 21 (3): 474–481.
6. Herkowitz HN. A comparison of anterior cervical fusion, cervical laminectomy, and cervical laminoplasty for the surgical management of multiple level spondylotic radiculopathy. *Spine*, 1988; 13 (7): 774–780.
7. Yonenobu K, Hosono N, Iwasaki M, Asano M, Ono K. Laminoplasty versus subtotal corpectomy. A comparative study of results in multisegmental cervical spondylotic myelopathy. *Spine*, 1992; 17 (11): 1281–1284.
8. Sakaura H, Hosono N, Mukai Y, Ishii T, Yoshikawa H. C5 palsy after decompression surgery for cervical myelopathy: review of the literature. *Spine*, 2003; 28 (21): 2447–2451.
9. Lebl DR, Hughes A, Cammisa FP Jr, O’Leary PF. Cervical spondylotic myelopathy: pathophysiology, clinical presentation, and treatment. *HSS J*. 2011; 7 (2): 170–178.
10. Liu T, Xu W, Cheng T, Yang HL. Anterior versus posterior surgery for multilevel cervical myelopathy, which one is better? A systematic review. *Eur Spine J*. 2011; 20 (2): 224–235.
11. Sevki K, Mehmet T, Ufuk T, Azmi H, Mercan S, et al. Results of surgical treatment for degenerative cervical myelopathy: anterior cervical corpectomy and stabilization. *Spine*, 2004; 29 (22): 2493–2500.
12. Liu Y, Yu KY, Hu JH. Hybrid decompression technique and two-level corpectomy are effective treatments for three-level cervical spondylotic myelopathy. *J Zhejiang Univ Sci B*. 2009; 10 (9): 696–701.
13. Chang SW, Kakarla UK, Maughan PH, DeSanto J, Fox D, et al () Fourlevel anterior cervical discectomy and fusion with plate fixation: radiographic and clinical results. *Neurosurgery*, 2010; 66 (4): 639–646.
14. Liu Y, Hou Y, Yang L. Comparison of 3 reconstructive techniques in the surgical management of multilevel cervical spondylotic myelopathy. *Spine*, 2012; 37 (23): e1450–e1458.
15. Shunzhi Y, Zhonghai L, Fengning L, Zhi C, Tiesheng H. Surgical Management of 4-level Cervical Spondylotic Myelopathy. *Orthopedics*, 2013; 36 (5): e613–e620.
16. Park Y, Maeda T, Cho W, Riew KD. Comparison of anterior cervical fusion after two-level discectomy or single-level corpectomy: sagittal alignment, cervical lordosis, graft collapse, and adjacent-level ossification. *Spine J*. 2010; 10 (3): 193–199.
17. Oh MC, Zhang HY, Park JY, Kim KS. Two-level anterior cervical discectomy versus one-level corpectomy in cervical spondylotic myelopathy. *Spine*, 2009; 34 (7): 692–696.
18. Guo Q, Bi X, Ni B, Lu X, Chen J, et al. Outcomes of three anterior decompression and fusion techniques in the treatment of three-level cervical spondylosis. *Eur Spine J*. 2011; 20 (9): 1539–1544.
19. Stewart TJ, Schlenk RP, Benzel EC. Multiple level discectomy and fusion. *Neurosurgery*, 2007; 60 (1):S143–S148.
20. Majd ME, Vadhva M, Holt RT. Anterior cervical reconstruction using titanium cages with anterior plating. *Spine*, 1999; 24 (15): 1604–1610.
21. Penning L. Normal movements of the cervical spine. *Am J Roentogenol*. 1978; 130 (2): 317–326.
22. Hacker RJ, Cauthen JC, Gilbert TJ, Griffith SL. A prospective randomized multicenter clinical evaluation of an anterior cervical fusion cage. *Spine*, 2000; 25 (20): 2646–2654.

Additional Information

Disclosures: Authors report no conflict of interest.

Ethical Review Board Approval: The study was conformed to the ethical review board requirements.

Outcome of Anterior Cervical Fusion Technique for Multilevel Cervical Spondylotic Myelopathy

Human Subjects: Consent was obtained by all patients/participants in this study.


Conflicts of Interest:

In compliance with the ICMJE uniform disclosure form, all authors declare the following:

Financial Relationships: All authors have declared that they have no financial relationships at present or within the previous three years with any organizations that might have an interest in the submitted work.

Other Relationships: All authors have declared that there are no other relationships or activities that could appear to have influenced the submitted work.

*Correspondence: Dr. Muhammad Hassan Raza, Punjab Institute of Neurosciences, Lahore
Email: Mhraza512@hotmail.com*

AUTHORSHIP AND CONTRIBUTION DECLARATION			
Sr.#	Author's Full Name	Intellectual/Contribution to Paper in Terms of:	
1.	Muhammad Hassan Raza (Main/Principal Author).	1. Proposed Topics and Basic Study Design, Methodology.	Signature by the author(s) 
2.	Nabeel Chaudhary (2nd Author)	2. Data Collection and Calculations.	
3.	Muhammad Akmal (3rd Author)	3. Analysis of Data and Interpretation of Results etc.	
4.	Adeeb-ul-Hassan (4th Author)	4. Literature Review and Manuscript Writing.	
5.	Khalid Mahmood (5th Author)	5. Paper Writing, Referencing, Data Calculations and Quality Insurer.	

Date of Submission: 20-10-2019

Date of Revision: 04-12-2019

Date of Online Publishing: 25-12-2019

Date of Print: 31-12-2019