

Endoscopic Endonasal Excision of Pituitary Tumors Using a Mono-nostril Technique

AMIR AZIZ, YASER-UD-DIN, ZUBAIR AHMED, SHARUKH RIZVI
HABIB SULTAN, ANWAR CHAUDHRY, RIZWAN MASOOD

Department of Neurosurgery Unit 1, Lahore General Hospital Lahore – Pakistan

DOI: <https://doi.org/10.36552/pjns.v23i4.382>

ABSTRACT

Objectives: The purpose of this study is to assess the effectiveness and advantage of endoscopic mono-nostril approach to the pituitary tumors.

Materials and Methods: We analyzed 70 patients undergoing transsphenoidal mono-nostril excision of pituitary tumors from September, 2016 to March, 2018.

Results: We operated 70 patients, out of which 51 were males and 19 were females; the age of the patients ranged from 15 years to 65 years. In our study, out of 70 patients, 61 (87.1%) patients had excellent results with total tumor resection, marked visual improvement, early discharge on the second post-operative day, resuming their daily activities within two weeks and recurrence free interval of 1 year. Nine (12.8%) of our patients had a partial excision of the tumor, whereby there was improvement of headaches in all of them while visual status remained at the pre-operative status. Five (7.1%) of our patients had a post-operative cerebral spinal fluid (CSF) rhinorrhea, 4 (5.7%) in total excision group and 1 (1.4%) in partial excision group. These patients of CSF leak were retained in hospital and their mean stay in hospital was 12 ± 4 . Two cases were re-explored and the nasal reconstruction was done via inlay outlay graft using the other nostril, post operatively the CSF leak stopped. Only 1 patient had a trans-cranial repair of dura for CSF leak. One (1.4%) of our patient expired post operatively.

Conclusion: We consider that endoscopic mono-nostril excision of the pituitary tumor is a relatively safer, effective, minimally invasive procedure; whereby there is a fast recovery, early discharge and good cosmetic results.

Keywords: Endoscopic, mono-nostril, trans-sphenoid, pituitary, CSF rhinorrhea.

INTRODUCTION

The pituitary gland has fascinated clinicians for many decades, it was believed to be an organ draining the waste products from the brain through nostrils. In 1930, when the vasopressin and oxytocin was discovered to be secreted by pituitary, it was then considered as a gland and the pituitary gland become “the conductor of the endocrine orchestra”¹ Harvey Cushing was the first person pioneering the transsphenoidal approach to the pituitary gland. Sir Victor Horsley, performed a series of transsphenoidal approach in 10 patients from 1904 to 1906, but couldn’t get the desired results. The first successful approach was made in 1907 by Schloffer.

In 1978, Bushe and Halves introduced the use of the endoscope in pituitary operation¹. However, it was not until the mid-1990s that the endoscope gained popularity for pituitary operation after otolaryngologists started using it for a sinus operation with improved visualization and good working space. Yaniv and Rappaport described a combined approach in which the endoscope was used for the initial approach to the sphenoid sinus, followed by conversion to the standard transsphenoidal microsurgical approach for the tumor resection.² Jho and Carrau later reported the largest series of patients who had undergone pure endoscopic endonasal transsphenoidal operation.³

Since the introduction of the endoscopic transsphenoidal surgery, most surgeons advocate either of two techniques; two surgeons (3 or 4 hands) technique, or one surgeon (2 hands) technique utilizing an endoscope holder.^{4,9,17} In the binostril 3-hand technique, the ENT surgeon does the exposure, then holds the endoscope in one nostril (usually the right) and the neurosurgeon works with instruments using both nostrils. Usually the neurosurgeon holds the suction in the non-dominant hand and a dissecting instrument in the dominant one. With the mononostril 2-hand technique, the ENT surgeon may perform the nasal phase of the surgery, but then the endoscope holder (hydraulic or mechanical) may be used for the rest of the operation.^{5,8} Furthermore, as discussed by Edward Laws and John Jane, the main advantage of the mono-nostril technique is lesser trauma to the nasal mucosa and thus less nasal morbidity such as crusting, loss of smell, and synechia.⁶ However, the main disadvantage is small working room, especially for invasive and large macro-adenomas. In this situation, the degree of freedom that is gained by the operating surgeon is crucial for better surgical outcomes. This freedom is gained by the elimination of the endoscope shaft, usually used for irrigation and holding, from one of the surgeons operating corridors. Based on this, we wanted to assess our results looking for the efficacy of the mono-nostril technique and compare it to the literature with respect to outcome and efficacy.

In this paper, we present our series of 70 patients of sellar pituitary adenomas operated via the endoscopic endonasal transsphenoidal approach using a single nostril, 2-hand and 4 handed technique. We studied the outcomes, besides the complications of our operations.

MATERIALS AND METHODS

Study Design

Descriptive prospective study. Seventy patients, age ranging from 15 to 65 years, from September, 2016 to April, 2018 with pituitary tumor underwent transsphenoidal mono-nostril approach in our department.

Inclusion Criteria

All cases of pituitary tumor which were sella and suprasellar.

Exclusion Criteria

Recurrent tumor and parasellar extension and children below 14 years of age. Cases of Radiosurgery were excluded similarly these patients who refused consent.

Data Collection

In all the patients, pre-operative evaluations, including MRI of the brain and sellae, CT scan of sellae, paranasal sinuses and sphenoid sinuses were performed. We classified the pituitary adenomas according to the classification of Hardy (Grade 0 to Grade V) were assessed by radiological and intra-operative findings. Post-operative CT Scans were done after 72 hours, while MRIs were obtained after 3 months of surgery.

Table 1: *Hardy Classification.*

Grade	Size	Extension	No. of Patients
0	< 10 mm	Sella normal	20
I	< 10 mm	Sella expanded	25
II	> 10 mm	Sella expanded	16
III	> 10 mm	Focal destruction	5
IV	> 10 mm	Diffuse destruction	4
V		Distant spread	0

Operative Technique

We used the mono-nostril approach in all operations. The choice of the nostril was done with the help of a preoperative 1-mm cut CT scan of the sinuses. If there was no septal deviation we tended to use the right nostril, as both surgeons were right handed, and it was easier to handle the scope with the left hand and work with the right hand. Should there be a septal deviation, a sub-mucosal resection of the septum (SMR) or operating through the other nostril may be preferred. In the nasal stage, the middle turbinate is lateralized, and as we reach and identify the sphenoid ostium on one side, we continue in a sub-mucosal fashion across the perpendicular plate of the ethmoid to expose the contra-lateral ostium as shown in figure 1.

Removing the bone between the two ostia and connecting them in one big hole creates a wider working space demonstrated in figure 2. The mucosa over the entered ostium is either coagulated or used to make a flap for better closure, whereas the mucosa on the other side is kept intact for better healing of the

nose. In the sphenoidal stage as we enter the scope into the sphenoid sinus, the scope is handed over to the assistant making it a four handed technique, who will push it into the upper corner of the nostril. Under some circumstances, we can also use 2-handed technique

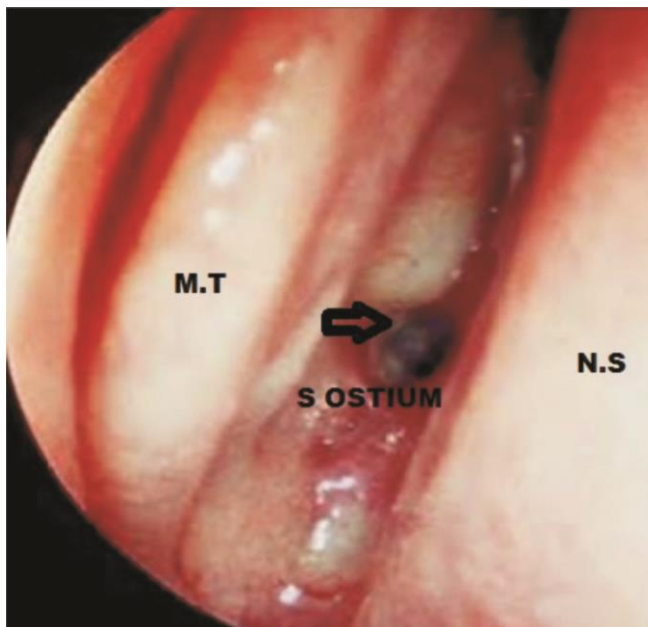


Fig. 1: Endoscopic view of the nasal anatomy, showing the medial turbinate (M.T) on the left, nasal septum (N.S) on the right and sphenoid ostium (S.O) in the middle.

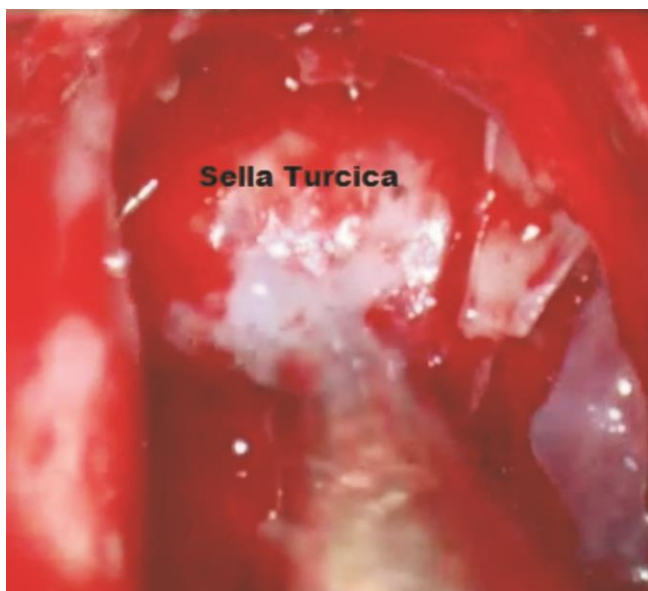


Fig. 2: After entering the ostium and removing the vomer bone, sphenoid sinus is entered drilling the floor of sinus and exposing the sella turcica.

with suction in the left hand and the other working instrument in the right one. After incising the dura in cruciate manner, the tumor bulges by itself and adenoma is removed using ring curettes in the corners with visualization of an endoscope. After tumor removal, and identifying the arachnoid pulsation the reconstructive phase is started by applying surgical and fixing up with fibrin glue. A fat graft, taken from a small abdominal incision, in some cases was tucked in and fixed with glue.

Data Analysis

It was done SPSS Version 20.

RESULTS

Gender Distribution

We operated 70 patients, out of which 51 were males and 19 were females.

Age Incidence

The age of the patients ranged from 15 years to 65 years.

Clinical Outcome with Reference to Excession of Tumor

Group A: Total Excision

The surgical removal of tumor (Fig. 3 and Table 2 & 3). A total resection in our study, out of 70 patients, 61 (87.1%) patients had excellent results with total tumor resection, marked visual improvement, early discharge on the second post-operative day, resuming their daily

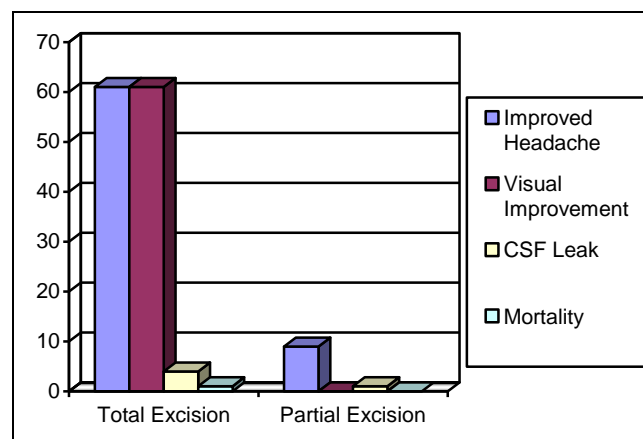


Fig. 3: Graphical presentation of results for trans-sphenoidal mononostril excision of pituitary tumors.

Table 2: *Clinical Outcome with Reference to Excision of Tumor.*

Group A	Headache Improved		Vision Improved	
	Yes	No	Yes	No
Excision 61 (87.1%) Cases	61 (100%)	Nil	61 (100%)	Nil
Group B				
Partial Excision 9 (12.8%) Cases	All 9 Cases (100%)	Nil	Nil	All Static 9 Cases (100%)

Table 3: *Visual Improvement.*

Extent of Excision	Vision Improvements		Static Vision	
	No.	%	No.	%
Total Excision 61 cases	61	100%		
Partial excision 9 cases			9	100%

activities within two weeks and recurrence free interval of 1 year.

Partial Excision

Nine (12.8%) of our patients had a partial excision of the tumor. There was improvement of headaches in all of them while visual status remained at the pre-operative status. There was no case of visual deterioration.

Complications

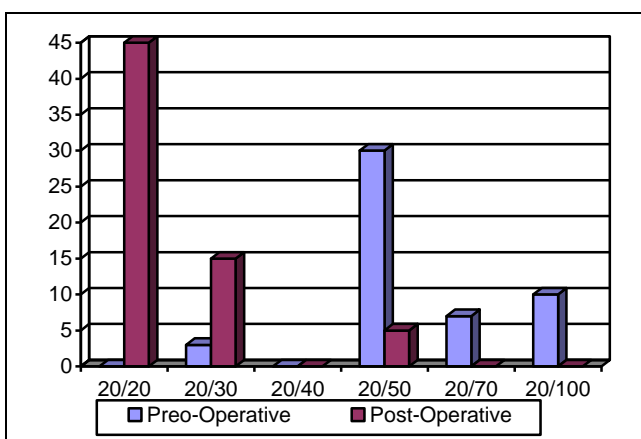
Table shows the complications. Five (7.1%) of our patients had a post-operative cerebral spinal fluid (CSF) rhinorrhea, 4 (5.7%) in total excision group and

1 (1.4%) in partial excision group. These patients of CSF leak were retained in hospital and their mean stay at hospital was 12 ± 4 . Two cases were re-explored and the nasal reconstruction was done via inlay outlay graft using the other nostril, post operatively the CSF leak stopped. Only 1 patient had a trans-cranial repair of dura for CSF leak. One (1.4%) of our patient expired post operatively.

DISCUSSION

Our results are comparable to most endoscopic and microscopic series reported in the literature. We have achieved a gross total resection of 87% for non-invasive macro-adenomas overall, with a stable residual in 13%. Among those, the non-secreting adenomas had a 78% gross total resection rate, with 22% having a small stable residual at their last follow-up (near total removal). The invasive non-secreting adenomas on the other hand had an initial 87% near total resection. Long-term surgical stability at last follow up was thus achieved in patients with invasive nonfunctioning adenomas. Of note is that most of the residuals or recurrences requiring another operation or radiation therapy occurred in the invasive adenoma group.

As for patients with preoperative visual field disturbances, complete recovery of vision was seen in 40%–50% of the cases and improvement in 39%–51% of the cases in two large endoscopic series.^{7,12,13,15} In our series, we had 60% complete recovery of vision and improvement was seen in another 30% of patients.

**Fig. 4:** *Pre-Operative and Post-Operative Assessment of Visual Status.*

One patient who had presented with a third nerve palsy had near total recovery after operation. One common complication is transient diabetes insipidus. Permanent diabetes insipidus is much less common and is seen in around 1% of the cases.^{8,15} Postoperative CSF leak rate ranges around 2%–4%, and in the 200 patients reported by Dehdashti et al, it was 3.5%.^{7,8,16} Only 2% of our patients had persistent diabetes insipidus and one had a postoperative CSF leak.

Hospital stay is relatively short in most endoscopic series, and in one retrospective study, Neal et al. showed a significant decrease in hospital stay (3.4 days) and operation time (4.41 hours) using the endoscopic approach.⁹ In our series, the hospital stay ranged from 2 to 5 days with an average of 2.8 days. The operative time ranged around 2.2–4 hours with an average of 2.8 hours.

The endoscopic trans-nasal approach offers excellent results when it comes to removal of pituitary tumors, with less nasal complication rates when compared to the microscopic sub-labial trans-sphenoidal approach.^{10,16} However, there is controversy as to whether the bi-nostril or mono-nostril endoscopic approach is superior. Some neurosurgeons prefer the mono-nostril approach, whereas the otolaryngologists prefer the bi-nostril approach.^{4,11} Far from being a rule, however, this has created controversy over the preferred endoscopic approach for pituitary lesions.

As for the bi-nostril approach, the ostia are separately and bilaterally identified and the mucosa can then be coagulated or turned as a flap. The scope is held, usually by the ENT (Ear, Nose, & Throat) surgeon or by scope holder, in one nostril usually the right and the neurosurgeon works through both nostrils with his two hands. The major advantage in this approach is the dynamic process achieved with both surgeons working together at the same time. The space afforded for surgical instruments is also wider, with easier manoeuvring. The major disadvantage is mucosa disruption on both sides of the sphenoid ostium, which may lead to more nasal crusting and discomfort.

We have described earlier our usual single nostril approach, where after lateralization of the middle turbinate, localization of one sphenoid ostium, and exposure of the ethmoid plate, the contra-lateral ostium is performed. The central bone removal affords an acceptable wide working space. It is generally felt that the preservation of the contra-lateral mucosa is important for proper healing of the nose. As pituitary tumors are usually soft and easily removed with

pituitary curettes and suction, the authors believe that the space provided by the single nostril approach is enough, though sometimes a bit crowded, to perform the procedure with high success rate. The authors, further, remove the endoscope holder towards the end of tumor resection, and inspect the surgical field in a dynamic fashion through the same nostril allowing further removal of possible missed tumor. The approach is minimally invasive and the nose heals quickly, especially with an intact mucosa on the contra-lateral sphenoid ostium and proper medialization of the middle turbinate at the end of the procedure. Our results, further, have been comparable to most endoscopic series, with a very low complication rate.

LIMITATION OF STUDY

Limitations to the mono-nostril approach may be a crowded narrow nasal cavity, a harder tumor with invasive appearance or significant supra-sellar extension, and lesions other than pituitary adenomas. The mono-nostril surgery may then be simply turned into a bi-nostril, wider and more dynamic approach to allow for better dissection of such larger, harder, and more extensive tumors.

CONCLUSION

In conclusion, we have reviewed our experience with the mono-nostril endoscopic approach for pituitary tumors in 70 patients. We have shown comparable results to the bi-nostril technique, mostly reported in endoscopic series, in pituitary adenomas, as the endoscope allows inspection of the hidden corners and supra-sellar region, allowing for a more nearly complete resection. The recurrence and complication rates were quite low, mostly limited to recurrent or invasive adenomas. We feel that the mono-nostril approach is simple, less traumatic, and sufficient for pituitary adenoma surgery to achieve a good outcome.

REFERENCES

1. Bushe K. A., Halves E. Modified Technique of transnasal operation for Hypophyseal- pituitary axis. *J. Acta Neurochirurgica*. 1978; 41 (1–3): 163–175.
2. Yaniv E., Rappaport Z. H. Endoscopic Transseptal Transsphenoidal Surgery for Pituitary Tumors. *Neurosurgery*, 1997; 40 (5): 944–946.
3. Jho H. D., Carrau R. L. Endoscopic endonasal trans-sphenoidal surgery: experience with 50 patients.

- Neurosurgical Focus, 1996; 87 (1): 44–51.
4. Cappabianca P., Cavallo L. M., de Divitiis E. Endoscopic Endonasal Transsphenoidal Surgery. *Neurosurgery*, 2004; 55 (4): 933–941.
5. Cappabianca P., Cavallo L. M., Colao A., Del Basso De Caro M., Esposito F., Cirillo S., et al. Endoscopic Endonasal Transsphenoidal Approach: Outcome Analysis of 100 Consecutive Procedures. *Minimally Invasive Neurosurgery*, 2002; 45 (4): 193–200.
6. Jgannathan J., Laws E. R., Jane J. J. Advantages of endoscope and transitioning from microscope to the endoscope for endonasal approaches. Ed Kassam B., *Endoscopic Approaches to Skull Base*, Switzerland: Karger, 2011: 7–21.
7. Dehdashti A. R., Ganna A., Karabatsou K., Gentili F. Pure endoscopic endonasal approach for pituitary adenomas: early surgical results in 200 patients and comparison with previous microsurgical series. *Neurosurgery*, 2008; 62 (5): 1006–1017.
8. Tabaei A., Anand V. K., Barrón Y., Hiltzik D. H., Brown S. M., Kacker A., et al. Endoscopic pituitary surgery: a systematic review and meta-analysis. *Journal of Neurosurgery*, 2009; 111 (3): 545–554.
9. Neal J. G., Patel S. J., Kulbersh J. S., Osguthorpe J. D., Schlosser R. J. Comparison of techniques for transsphenoidal pituitary surgery. *American Journal of Rhinology*, 2007; 21 (2): 203–206.
10. Koren I., Hadar T., Rappaport Z. H., Yaniv E. Endoscopic transnasal trans-sphenoidal microsurgery versus the sublabial approach for the treatment of pituitary tumors: Endonasal Complications. *The Laryngoscope*, 1999; 109 (11): 1838–1840.
11. Nakagawa T., Takashima T., Tomiyama K., Asada M. Approaches to Sella Turcica in Endoscopic Pituitary Surgery. *Nippon Jibiinkoka Gakkai Kaiho*, 2001; 104 (1): 1–8.
12. Mortini P., Losa M., Barzaghi R., Boari N., Giovanelli M. Results of Transsphenoidal Surgery in a Large Series of Patients with Pituitary Adenoma. *Neurosurgery*, 2005; 56 (6): 1222–1233.
13. De Divitiis E., Cappabianca P., Cavallo L. M. Endoscopic Trans-sphenoidal Approach: Adaptability of the Procedure to Different Sellar Lesions. *Neurosurgery*, 2002; 51 (3): 699–707.
14. Biller B. M. K., Grossman A. B., Stewart P. M., Melmed S., Bertagna X., Bertherat J., et al. Treatment of adrenocorticotropin dependent cushing's syndrome: A Consensus Statement. *The Journal of Clinical Endocrinology & Metabolism*, 2008; 93 (7): 2454–2462: 10.
15. Giustina A., Chanson P., Bronstein M. D., Klibanski A., Lamberts S., Casanueva F. F., et al. A Consensus on Criteria for Cure of Acromegaly. *The Journal of Clinical Endocrinology & Metabolism*, 2010; 95 (7): 3141–3148.
16. Hofstetter C. P., Shin B. J., Mubita L., Huang C., Anand V. K., Boockvar J. A., Schwartz T. H. Endoscopic endonasal transsphenoidal surgery for functional pituitary adenomas. *Neurosurgical Focus*, 2011; 30 (4).
17. Mamelak A. N., Carmichael J., Bonert V. H., Cooper O., Melmed S. Single-surgeon fully endoscopic endonasal trans-sphenoidal surgery: outcomes in three-hundred consecutive cases. *Pituitary*, 2012; 16 (3): 393–401.
18. Yano S., Kawano T., Kudo M., Makino K., Nakamura H., Kai Y. Endoscopic Endonasal Transsphenoidal Approach Through the Bilateral Nostrils for Pituitary Adenomas. *Neurologia Medico-Chirurgica*. 2009; 49 (1): 1–7.

Additional Information

Disclosures: Authors report no conflict of interest.

Ethical Review Board Approval: The study was conformed to the ethical review board requirements.

Human Subjects: Consent was obtained by all patients/ participants in this study.

Conflicts of Interest:

In compliance with the ICMJE uniform disclosure form, all authors declare the following:

Financial Relationships: All authors have declared that they have no financial relationships at present or within the previous three years with any organizations that might have an interest in the submitted work.


Other Relationships: All authors have declared that there are no other relationships or activities that could appear to have influenced the submitted work.

Address for Correspondence:

Dr. Yaser-ud-Din

Department of Neurosurgery Unit 1, Lahore General Hospital, Lahore – Pakistan

Email: yhcancer@yahoo.com

AUTHORSHIP AND CONTRIBUTION DECLARATION			
Sr.#	Author's Full Name	Intellectual/Contribution to Paper in Terms of:	Signature by the author(s) 
1.	Amir Aziz (Main/Principal Author).	1. Paper writing and Proof Reading.	
2.	Yaser-ud-Din (2nd Author)	2. Data collection and calculations	
3.	Zubair Ahmed (3rd Author)	3. Analysis of data and interpretation of results etc.	
4.	Sharukh Rizvi (4th Author)	4. Literature review and Discussion Writing.	
5.	Habib Sultan (5th Author)	5. Proposed topics and Basic Study Design, methodology.	
6.	Anwar Chaudhry (6th Author)	6. Performed Surgery or Supervised Surgery Quality Insurer.	
7.	Rizwan Masood (7th Author)	7. Supervised surgery or performed surgery.	

Date of Submission: 02-09-2019

Date of Revision: 28-10-2019

Date of Online Publishing: 25-12-2019

Date of Print: 31-12-2019