

Consequences of Streptococcal Pneumoniae Meningitis When it Remains Undiagnosed – Suggested Model of Investigational Process

SAMAR ABBAS JAFFRI,¹ SYEDA RIDA E ZEHRA,¹ SADIA SULTAN²

¹Department of Medicine, Liaquat National Hospital & Medical College

²Laboratory Services, National Medical Centre, Karachi

DOI: <https://doi.org/10.36552/pjns.v23i4.387>

ABSTRACT

Background: Whenever any patient presents with headache and slightly high total leukocytic counts, the pertinent question gets raised is either prompt lumbar puncture (LP) is indicated or not. Usually patients with bacterial meningitis characteristically exhibit fever, neck rigidity and deranged mental status or headache. In majority of cases the causes are non-infective. Whilst meningococcal meningitis has a distinctive non-blanching rash and is promptly diagnosable from the CSF. Our report describes disease presentation with merely one aspect of the triad for acute bacterial meningitis and it raises query regarding reliance on guidelines based on the triad.

Keywords: Streptococcal Pneumoniae, Meningococcal, Meningitis.

CASE PRESENTATION

58 years old patient presented with headache and vomiting for 7 hours. The patient had sudden and severe frontal headache but without photophobia. She did not smoke or drink alcohol. Examination revealed afebrile patient and normal findings on examination. Signs of meningeal irritation were absent on presentation. Her only significant finding was raised TLC count of 13.5/mcl and CRP was 5 u/l.

Virtually normal brain CT scan had ruled out Subarachnoid haemorrhage (SAH). Soon after her CT scan, her GCS was dropped to 10/15. CSF revealed a raised TLC count with 92% polymorphs and 8% lymphocytes. Gram positive diplococci and red blood cells were present in all three CSF samples. Repeat brain CT scan ruled out SAH as a cause of the CSF blood.

The patient was intubated and mechanically ventilated for 4 days – streptococci pneumoniae having been isolated on CSF culture with ceftriaxone 4 gm/d, prophylactic Enoxaparin, Omeprazole 40 mg/d for fourteen days whilst the patient was barrier nursed.

In the latter days of her stay, she was mildly cognitively impaired with mild right sided weakness. On MRI (Fig. 1) focal encephalitis and minor cortical hemorrhage were described.

DISCUSSION

Meningitis is a clinical syndrome characterized by inflammation and infection of the meningeal membrane that encloses the brain and spinal cord. It typically presents with the triad of fever, neck stiffness and headache/altered mental state.¹ There are no cutaneous or other pathognomic features of pneumococcal meningitis and, as a result, the diagnosis of this pathogen is easily delayed or missed altogether.

In the case described here only one feature of the triad was present on admission. And there was a delay before an alteration in the level of consciousness alerted the urgency for LP. Whilst there was a mildly raised white cell count the only features indicative of possible meningitis were headache and some nausea and vomiting. There were no predisposing risks for

meningitis such as pneumonia, sinusitis, endocarditis or skull fracture.^{2,3}

The lack of key features of the meningitis triad at presentation posed the threat of failure to diagnose the meningitis promptly. It also risked failure to commence therapy early. In one study of 396 patients with atypical presentation of acute bacterial meningitis, those treated within 30 minutes of hospital arrival had a far better outcome than patients with an atypical presentation and complex history that delayed diagnosis. In a prospective study of 156 patients with pneumococcal meningitis, a delay in antimicrobial treatment of more than three hours after hospital admission was a strong and independent risk factor for mortality. Delayed therapy was a greater risk factor than even the presence of a penicillin-resistant strain or a higher disease severity.⁴ Tunkel et al demonstrated that commencement of antibiotics after more than 3 hours of hospital stay leads to the highest mortality within 3 months.⁵ Such delays contribute to the high mortality rates seen in adults (approximately 20-30%).^{6,7}

In a retrospective study of 119 adults with bacterial meningitis, the most dramatic clinical predictor of death was the absence of fever at presentation. This finding, along with other "atypical features" (e.g. lack of headache or neck stiffness) was a significant contributor to the risk.⁸

Our case highlights how physicians need to be wary of apyrexial patients presenting with severe headache, no signs of meningeal irritation, no altered consciousness, no confusion, no tachycardia or hypotension and normal CRP on presentation. It might be argued that the WCC of 13.5/mcl was a diagnostic clue of notable importance. However, WCCs of such a level are not uncommon as a presentation of multiple disorders.

The current guidelines propose that a diagnosis of meningitis should be based on the presence of the triad of fever, neck stiffness and headache/altered mental status. And yet 56% of patients with meningitis do not exhibit such a triad (absent of headache).¹

The CRP was normal in our case and was considered reassuring since it is thought to be of significant negative predictive value.⁹ Its role in respect of the guidelines needs consideration since, being an acute phase reactant; it may not be elevated early in acute diseases such as pneumococcal meningitis.

In the case presented here a period of delay

occurred before the LP was performed. If this had been of longer duration the outcome might have been fatal since the MRI showed evidence of likely brain tissue injury already having occurred? If the level of consciousness had not dropped the patient might well have been monitored overnight until more indicative features such as fever and neck stiffness were identified.

Such a period of observation might be termed the Danger Period? Whilst in the current case it was relatively short, in other patients it may be prolonged and lethal. Periods of monitoring are typical in many

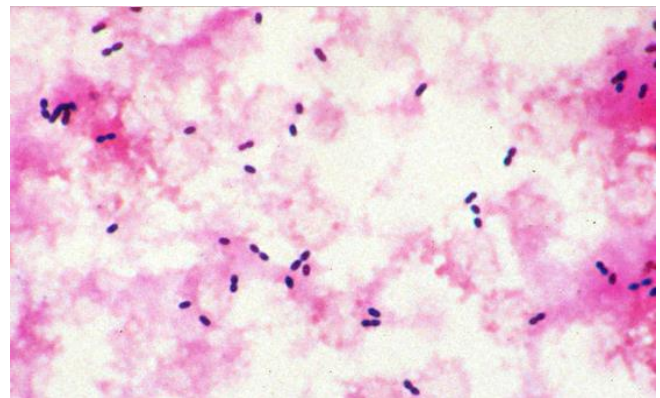


Fig. 1: *Streptococcus pneumoniae* appear as gram-positive diplococci. The cells are somewhat tapered at the ends giving the "lancet" shaped appearance.

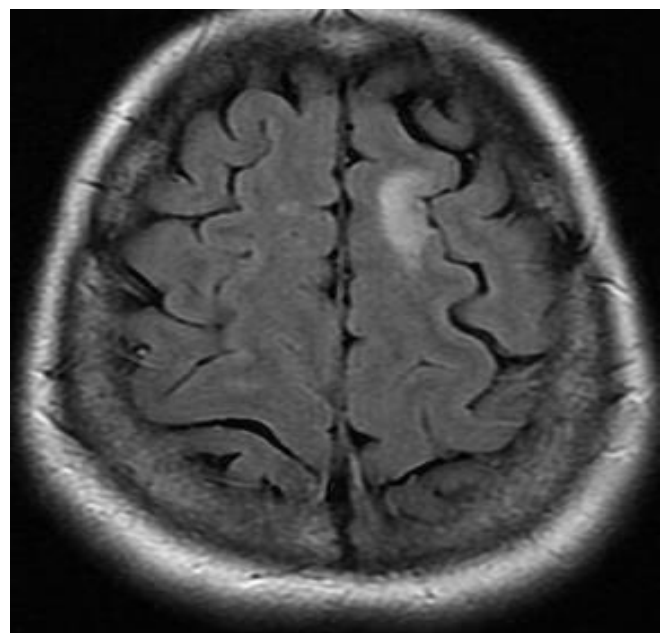


Fig. 2: MRI revealed focal encephalitis and minor cortical hemorrhage.

acutely presenting disorders when the features are not diagnostic. Our case highlights the importance of being alert to the Danger Period and being cautious in respect of monitoring when the patient fails to fulfill the full triad for the diagnosis of meningitis, and especially pneumococcal meningitis.

MODELLING INVESTIGATION DECISION MAKING: ALPHA, BETA, GAMMA

For general internal medicine physicians managing cases that present at acute admission facilities, decisions pathways on how to investigate the cause of patients' symptoms require careful consideration. In the majority of cases basic investigations are performed such as haematology, renal profiles, blood glucose, radiology and electrocardiography according to standard protocols. Such investigational decision making might be described as Alpha Phase I. Based on the results a second set of investigations may be decided upon. This might be described as Alpha Phase II investigation and include CT, echocardiography, LP etc. In some cases, and in some units, these may be part of an Alpha Phase I protocol – especially for certain neurological conditions presenting overtly.

Occasionally, after clinical assessment and evaluation of the key basic tests, question may arise as to whether an Alpha Phase II procedure such as an LP should be performed? That decision will often be based on clinical guidelines concerning the presumptive diagnosis. In the absence of a 'full house' triad such as that described for meningitis, conservative monitoring may be chosen. Such a 'holding' decision might be described as Beta. And if prolonged, it might be catastrophic.

In some cases, a decision to do an Alpha Phase I or II investigation such as a CT might be cancelled. Making such a 'cancel' decision might be described as Gamma and may have notable detrimental consequences for patients.

In the case of pneumococcal meningitis described here the Alpha Phase I tests only demonstrated a mildly elevated WCC. The clinical features of the case did not categorize the case as being one where an LP was urgently indicated. The admitting team were only alerted to the need for the Alpha Phase II test, (the LP), by the alteration in the patient's level of consciousness.

The period between the performance of the first brain CT and the change in mental state was relatively short in our case and so Beta was approximately 2

hours. If the level of consciousness had not changed there existed a risk that conservative monitoring would have occurred until further indication for the LP became apparent. With pneumococcal pneumonia infection present this could have been of major negative consequence from the patient's perspective and medic-legally from the admitting physicians' perspective.

Though it did not occur here, the performance of the LP was not prevented due to ankylosis of the spine etc. If such occurs, a Gamma situation will feature. And whereas in a case where there is a 'cancel' Gamma decision made and nothing is done investigatively or therapeutically, in an ankylosis-forced Gamma decision blind commencement of therapy etc may well have to be entertained. This should be a feature of modern guidelines.

Beta equates to the duration indicated by Alpha II–Alpha I in respect of investigational decision making.

$$\text{Beta} = \text{Alpha II} - \text{Alpha I (minutes)}$$

It may not equate to the period before the commencement of therapy which might be delayed as laboratory results are awaited. However, the decision to commence antibiotic therapy should be taken once the key tests have been performed (blood culture, LP etc) and so the Beta investigation period and Beta therapy delay can be considered to be equivalent.

In the literature in respect of pneumococcal meningitis a Beta period re-therapy commencement of no more than 30 minutes is advised. For other conditions such as acute myocardial infarction, cerebrovascular accidents etc Beta periods prior to undertaking thrombolysis have been measured. In respect of potentially lethal infections the Beta period needs to be as short as possible.

Atypical presentations of meningitis are the difficult and yet these tend to be observed in certain groups such as the more elderly and individuals with renal and liver disease, diabetes, alcoholism and AIDS.⁵

LIMITATIONS

The major limitations of our case report were: Inability to generalize our results, not possible to establish definitive relationship and our subjective perception may influence the case study.

CONCLUSIONS

A case of pneumococcal meningitis is presented where

the clinical indicators of the disease were few. The diagnosis was made after an alteration in the level of consciousness occurred. The case highlights that by following guidelines a prolonged period of observation may occur. That such a delay in investigation, which might be described as Beta, can occur should be highlighted. And it should be emphasized that Alpha Phase II investigations be performed sooner rather than later once the possibility of pneumococcal meningitis is considered. This is particularly so when the case presents totally or partially atypically because atypical symptoms at presentation are well described to make the diagnosis difficult and to delay treatment.¹⁰

To LP or not to LP, that is the question? In our case the fall in GCS was the trigger. If such had not occurred the diagnosis would have been delayed. It might be a policy that **“All Acute Neurology is Strep Pneumoniae Meningitis until Proven Otherwise”?**

Disclosure

This case was presented in 3rd Euro-Global Experts Meeting Valencia, Spain.

REFERENCES

1. Van de Beek D, de Gans J, Spanjaard L, Weisfelt M, Reitsma JB, Vermeulen M. Clinical features and prognostic factors in adults with bacterial meningitis. *N Engl J Med*. 2004; 351 (18): 1849-59. Doi:10.1056/NEJMoa040845
2. Mann K, Jackson MA. Meningitis. *Pediatr Rev*. 2008; 29 (12): 417-29; Quiz 430. Doi:10.1542/pir.29-12-417.
3. Brouwer MC, Thwaites GE, Tunkel AR, van de Beek D. Dilemmas in the diagnosis of acute community-acquired bacterial meningitis. *Lancet*. 2012; 380 (9854): 1684-92. Doi:10.1016/S0140-6736(12)61185-4.
4. Lepur D, Barsić B. Community-acquired bacterial meningitis in adults: antibiotic timing in disease course and outcome. *Infection*. 2007 Jun; 35 (4): 225-31. Doi:10.1007/s15010-007-6202-0
5. Tunkel AR, Hartman BJ, Kaplan SL, Kaufman BA, Roos KL, Scheld WM, et al. Practice guidelines for the management of bacterial meningitis. *Clin Infect Dis*. 2004; 39 (9): 1267-84. Doi:10.1086/425368
6. Weisfelt M, van de Beek D, Spanjaard L, Reitsma JB, de Gans J. Clinical features, complications, and outcome in adults with pneumococcal meningitis: a prospective case series. *Lancet Neurol*. 2006; 5 (2): 123-9. Doi:10.1016/S1474-4422(05)70288-X
7. Koedel U, Klein M, Pfister HW. New understandings on the pathophysiology of bacterial meningitis. *Curr Opin Infect Dis*. 2010; 23 (3): 217-23. Doi:10.1097/QCO.0b013e328337f49e.
8. Auburtin M, Wolff M, Charpentier J, Varon E, Le Tulzo Y, Girault C, et al. Detrimental role of delayed antibiotic administration and penicillin-nonsusceptible strains in adult intensive care unit patients with pneumococcal meningitis: the PNEUMOREA prospective multicenter study. *Crit Care Med*. 2006; 34: 2758. Doi:10.1097/01.CCM.0000239434.26669.65
9. Gerdes LU, Jorgensen PE, Nexø E, Wang P. C-reactive protein and bacterial meningitis: a meta-analysis. *Scand J Clin Lab Invest* 1998; 58: 383-9. Doi:10.1080/00365519850186364
10. Attia J, Hatala R, Cook DJ, Wong JG. The rational clinical examination. Does this adult patient have acute meningitis? *JAMA*. 1999; 282 (2): 175-81. Doi:10.1001/jama.282.2.175

Additional Information

Disclosures: Authors report no conflict of interest.

Ethical Review Board Approval: The study was conformed to the ethical review board requirements.

Human Subjects: Consent was obtained by all patients/ participants in this study.


Conflicts of Interest:

In compliance with the ICMJE uniform disclosure form, all authors declare the following:

Financial Relationships: All authors have declared that they have no financial relationships at present or within the previous three years with any organizations that might have an interest in the submitted work.

Other Relationships: All authors have declared that there are no other relationships or activities that could appear to have influenced the submitted work.

*Address for Correspondence: Dr. Samar Abbas Jaffri
Department of Medicine
Liaquat National Hospital & Medical College
Karachi*

AUTHORSHIP AND CONTRIBUTION DECLARATION			
Sr.#	Author's Full Name	Intellectual/Contribution to Paper in Terms of:	Signature by the author(s) Signature 
1.	Samar Abbas Jaffri (Main/Principal Author).	1. Proposed Topics and Basic Study Design, Methodology.	
2.	Syeda Rida E Zehra (2nd Author)	2. Data Collection and Calculations. Paper Writing.	
3.	Sadia Sultan (3rd Author)	3. Analysis of Data and Interpretation of Results etc.	

Date of Submission: 13-09-2019

Date of Revision: 29-11-2019

Date of Online Publishing: 25-12-2019

Date of Print: 31-12-2019