

Original Research

Beyond the Sella: Role of Sphenoid Sinus Pneumatization and Anatomical Variations in Determining Outcomes of Endoscopic Pituitary Surgery

Usman Ahmad¹, Syed Shahzad Hussain Shah¹, Muhammad Irfan¹, Mehwish Manzoor²
Omair Afzal¹, Hamza Iqbal¹, Tehreem Asif³

¹Department of Neurosurgery, Unit 2, Punjab Institute of Neurosciences (PINS), Lahore

²Department of Medical Oncology, King Edward Medical University (KEMU), Mayo Hospital, Lahore

³Ameer U Din Medical College/Postgraduate Medical Institute Lahore General Hospital Lahore – Pakistan

ABSTRACT

Objective: To assess whether anatomical variations of the sphenoid sinus (including pneumatization type, extent, course of optic nerve, and septal morphology) have an influence on surgical outcomes of endoscopic transsphenoidal surgery (ETSS) for pituitary tumors.

Materials & Methods: A prospective cohort study was conducted at the Institute of Neurosciences, Lahore. We analyzed the details of 81 patients who underwent ETSS from June 2025 to December 2025. Sphenoid sinus pneumatization (pre-sellar, sellar, post-sellar), the degree of pneumatization (none, lateral extent, clivus extent, and lesser wing), Optic Nerve (ON) type (Type 1–4), and septum (single vs. double) were evaluated on preoperative CT FESS. The relations between the anatomic parameters and operative results—operation time, and intra- and post-operative complications, improvement in the neurological function—were evaluated using the chi-square test and Fisher's exact test.

Results: Majority of the patients were male, with a mean age of 46.8 ± 12.7 years, having a tumor exceeding 50 mm in size, in >70% cases, with larger tumor size meaning longer surgical duration, as also seen in lateral and clival extension types. Sellar pneumatization pattern was most common, but pre-Sellar and post-Sellar varieties, along with clival extent and type 3 ON, were associated with a higher incidence of intra- and post-op complications. The inter-sphenoid septum type didn't have any impact on surgical outcomes.

Conclusion: The anatomy of the sphenoid sinus has a marked effect on safety and ease of ETSS. Preoperative high-resolution CT FESS showing the type and extent of pneumatization and optic nerve variations should be a mandatory step in risk stratification and tailored treatment to avoid neuro-vascular injuries.

Keywords: Endoscopic transsphenoidal surgery; Pituitary tumors; Sphenoid sinus anatomy; Pneumatization; Optic nerve; CT FESS; Neurosurgical outcome

Corresponding Author: Usman Ahmad
Department of Neurosurgery, Unit 2, Punjab Institute of
Neurosciences (PINS), Lahore
Email: usmanschemer644@hotmail.com

Date of Revision: 11-06-2026
Date of Acceptance: 13-06-2026
Date of Online Publishing: 17-6-2026
Date of Print: 30-6-2026

Date of Submission: 17-02-2026

DOI: 10.36552/pjns.v30i2.1251

INTRODUCTION

Pituitary tumors are one of the most common sellar pathologies and are reported to have a 15% incidence out of all benign intracranial lesions.¹ They can present with a plethora of symptoms, including hormonal irregularities, pressure effects on surrounding structures, but they can also be an incidental finding in 5-20% of cases.² The treatment of choice for pituitary tumors is surgery, with various approaches, including transcranial approach, transsphenoidal microscopic approach, and endoscopic endonasal transsphenoidal approach.

Endoscopic transsphenoidal surgery (ETSS) has become the gold standard procedure for sellar and parasellar surgeries, with better lighting, magnification, and minimal invasion.¹⁻³ The majority of the procedures being performed for pituitary tumor excision involve an endoscopic approach these days. The sphenoid sinus is a deep-seated and posterior-most paranasal sinus, with the most variable anatomy among all paranasal sinuses, and is anatomically related to important neuro-vascular structures, which makes it technically very demanding to use this corridor for the surgical excision of pituitary tumors.⁴⁻⁵

Pneumatization of the sphenoid sinus can range from a conchal to pre-sellar, sellar, and post-sellar pneumatized sinus.⁶ Such variations can have an impact on operative exposure, surgical time, and risk of complications.⁷ Also, the proximity of the optic nerve to the sinus wall may predispose to direct injury during operation, especially within Type III variants in which the optic nerve traverses through the sphenoid sinus.⁸⁻¹²

While these anatomic differences have been previously reported, few studies have systematically evaluated the quantitative impact of these variations on the intraoperative complications and outcomes in ETSS. The present study aims to investigate the association of various sphenoid sinus morphologies with intraoperative findings and neurosurgical outcomes in patients with pituitary tumors, thereby attempting to

establish a strong anatomic foundation for pre-operative risk stratification and surgical management.

MATERIAL & METHODS

Study Design & Setting

This prospective cohort, descriptive study was carried out in the Department of Neurosurgery, Unit-2, Punjab Institute of Neurosciences, Lahore, Pakistan, from June 2025 to December 2025. The study was approved by the Institutional Review Board of PINS following the Declaration of Helsinki. (2187/IRB/PINS/Approval/2025).

Sample Size

The sample size was calculated using the OpenEpi calculator. After obtaining informed written consent, a total of 81 patients of either gender, aged between 18 and 70 years, were included in the study.

Inclusion Criteria

Patients with pituitary tumors and preoperative paranasal sinuses, high resolution CT scan was available, planned for endoscopic transsphenoidal surgery were included.

Exclusion Criteria

Patients who had a history of skull base surgery, trauma, incomplete imaging, or those with significant craniofacial malformations were excluded.

Data Collection Procedure

Patients' demographic data, including name, age, gender, duration of disease, and presenting symptoms, were recorded in a pre-designed patient proforma. For each patient, preoperative CT FESS images were reviewed in axial, coronal, and sagittal sections. The following classifications were applied:

Pneumatization pattern: pre-sellar, sellar, post-sellar (relative to sella turcica).

Degree of Pneumatization: none, lateral, clival, or in the lesser wing.

Optic nerve classification: Type 1–4, as per Moisés-Hernández’s criteria⁷.

Septum Design: single (Type 1) or double (Type 2).

All patients were treated with standard binostril endoscopic transsphenoidal surgery. Suction, curettage, and angled endoscopes were used for the tumor resection under direct vision. Autologous fat and fascia grafts were used for reconstruction when needed.

Data Analysis Procedure

Intraoperative complications (CSF leakage, bleeding, abandoned surgery), postoperative complications (CSF leak, DI, hypopituitarism, infection), duration of surgery, and neurological status (postoperative improvement/stability/deterioration) were assessed and recorded. All patients had follow-up with a medical oncologist as part of the multidisciplinary board. Statistical Package for the Social Sciences (SPSS) version 26 was used for data analysis. For continuous variables, the mean and standard deviation were calculated, whereas for categorical data, frequencies and percentages were expressed. Association was evaluated using the chi-square and Fisher's exact test. A p-value of <0.05 was considered statistically significant.

RESULTS

Demographics

Among 81 patients, the mean age was 46.8 ± 12.7 years; 53.1% were male. Tumor size exceeded 50 mm in 70.37% of cases.

Classification of Sphenoid

Sellar pneumatization pattern was the most common (88.89%), with no extension (61.73%)

Table 1: Summary of key variables.

Category	Value	Count	%
Tumor Size	>50mm	57	70.37
	20-50mm	24	29.63
Surgical	<10	22	27.16
Duration (mins) (Sphenoid phase)	10–20	34	41.98
	20–30	9	11.11
	>30	16	19.75
Pneumatization Pattern	Sellar	72	88.89
	Pre-sellar	3	3.70
	Post-sellar	6	7.41
Pneumatization Extent	None	50	61.73
	Lateral	14	17.28
	Clival	14	17.28
	Lesser wing	3	3.70
Optic Nerve Type	1	6	7.41
	2	22	27.16
	3	32	39.51
	4	21	25.93
Septum Type	Single	19	23.46
	Double	62	76.54
Intra-op Complications	None	68	83.95
	CSF leak	8	9.88
	Abandoned	5	6.17
Post-op Complications	None	61	75.31
	DI	8	9.88
	Hypopituitarism	6	7.41
Neurological Outcome	Infection	6	7.41
	Improved	42	51.85
	Same	33	40.74
	Worsened	5	6.17

being the most frequent pattern. Larger tumors (>50 mm) were associated with longer surgical duration (p = 0.017), but tumor size showed no significant association with neurological improvement. Pre-sellar and post-sellar varieties were associated with a higher incidence of intra- and post-operative complications (p < 0.01) and longer surgical duration (p < 0.001). Lateral and clival extents were found to have longer surgical duration (p < 0.001), while clival pneumatization trended towards more post-operative complications (p = 0.064). Type 3 ON variety showed higher intra-op (p = 0.013) and post-op complications (p = 0.036). No significant association was found between septum type and surgical outcomes (p>0.5).

Complications

The most common intra-op complication was CSF Leak (9.88%), while the most common post-op complication was Diabetes Insipidus (9.88%, usually transient). 51.85% of patients' neurological improvement after surgery.

No significant association between tumor size and neurological outcomes ($p = 0.236$).

Larger tumors (>50 mm) were significantly associated with longer surgical duration ($p = 0.017$).

Pre- and post-sellar pneumatization were significantly associated with intra- and postoperative complications ($p < 0.01$) and longer surgical durations ($p < 0.001$).

Lateral and clival extents correlated with longer surgeries ($p < 0.001$); clival pneumatization trended toward more postoperative complications ($p = 0.064$).

Type 3 optic nerve was significantly associated with higher intra-operative ($p = 0.013$) and postoperative ($p = 0.036$) complications.

No significant association was observed between septum type and surgical parameters ($p > 0.5$).

DISCUSSION

Endoscopic transsphenoidal surgery (ETSS) is now the preferred surgical choice for pituitary tumors because it provides superior illumination, panoramic visualization, and reduced morbidity compared with microscopic and transcranial techniques. However, the sphenoid sinus represents the primary surgical

Table 2: Tumor Size and Neurological Outcomes.

Tumor Size	Improved	Same	Worsened	Unknown	p-value
>50 mm	29	25	2	1	0.236
20-50 mm	13	8	3	0	

Table 3: Tumor Size and Surgical Duration.

Tumor Size	<10 mins	10–20 mins	20–30 mins	>30 mins	p-value
>5 cm	12	22	9	14	0.017*
2–5 cm	10	12	0	2	

Table 4: Pneumatization Pattern vs Surgical Outcomes.

Table 4(a): Intraoperative Complications.

Type	None	CSF Leak	Abandoned	p-value
Sellar	62	5	5	0.002
Pre-sellar	3	0	0	
Post-sellar	3	3	0	

Table 4(b): Postoperative Complications.

Type	None	DI	Hypopituitarism	Infection	p-value
Sellar	57	5	4	6	0.005
Pre-sellar	0	0	0	3	
Post-sellar	4	3	2	0	

Table 4(c): Surgical Duration.

Type	<10 mins	10–20 mins	20–30 mins	>30 mins	p-value
Sellar	22	31	9	10	<0.001
Pre-sellar	0	0	0	3	
Post-sellar	0	3	0	3	

Table 5(a): Pneumatization Extent vs Surgical Outcomes: Intraoperative Complications.

Extent	None	CSF Leak	Abandoned	p-value
None	46	2	2	0.114
Lateral	10	2	2	
Clival	10	4	0	
Lesser wing	2	0	1	

corridor and demonstrates substantial anatomical variability, which may directly influence surgical exposure, operative duration, and complication risk.

In our study, sellar pneumatization was the most common pattern, observed in 88.89% of patients (Table 1). This finding is consistent with previous anatomical and radiological studies, which have reported sellar pneumatization as the predominant configuration in the majority of individuals. Hamid et al,⁶ and Fadda et al,⁹ similarly reported, sellar pneumatization in more than 80% of cases and noted that this configuration provides optimal surgical access due to increased sinus volume and improved anatomical orientation. Reduced pneumatization, such as pre-sellar type, limits surgical working space and may obscure important anatomical landmarks, thereby increasing operative difficulty.

Our results demonstrated that post-sellar pneumatization patterns were significantly associated with increased intraoperative and postoperative complications and prolonged surgical duration (Table 4). This association can be explained by altered anatomical relationships between the sphenoid sinus and critical neurovascular structures. In pre-sellar pneumatization, limited sinus development results in reduced surgical working space and increased need for bone drilling, thereby increasing operative time and risk of complications, but we have only a few cases, i.e., 3(3.70%), and among them, only infection was found. Due to the small number of cases with pre-sellar type complications, risks

cannot be quantified. Post-sellar pneumatization, on the other hand, may expose critical structures such as the internal carotid artery and optic nerve,

Table 5(b): Pneumatization Extent vs Surgical Outcomes: Postoperative Complications.

Extent	None	DI	Hypopituitarism	Infection	p-value
None	42	2	2	4	0.064
Lateral	9	2	1	2	
Clival	8	4	3	0	
Lesser wing	2	0	0	1	

Table 5(c): Surgical Duration.

Extent	<10 mins	10–20 mins	20–30 mins	>30 mins	p-value
None	20	22	8	0	<0.001
Lateral	2	3	0	9	
Clival	0	8	0	6	
Lesser wing	0	1	1	1	

Table 6(a): Optic Nerve Type vs Surgical Outcomes: Intraoperative Complications.

Type	None	CSF Leak	Abandoned	p-value
Type 1	6	0	0	0.013
Type 2	17	3	2	
Type 3	24	5	3	
Type 4	21	0	0	

Table 6(b): Optic Nerve Type vs Surgical Outcomes: Postoperative Complications.

Type	None	DI	Hypopituitarism	Infection	p-value
Type 1	6	0	0	0	0.036
Type 2	16	2	1	3	
Type 3	21	6	5	3	
Type 4	18	0	0	3	

Table 6(c): Optic Nerve Type vs Surgical Outcomes: Surgical Duration.

Type	<10 mins	10–20 mins	20–30 mins	>30 mins	p-value
Type 1	2	4	0	0	0.147
Type 2	7	8	0	7	
Type 3	7	14	2	9	
Type 4	6	8	7	0	

increasing vulnerability to injury. Similar findings were reported by Tesfaye et al, who demonstrated that altered sphenoid sinus pneumatization significantly increases surgical complexity and complication rates.

Optic nerve configuration was also found to significantly influence surgical outcomes. Type 3 optic nerve configuration showed a significantly higher rate of intraoperative and postoperative complications in our study (Table 6). This finding is consistent with Moisés-Hernández et al,⁷ and Açar et al,⁸ who reported that optic nerve protrusion into the sphenoid sinus increases susceptibility to injury due to reduced bony protection and closer proximity to the surgical field. These anatomical variations

Table 7 (a): Septum Type vs Surgical Outcomes: Intraoperative Complications.

Septum	None	CSF Leak	Abandoned	p-value
Single	15	3	1	0.544
Double	53	5	4	

Table 7(b): Septum Type vs Surgical Outcomes: Postoperative Complications.

Septum	None	DI	Hypopituitarism	Infection	p-value
Single	15	1	1	2	0.859
Double	46	7	5	4	

Table 7(c): Septum Type vs Surgical Outcomes: Surgical Duration.

Septum	<10 mins	10–20 mins	20–30 mins	>30 mins	p-value
Single	6	8	2	3	0.617
Double	16	26	7	13	

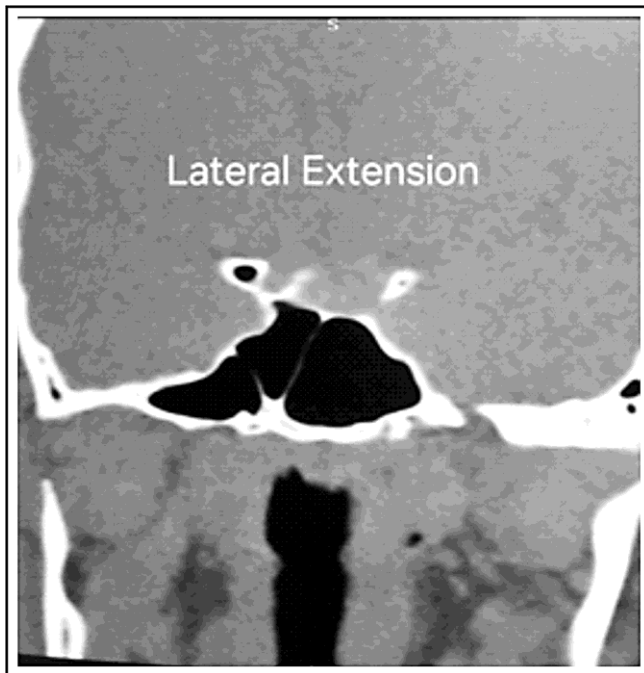


Figure 1: Showing lateral extension of pneumatization (Consent taken from patient).

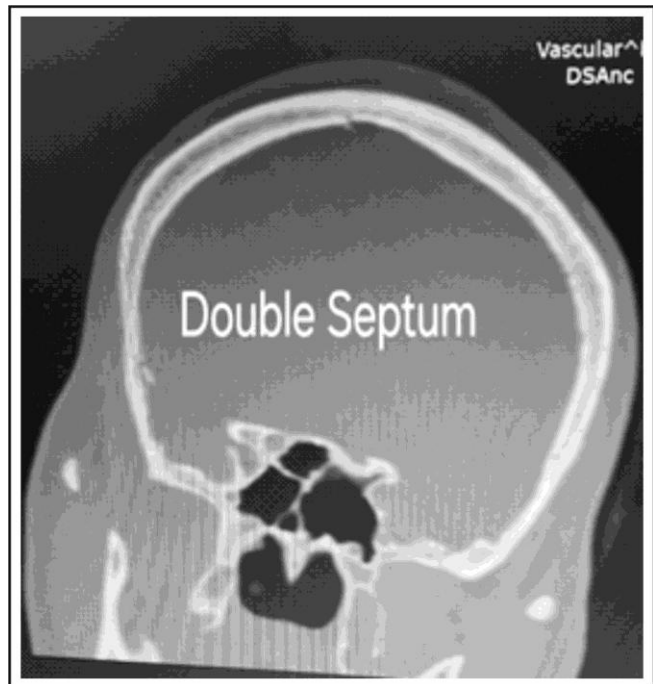


Figure 2: Showing double inter-sphenoid septum (Consent taken from patient).

increase the risk of direct mechanical injury, thermal injury, or vascular compromise during surgical manipulation.

The intraoperative cerebrospinal fluid leak rate in this study was 9.88%, which is comparable to previously reported rates ranging from 5% to 15%.

Similarly, postoperative diabetes insipidus occurred in 9.88% of patients, which is consistent with published ETSS complication rates (Table 1). These findings indicate that overall surgical outcomes in this study are comparable with international standards.

Tumor size was significantly associated with increased surgical duration but did not significantly influence neurological outcome. This suggests that anatomical accessibility, rather than tumor size alone, plays a more critical role in determining surgical complexity. Torales et al,² reported similar findings, demonstrating that anatomical factors, including sphenoid sinus configuration and tumor extension pattern, have a greater impact on surgical difficulty than tumor size alone.

Preoperative CT imaging plays a crucial role in identifying high-risk anatomical variants. Accurate identification of the sphenoid sinus pneumatization pattern and optic nerve configuration allows surgeons to anticipate technical challenges, optimize surgical planning, and reduce complication risk. Preoperative anatomical assessment is particularly important in patients with high-risk configurations, such as Type 3 optic nerve (Fig. 1).

Contemporary studies have further highlighted the importance of detailed preoperative assessment of sphenoid sinus anatomy before ETSS. Variations in pneumatization and optic nerve course can significantly alter the surgical corridor and increase the risk of neurovascular injury during surgery. Previous authors have shown that lateral and clival pneumatization are frequently associated with more complex anatomy and difficult surgical exposure. In our study, lateral and clival extensions were associated with prolonged operative duration, as demonstrated in Table 5(c), while Type 3 optic nerve configuration showed significantly higher intraoperative and postoperative complications (Tables 6(a) and 6(b)). Similarly, the predominance of sellar pneumatization in our cohort (Table 1) is

consistent with previously published anatomical studies. These findings emphasize that preoperative CT-FESS should be considered an essential surgical roadmap for safer ETSS planning and execution.¹⁰⁻¹²

Another important finding of this study was that sphenoid sinus anatomy appeared to influence surgical difficulty more than tumor size alone. Although larger tumors were associated with longer operative duration (Table 3), neurological outcomes were not significantly affected by tumor size (Table 2). This suggests that anatomical accessibility and proximity to critical neurovascular structures may play a more important role in determining operative complexity and complications. Furthermore, septum morphology showed no significant association with surgical outcomes in our cohort, as shown in Tables 7(a–c), which is comparable with previous reports.^{13,14} Overall, these findings support the growing role of individualized anatomical risk stratification and detailed preoperative imaging in improving the safety and outcomes of endoscopic pituitary surgery.

Clinical Implications

These findings reiterate standard CT-based anatomic mapping before ETSS. Pre- and post-sellar pneumatization and Type 3 ON may be considered as high-risk configurations, which should guide intra-operative navigation for extended sellar reconstruction. Our findings demonstrate that careful preoperative anatomical evaluation can help anticipate surgical difficulty and reduce complications.

LIMITATIONS

This was a single-center, prospective study, and for rare variants, it had inadequate numbers ($n = 3$ [pre-sellar], 6 [post-sellar]). Statistical significance for these subsets should be taken with caution. Larger multicentric studies are recommended.

CONCLUSION

Sphenoid sinus anatomical variations, particularly pneumatization pattern and optic nerve configuration, significantly influence operative duration and complication risk in endoscopic transsphenoidal surgery. Pre-sellar and post-sellar pneumatization, as well as Type 3 optic nerve configuration, are associated with increased surgical complexity and higher complication rates. Preoperative CT-based anatomical evaluation is essential for surgical planning and risk stratification to improve surgical safety and outcomes.

REFERENCES

1. Sanno N, Teramoto A, Osamura RY, Horvath E, Kovacs K, Lloyd RV, et al. Pathology of pituitary tumors. *Neurosurg Clin N Am.* 2003;14(1):25–39. Doi: 10.1016/S1042-3680(02)00055-4.
2. Torales J, Halperin I, Hanzu F, Mora M, Alobid I, De Notaris M, et al. Endoscopic endonasal surgery for pituitary tumors. *Endocrinol Nutr.* 2014;61(8):410–416. Doi: 10.1016/j.endonu.2014.03.004.
3. Weiland T, et al. Surgical outcomes of endoscopic transsphenoidal pituitary surgery. *Eur Arch Otorhinolaryngol.* 2023;280(8):3451–3459. Doi: 10.1007/s00405-023-07964-1.
4. Nakaya M, et al. Endoscopic transsphenoidal surgery outcomes. *Front Neurol.* 2023;14:1162733. Doi: 10.3389/fneur.2023.1162733.
5. Tesfaye S, Gebrewold Y, Hailu A, et al. Anatomical variations of sphenoid sinus. *Transl Res Anat.* 2021;24:100126. Doi: 10.1016/j.tria.2021.100126.
6. Hamid O, El Fiky L, Hassan O, Kotb A, El Fiky S. Anatomical variations of sphenoid sinus. *Skull Base.* 2008;18(1):9–15. Doi: 10.1055/s-2007-992764.
7. Moisés-Hernández JF, González-Aguirre AJ, et al. Optic nerve variations. *Rev Med Hosp Gen Mex.* 2024;87(3):175–183. Doi: 10.24875/RMHGM.23000073.
8. Açar G, Koseoglu A, et al. Optic nerve protrusion. *Neurosurg Rev.* 2024;47(1):56. Doi: 10.1007/s10143-023-02138-9.
9. Fadda GL, Rosso S, et al. Radiological study of sphenoid sinus. *Head Face Med.* 2022;18(1):16. Doi: 10.1186/s13005-022-00307-9.
10. El-Kammash TH, Enaba MM, Awadalla AM. Variability in sphenoid sinus pneumatization and its impact upon reduction of complications following sellar region surgeries. *Egypt J Radiol Nucl Med.* 2014;45(3):705–714. Doi: 10.1016/j.ejrn.2014.04.010.
11. Unal B, Bademci G, Bilgili YK, Batay F, Avci E. Risky anatomic variations of sphenoid sinus for surgery. *Surg Radiol Anat.* 2006;28(2):195–201. Doi: 10.1007/s00276-005-0073-9.
12. Wang J, Bidari S, Inoue K, Yang H, Rhoton AL Jr. Extensions of the sphenoid sinus: a new classification. *Neurosurgery.* 2010;66(4):797–816. Doi: 10.1227/01.NEU.0000367619.24800.B1.
13. Gupta T, Aggarwal A, Sahni D. Anatomical variations of sphenoid sinus and their impact on trans-sphenoid pituitary surgery. *Surg Radiol Anat.* 2013;35(1):37–43. Doi: 10.1007/s00276-012-0993-8.
14. Hewaidi GH, Omami GM. Anatomic variation of sphenoid sinus and related structures in Libyan population: CT scan study. *Libyan J Med.* 2008;3(3):128–133. Doi: 10.4176/080207.

Additional Information

Disclosures: No conflict of interest

Institutional Ethical Review Board Approval: The study complies with the ethical review board requirements.

Human Subject: Consent was obtained from all patients/participants in this study.

Conflict of Interest: In compliance with the ICMJE uniform disclosure form, all authors declare the following:

Financial Relationships: All authors have declared that they have no financial relationship at present or within the previous three years with any organization that might have an interest in the submitted work.

Other Relationships: All authors have declared that no other relationships or activities could appear to have influenced the submitted work.

Data sharing Statement: For data sharing, interested researchers can contact the corresponding authors.

AUTHOR'S CONTRIBUTION

Sr.	Author Name	Author contribution
1.	Usman Ahmad	Paper writing, study design, and methodology.
2.	Muhammad Irfan	Literature review.
3.	Omair Afzal and Hamza Iqbal	Data analysis and interpretation of results.
4.	Mehwish Manzoor	Discussion.
5.	Tehreem Asif	Data collection.
6.	Syed Shahzad Hussain Shah	Quality insurer.