

# Primary Decompressive Craniectomy – Salvation in Closed TBI

FAIQA FILZA KHAN, MUHAMMAD NAWAZ, TARIQ KHAN

Department of Neurosurgery, Northwest General Hospital and Research Centre, Peshawar – Pakistan

## ABSTRACT

**Objective:** To evaluate the role of early Decompressive Craniectomy in closed traumatic brain injury in relation to functional outcome.

**Material and Methods:** A study was conducted at the Department of Neurosurgery, Northwest General Hospital and Research Centre Peshawar Pakistan. 09 months Data from 22/06/2011 to 21/03/2012 was collected, and all the consecutive cases of closed head injury that required Decompressive Craniectomy (Primary Decompression) based on clinical and radiological findings were included in the study.

**Results:** Out of 23 patients, 13 showed moderate to good recovery making this procedure one of the priority treatment options in closed traumatic brain injury.

**Conclusion:** The promising outcome in our study suggests that an early Decompressive Craniectomy should be considered in severe closed head injury to improve the outcome.

**Key words:** Decompressive Craniectomy, Intracranial hypertension, Traumatic brain injury.

**Abbreviations:** TBI = Traumatic Brain Injury, ICP = Intracranial Pressure, DC = Decompressive craniectomy.

## INTRODUCTION

Most of the severe traumatic brain injury patients often present with a progressive increase in intracranial pressure, leading to clinical deterioration and ultimately death. Medical treatment alone can help to control such increases in pressure, but intracranial hypertension becomes life – threatening in some patients.

Despite the controversy in establishing the role of “Decompressive Craniectomy” it is still used worldwide for the treatment of uncontrollable intracranial hypertension. Munch, et al,<sup>1</sup> reported a 72% poor outcome versus a good recovery of 28% at discharge. However, at 6 months the favorable outcome had increased to 41% and the poor outcome decreased to 59%. The European Brain Injury Consortium and Brain Trauma Foundation guidelines for severe TBIs refers to decompressive craniectomy as a second-tier therapy for refractory intracranial hypertension that does not respond to conventional therapeutic measures<sup>2,3</sup> which include 10 – degree head elevation, sedation, hyperventilation, osmotic diuresis, cerebrospinal fluid (CSF) drainage, and barbiturate-induced coma.<sup>4,5</sup>

More recently, various studies on the use of early Decompressive Craniectomy after severe head trauma have reported a good outcome (GOS 4 and 5) in these patients.

The purpose of this study was to evaluate the efficacy of the immediate surgical intervention to achieve a better survival chance and functional prognosis in closed TBI.

**The Procedure:** It is a surgical procedure in which part of the skull is removed to allow the brain to swell without being compressed against the vault. There are currently various decompressive craniectomy methods used; These include:

1. Subtemporal decompression<sup>6,7</sup>
2. large fronto-temporoparietal decompressive craniectomy,
3. bifrontal decompressive craniectomy.<sup>8</sup>

**In subtemporal approach** a circular bone is taken out, but the area of the skull removed is small and the room that it can provide for the expansion of the brain is restricted.

The decompressive effect depends primarily on the size of the part of the skull removed, so we preferred a fronto-temporo-parietal approach as it seemed to lead to better outcomes in patients with severe TBI compared with other varieties of surgical decompression in previous literature.<sup>9,10</sup> Also decompressive craniectomy combined with duroplasty is widely performed and is recommended by most authors.<sup>11</sup>

In our study procedure was performed within 24 hours (mean 9.1 hours) of arrival to hospital. All the patients received standardized medical management plus cerebral decompression. They all were admitted to surgical ICU and were mechanically ventilated for 72 hours. After the procedure bone flap was preserved in Pathology lab at -40°C to be replaced later in the 2<sup>nd</sup> sitting.

**MATERIALS AND METHOD**

The study was conducted at the Department of Neurosurgery, Northwest General Hospital and Research Centre Peshawar Pakistan. 09 months Data from 22/06/2011 to 21/03/2012 was collected and total number of cases was 23. It is a cross – sectional study.

**Patient Selection**

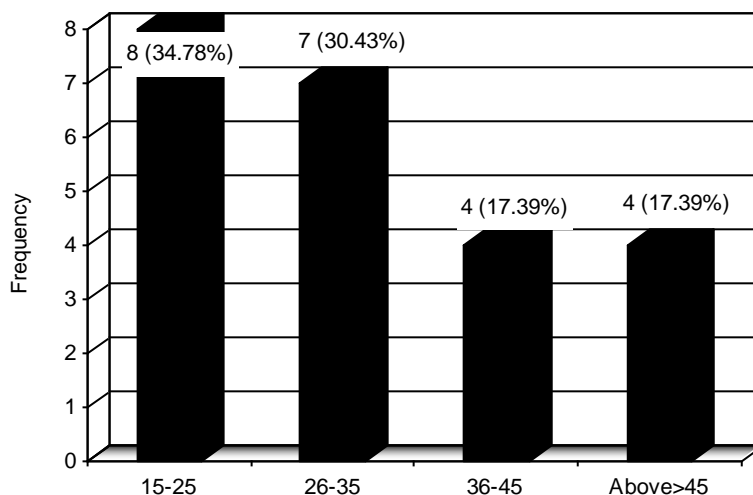
The study included patients with closed traumatic brain injury, with an age range

**Table 1: Descriptive Statistics (Mean Age).**

	N	Minimum	Maximum	Mean	Std. Deviation
Age	23	16	50	31.57	11.003

**Table 2: Age Groups.**

	Frequency	Percent	Cumulative Percent
15 – 25	8	34.8	34.8
26 – 35	7	30.4	65.2
36 – 45	4	17.4	82.6
Above > 45	4	17.4	100.0
Total	23	100.0	



**Fig. 1: Age Group.**

**Table 3: Age group \* Outcome Cross tabulation.**

		Moderate to Good Recovery	Severe Disability	Vegetative	Expired	
Age Group	15 – 25	6	0	2	0	8
	26 – 35	4	0	0	3	7
	36 – 45	3	1	0	0	4
	Above > 45	0	3	0	1	4
Total		13	4	2	4	23

of 15 to 55 years, admitted to ICU under neurosurgical care. Diagnostic confirmation of the condition was

both clinical (vital record, GCS, pupils) and radiological. CT scan findings were diffuse brain edema with

or without brain contusions and subdural hematoma. The effacement of basal cisterns and ventricles were the common feature to all CT scans. Some had midline shift and mass effect to contusions / hematomas but no documented extradural, subdural or intracerebral hematoma which needed evacuation were included in the study. Timing of surgery was within 24 hours of the arrival to the hospital (mean 9.1 hours). Exclusion criteria were the presence of co-morbid factors and severe extra cranial injuries needing specialty care.

**Data Acquisition**

All patients treated with DC over the time period of the study were recorded. Subsequently, epidemiologic and clinical data such as cause of injury, neurological and radiological examinations were also noted. Patients were observed closely both pre and post operatively till the time of discharge. GOS and general status were recorded at time of discharge, one month, 03 months, 06 months and then one year follow up before making the final conclusion.

**Statistical Analysis**

Data was analyzed by the Epidemiologists at Department of medical education, Northwest General Hospital and Research center Peshawar. Latest version of SPSS was implicated in calculating the data.

**RESULTS**

Total of 23 cases who underwent the procedure comprised 17 patients from Afghanistan and 06 from neighboring areas of Peshawar.

**Age Range**

Age range was from 16 to 50 years (mean 31.57) table 1 and Fig. 1. The frequency and percent of age has been shown in table 2.

**Sex Incidence**

There were 20 male (87%) and 3 (13%) female patients (table 5, Fig. 2)

**Mode of trauma:** RTA: 16 patients, Fall: 5, Assault: 02.

**Condition on Arrival:** GCS 9/15 or above 9 (39%) patients had GCS 8/15, 5 (21%) patients had GCS of 8, GCS 7/15, 4 (18%) patients had GCS of 7, 02

patients had GCS of 6/15 2 (9%) and 03 had GCS of 5/15, 3 (13%) patients (table 7, Fig. 4).

**Pupils:** Reactive and equal in 11 patients, Anisocoria: 9 and pin – point: 3.

5 Patients showed hemiparesis, which persisted in 4 patients post operatively. No major concomitant injuries.

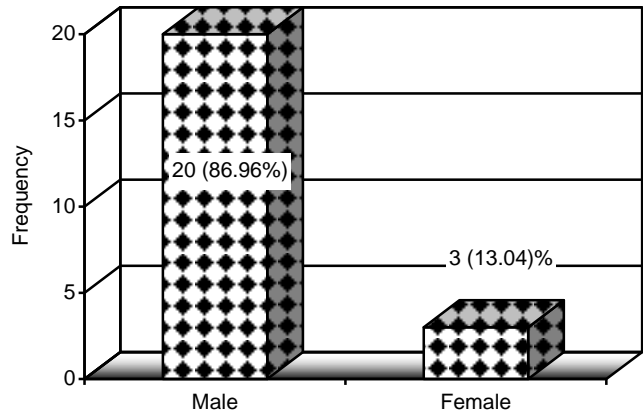


Fig. 2: Gender.

Table 4: Chi-Square Tests.

	Value	df	P-Value
Pearson Chi-Square	21.942 <sup>a</sup>	9	.009
Likelihood Ratio	25.035	9	.003
Linear-by-Linear Association	.803	1	.370
N of Valid Cases	23		

**Outcome:** 13 (56.52%) patients showed moderate to good recovery, 04 (17.39%) patients had severe disability, 02 (8.70%) became vegetative and 04 (17.39%) expired (table 6, Fig. 3).

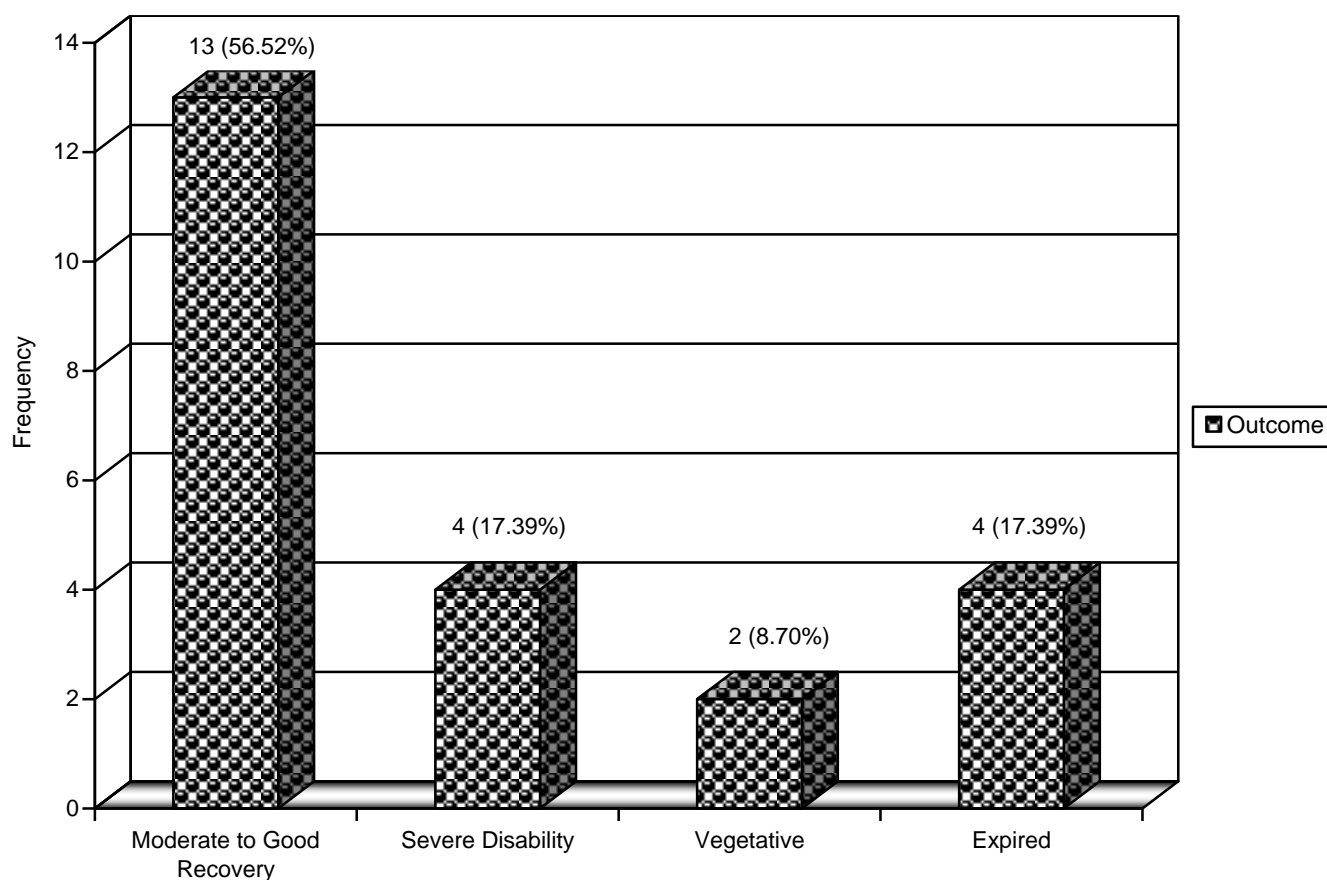
Table 5: Frequency of Gender.

	Frequency	Percent	Cumulative Percent
Male	20	87.0	87.0
Female	3	13.0	100.0
Total	23	100.0	

Better clinical results were obtained in younger patients, and in whom the preoperative neurological

**Table 6:** Outcome.

	Frequency	Valid Percent	Cumulative Percent
Moderate to good recovery	13	59.1	59.1
Severe disability	4	18.2	77.3
Vegetative	2	9.1	86.4
Expired	4	18.2	100.0
Total	23	100.0	



**Fig. 3:** Outcome.

**Table 7:** Descriptive Statistics (Mean GCS).

	N	Minimum	Maximum	Mean	Std. Deviation
GCS	23	5	9	7.65	1.434

status was good (GCS 8 and above); age being the most important prognostic factor. Also the recovery was better when there was not too much delay (undergoing surgery within 9 hours) between the trauma and

the surgery. The 04 patients who didn't survive, they could not recover at all and died during hospital stay. Of the 13 patients who showed moderate to good recovery, all of them still alive. Cranioplasty with

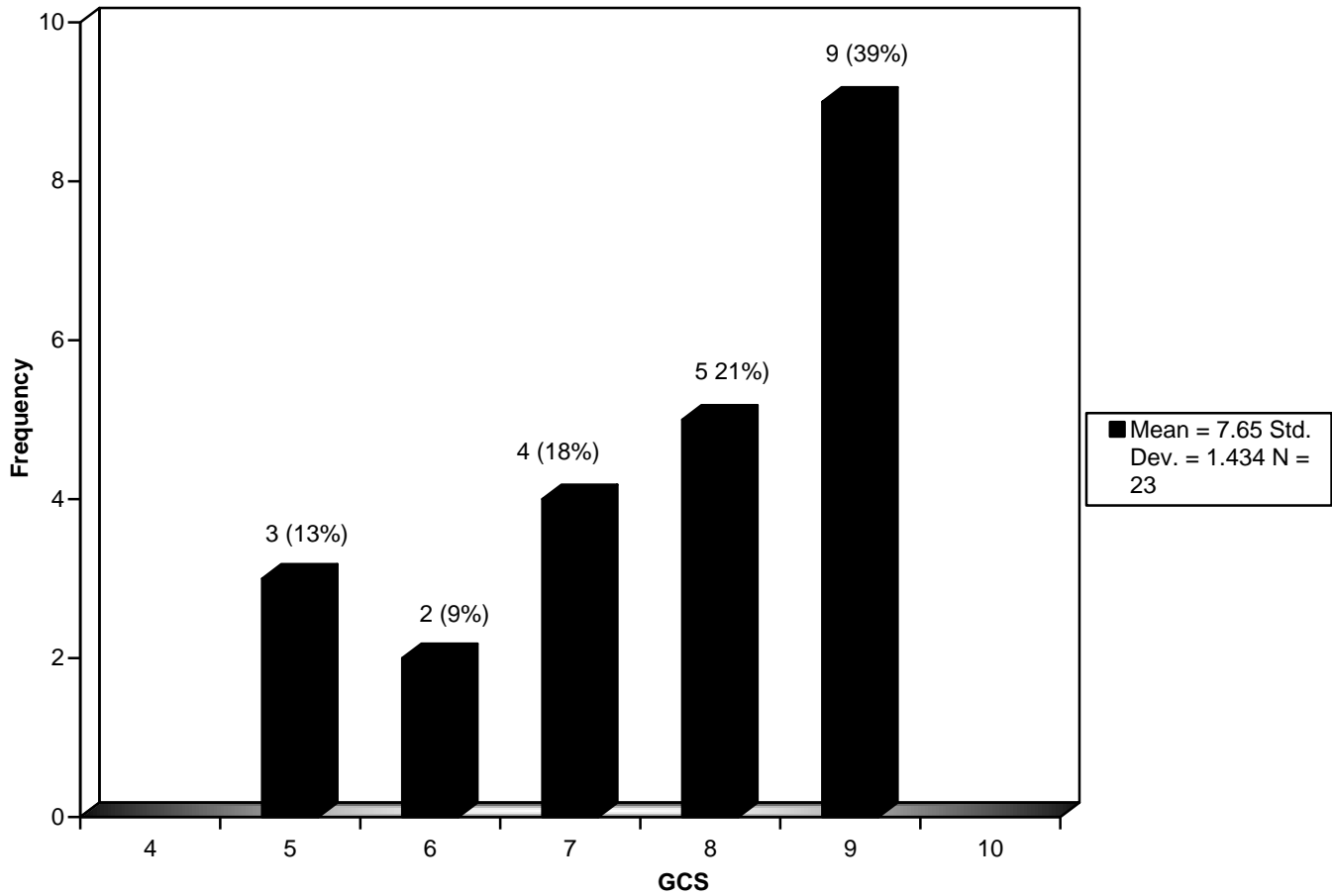


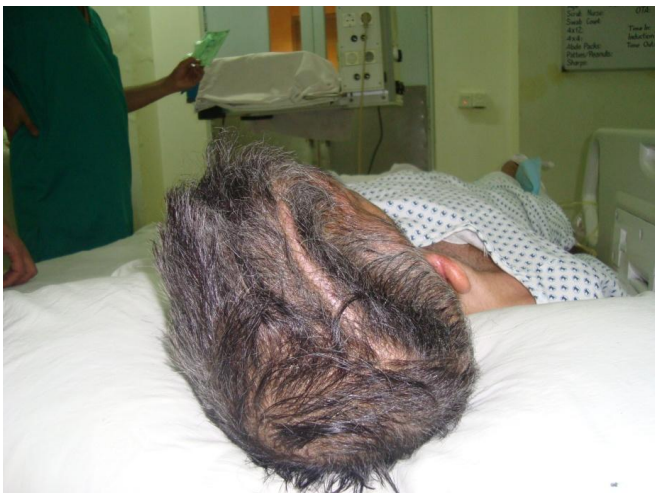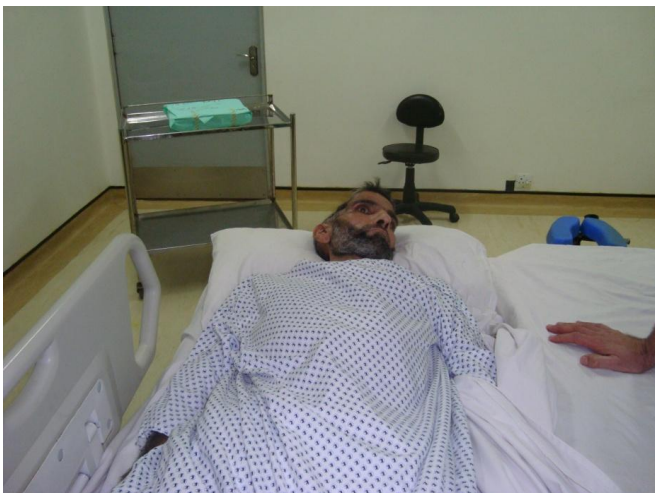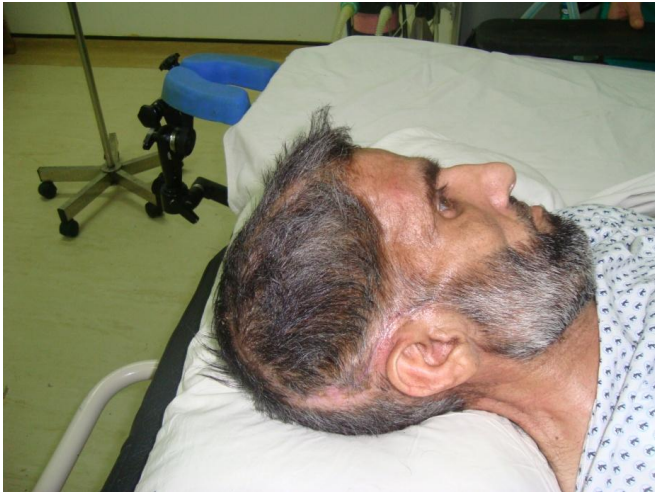Fig. 4:

Table 8: Group of GCS with Gender wise Distribution.

		GCS 5	GCS 6	GCS 7	GCS 8	GCS 9	Total
Gender	Male	3	1	4	4	8	20
	Female	0	1	0	1	1	3
Total		3	2	4	5	9	23

Table 9: Outcome \* Group GCS Cross tabulation.

		GCS 5	GCS 6	GCS 7	GCS 8	GCS 9	Total
Outcome	Moderate to good recovery	0	0	0	4	9	13
	Severe disability	0	0	3	1	0	4
	Vegetative	0	1	1	0	0	2
	Expired	3	1	0	0	0	4
Total		3	2	4	5	9	23



**Fig. 5:** Pictures taken with the permission; a post Decompressive Craniectomy patient ready to undergo bone flap replacement.

replacement of bone flap were performed in all the surviving patients from 06 weeks to 06 months duration the 1<sup>st</sup> surgery, depending on the clinical status.

**Table 10:** Chi-Square Tests.

	Value	df	P Value
<b>Pearson Chi-Square</b>	<b>41.422<sup>a</sup></b>	<b>12</b>	<b>.000</b>
Likelihood Ratio	40.315	12	.000
Linear-by-Linear Association	19.520	1	.000
N of Valid Cases	23		

### Complications

Superficial wound infection was noticed 3 patients, brain herniation through the craniectomy defect occurred in one patient who did not recover at all and later on died. Seizures were recorded in 5 patients and the anticonvulsant medications continued for 3 to 6 months after discharge. Transient cerebrospinal fluid (CSF) leakage through the scalp incision was noticed in one patient and contralateral subdural hygroma developed in one of the vegetative patients later on.

Associated systemic complications noticed were chest infections and DVT one patient each.

### DISCUSSION

There has long been a debate on the role of Decompressive Craniectomy in trauma; some still consider it “optional”. Though theoretically speaking the results are promising as mentioned in the literature, yet some centers faced with a worse clinical outcome despite the decrease in ICP. One small prospective single - centre randomized trial was published in 2001.<sup>12</sup> It showed promising results in favor of decompressive craniectomy. However, the surgical procedure reported (bi-temporal decompression without opening of the dura) is not now regarded as the standard approach. Apart from the technique, timely decompressive craniectomy before the development of irreversible changes in the injured brain would be equally important for patient outcome.<sup>13,14</sup>

As mentioned earlier the European Brain Injury Consortium and Brain Trauma Foundation guidelines for severe TBIs refers to decompressive craniectomy as a second - tier therapy for refractory intracranial hypertension,<sup>2,3</sup> we set our standard protocols after

approval from the ethical committee to perform the procedure as an adjunct to the conventional medical therapy. Both the treatments were considered as a “whole” option, lest the brain should suffer from irreversible damages. Patients admitted were started on medical management and close clinical observation coupled with radiological findings were the diagnostic parameters. No or slow response to medical management alone within 24 hours were the indications of surgery. Some patients were operated upon within a couple of hours due to deterioration of clinical status i.e. drop of GCS +/- 2 degrees or development of anisocoria / hemiparesis. Such patients had minimal acute subdural hematoma too along with the brain edema. All post operative patients were mechanically ventilated for 72 hours post operatively and on weaning off from the ventilation; tracheostomy was carried out for better brain oxygenation in low GCS patients.

The best time to decompress a patient is still under debate in the literature<sup>15</sup> but most authors have suggested an early DC (within 24 hours after injury) for severely head injured patients without brain stem dysfunction.<sup>3,15,16</sup> Our study showed the same as outcome was promising in those who were decompressed earlier. Age of the patient, duration since trauma and GCS on arrival in that order proved to be the most significant factors in relationship with the outcome in our series.

## CONCLUSION

Early Decompressive surgery may perhaps help in reducing many of the complications of conservatively managed patients including longer hospital stay leading to infections and thromboembolism. This procedure favors an early rehabilitation and avoiding psychological problems related with severe trauma.

Our results showed that the functional outcome and quality of life are better than in patients treated with medical management alone. So an early Decompressive Craniectomy should be considered in severe closed head injury. We recommend the strategy of performing early Decompressive Craniectomy followed by cranioplasty combined with state – of – the – art of intensive care management which may reduce not only the mortality but also the morbidity rates associated with very severe head injuries leading to better functional outcomes.

## ACKNOWLEDGMENTS

The authors wish to thank the following for their

valuable contributions in completion of this research;

1. Dr. Muhammad Iqbal Wahid  
Epidemiologist / Executive Officer Research  
College of Physicians and Surgeons Pakistan.  
Research Evaluation unit, Regional Center,  
Peshawar.
2. Dr. Khial Jalal  
Senior Medical officer,  
Department of Neurosurgery, Northwest General  
Hospital and Research Center Peshawar  
Who contributed to patient care and inclusion in  
the study.

### *Address for correspondence*

*Dr. Faiqa Filza Khan  
Associate Prof. Department of Neurosurgery  
Northwest General Hospital and Research centre  
Peshawar – Pakistan  
E-mail: faiqafilza@nwgh.pk*

## REFERENCES

1. Munch E, Horn P, Schurer L, Piegras A, Paul T, Schmiedek P: **Management of severe traumatic brain injury by decompressive craniectomy.** *Neurosurgery* 2000; 47: 315-321.
2. Maas AI, Dearden M, Teasdale GM. *et al.* **EBIC-guidelines for management of severe head injury in adults.** *European Brain Injury Consortium. Acta Neurochir (Wien).* 1997; **139**: 286-294.
3. The Brain Trauma Foundation. **The American Association of Neurological Surgeons. The Joint Section on Neurotrauma and Critical Care. Management and prognosis of severe traumatic brain injury, part 1: Guidelines for the management of severe traumatic brain injury.** *J Neurotrauma.* 2000; **17**: 451-533.
4. Honeybul S, Ho KM, Lind CR, Gillett GR: **Observed versus predicted outcome for decompressive craniectomy: a population based study.** *J Neurotrauma* 2010; 27: 1225-1232.
5. Rosner MJ, Rosner SD, Johnson AH: **Cerebral perfusion pressure: management protocol and clinical results.** *J Neurosurg.* 1995; 83: 949-962.
6. Alexander E, Ball MR, Laster DW. **Subtemporal decompression: radiology observations and current experience.** *Br J Neurosurg.* 1987; 1: 427-433.
7. Kessler LA, Novelli PM, Reigel DH. **Surgical treatment of benign intracranial hypertension-subtemporal decompression revisited.** *Surg Neurol.* 1998; **50**: 73-76.
8. Polin RS, Shaffrey ME, Bogaev CA. *et al.* **Decompressive bifrontal craniectomy in the treatment of**

- refractory posttraumatic cerebral edema. *Neurosurgery*, 1997; **41**: 84-92.
9. Aarabi B, Hesdorffer DC, Ahn ES, *et al.* **Outcome following decompressive craniectomy for malignant swelling due to severe head injury.** *J Neurosurg.* 2006; **104**: 469-479.
  10. Jiang JY, Xu W, Li WP, *et al.* **Efficacy of standard trauma craniectomy for refractory intracranial hypertension with severe traumatic brain injury: a multicenter, prospective, randomized controlled study.** *J Neurotrauma.* 2005; **22**: 623-628.
  11. Piek J. **Decompressive surgery in the treatment of traumatic brain injury.** *Curr Opin Crit Care*, 2000; **17**: 451-533.
  12. Taylor A, Butt W, Rosenfeld J, Shann F, Ditchfield M, Lewis E, Klug G, Wallace D, Henning R, Tibballs J. **A randomized trial of very early decompressive craniectomy in children with traumatic brain injury and sustained intracranial hypertension.** *Childs Nerv Syst.* 2001; **17**: 154-162.
  13. Josan VA, Sogouros S. **Early decompressive craniectomy may be effective in the treatment of refractory intracranial hypertension after traumatic brain injury.** *Child Nerv Syst.* 2006; **22**: 1268-1274.
  14. Dickerman RD, Morgan JT, Mitler MA. **Decompressive craniectomy for traumatic brain injury: when is it too late?** *Child Nerv Syst.* 2005; **21**: 1014-1015.
  15. Li LM, Timofeev I, Czosnyka M, Hutchinson PJ Review article: **the surgical approach to the management of increased intracranial pressure after traumatic brain injury.** *Anesth Analg.* 2010; **111**: 736-748.
  16. Albanese J, Leone M, Alliez JR, Kaya JM, Antonini F, Alliez B, Martin C **Decompressive craniectomy for severe traumatic brain injury: evaluation of the effects at one year.** *Crit Care Med.* 2003; **31**: 2535-2538.

**AUTHORS DATA**

Name	Post	Institution	E-mail
Dr. Faiqa Filza Khan	Associate Professor	Department of Neurosurgery, Northwest General Hospital and Research Centre, Peshawar – Pakistan	faiqafilza@nwgh.pk
Dr. Muhammad Nawaz	Consultant Neurosurgeon		
Dr. Tariq Khan	Senior Consultant Neurosurgeon		