

Outcome of Ventriculo-Atrial Shunt as a Third Option in the Treatment of Hydrocephalus

MUZAMIL DILBER,¹ QAMER RAZA BROHI,² ABDUL RAZAQ MARI¹
Hamid Akbabr Shaikh,¹ Fahmida Arab Mallah,¹ Ali Raza Brohi,³ Shams Raza Brohi¹

*Departments of ^{1,2}Neurosurgery, ³Pediatric Surgery
¹⁻³Peoples University of Medical and Health Sciences, Nawabshah
²Bhittai Medical and Dental College, Mirpur Khas*

ABSTRACT

Objective: The purpose of this study is to describe outcome of ventriculoatrial shunt as a third option in the treatment of hydrocephalus.

Design: Descriptive case series study.

Place and Duration of Study: Neurosurgery department Peoples University of Medical and Health Sciences Nawabshah, from January 2013 to December 2015.

Materials and Methods: This study was conducted on patients who have already attempted for VP shunt and ETV and both have failed. Under radiological guidance distal end of catheter was placed in right atrium at D6 level. Jugular vein was cannulated via common facial vein or direct puncture.

Results: Over a period of 3 years, 24 patients were operated for VA shunt. There were 16 (66.66%) males and 8 (33.33%) females. Male to female ratio was 2:1. Age groups included 2 years to 18 years (mean 9.17 median 8 SD +/- 5.55). Mostly left side was used and common facial venesection was preferred to direct puncture of jugular vein. One patient developed shunt nephritis which was managed with Vancomycin.

Conclusion: VA shunt can be used as third option in the treatment of hydrocephalus taking great care of its complications.

Abbreviations: ETV: Endoscopic Third Ventriculostomy. VCS: Ventriculocisternostomy. CSF: Cerebral Scleral Fluid.

Key words: Hydrocephalus, Neuroendoscopy, shunt, Endoscopic third ventriculostomy (ETV), Ventriculoatrial shunt.

INTRODUCTION

The obstructed cerebral ventricles are usually diverted to the peritoneal cavity by ventriculo-peritoneal shunts or into pre-pontine cistern by endoscopic third ventriculostomy. VP shunt revision may not be possible in patients who developed ascites, pseudocysts or intra-peritoneal adhesions.^{1,2} ETV failure is more common in pediatric group below 2 year age due to imperfect development of subarachnoid space or arachnoid villi; abnormal anatomy at 3rd ventricular floor or closure of stoma.^{3,4} When these patients failed after ETV and VP

shunts, ventriculo-atrial^{5,6,7} shunt is the third option in CSF diversion to right atrium. Ventriculopleural shunt,^{8,9} ventriculosinus shunt,¹⁰ Torkidsen shunt (ventriculocisternostomy VCS)¹¹ or ventriculobiliary shunt¹² are other alternatives.

The ventriculo-atrial shunt is akin to natural egress of CSF into blood stream through arachnoid villi into superior sagittal sinus. In 1895, Gartner floated the idea of physiological diversion of CSF into veins or lymphatics of the head and neck.¹³ Nulsen and Spitz¹⁴ introduced shunt from ventricle into jugular vein. Pud-

enz was the pioneer to suggest right ventricle (ventriculo-auricuostomy) as the suitable site for drainage of CSF and to prevent retrograde flow of blood.¹⁵

It may be adopted as first line of treating hydrocephalus but due to complications like pulmonary hypertension, bactremia, shunt nephritis, breakage and migration of shunt tube, it has been side lined.¹⁶⁻¹⁹ VA Shunt revision is also more difficult than VP shunt revision. To avoid these complications a second look may be given to inspect peritoneal cavity by laparoscopy²⁰ or by using ventriculo-omental bursa shunt²¹ or ventriculo-gall bladder shunt.¹² We have adopted VA shunt as a third option in the treatment protocol for hydrocephalus. The purpose of this study is to observe the clinical and radiological improvement of hydrocephalus; and complications of ventriculoatrial shunts.

MATERIALS AND METHODS

This descriptive case study was conducted in the department of Neurosurgery, Peoples University of Medical & Health Sciences for Women Nawabshah, over a period of 3 years from January 2012 to December 2015. Patients who had failed in the treatment of hydrocephalus with ventriculoperitoneal shunt and endoscopic third ventriculostomy were included in this study. Patients with prothrombotic tendency, infected CSF, cardiac disease, pulmonary hypertension or nephritis were contraindicated for VA shunt and were excluded from this study. Follow up period included 2 to 4 years.

Patients or the attendants were counseled for the procedure and consent taken. Before embarking on VA shunt, patency of internal jugular vein was assessed with Doppler study. Anesthetists were vigilant about smooth rapid sequence induction; and cardiac arrhythmias during atrial catheterization and possibility of venous air embolism. Right or left Keen's point marked. A transverse incision straddling sternocleidomastoid muscle was made. Burr hole was made at Keen's point. The ventricular catheter passed and connected to chamber. Distal catheter was guided into right atrium via common facial vein by venous cut down technique into internal jugular vein under microscope. A tie was used to secure the tube and prevent back flow of blood. Distal end was confirmed by radiographs in the middle or lower right atrium at the level of D₆. In patients failing to cannulate the jugular through common facial vein, direct cut down of the internal jugular vein was made and closed with purse string suture with 6 o stitches. Sometimes guide wire

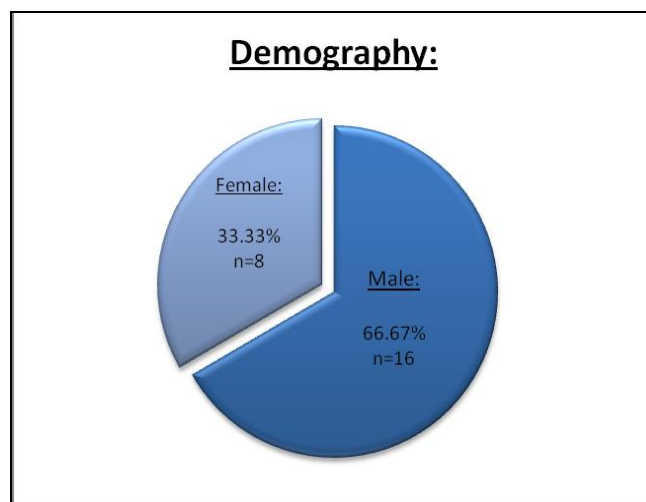
and dilatation and subsequent catheterization was performed. Wounds were closed in layers. Patients were admitted in ward for 2 days and stitches removed on 7th day. Patients were followed for clinical improvement and complications.

RESULTS

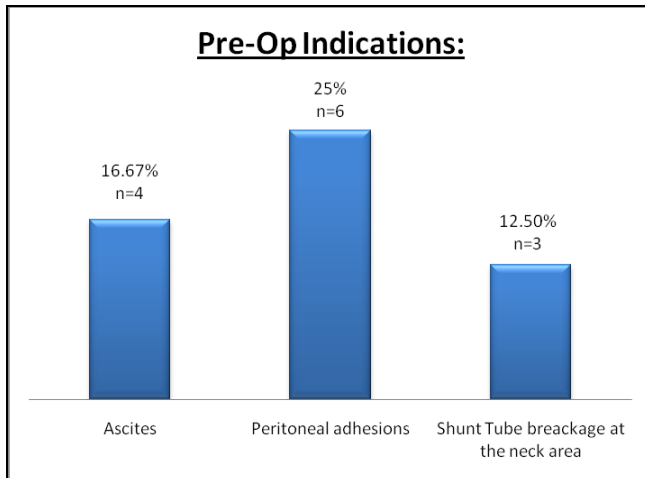
Over a period of 3 years, 24 patients were operated for VA shunt. There were 16 (66.66%) males and 8 (33.33%) females. Male to female ratio was 2:1. Age groups included 2 years to 18 years (mean 9.17 median 8 SD +/- 5.55). Left side was used in 14 (58.33%) patients and right side in 10 (41.67%) patients. All these patients were previously operated for VP shunt and ETV which failed. 4 (16.67%) patients had ascites and 6 (25%) had peritoneal adhesions. Shunt tube breakage at the neck area was observed in 3 (12.5%) patients.

Most of the patients (n = 18) (75%) were cannulated into common facial vein. Direct internal jugular vein cannulation was performed with surrounding purse string sutures in 4 (16.67%) patients. In 1 patient (4.17%) CVP line with guide wire was used for the placement of distal catheter.

Three patients (12.5%) needed shunt revision due to blockage of ventricular catheter or valve. One patient (8.33%) developed shunt nephritis which was managed with Vancomycin and Rifampicin. Follow up period included 3 years. One patient (8.33%) suddenly became cyanosed and died on third postoperative day possibly due to fits and aspiration.



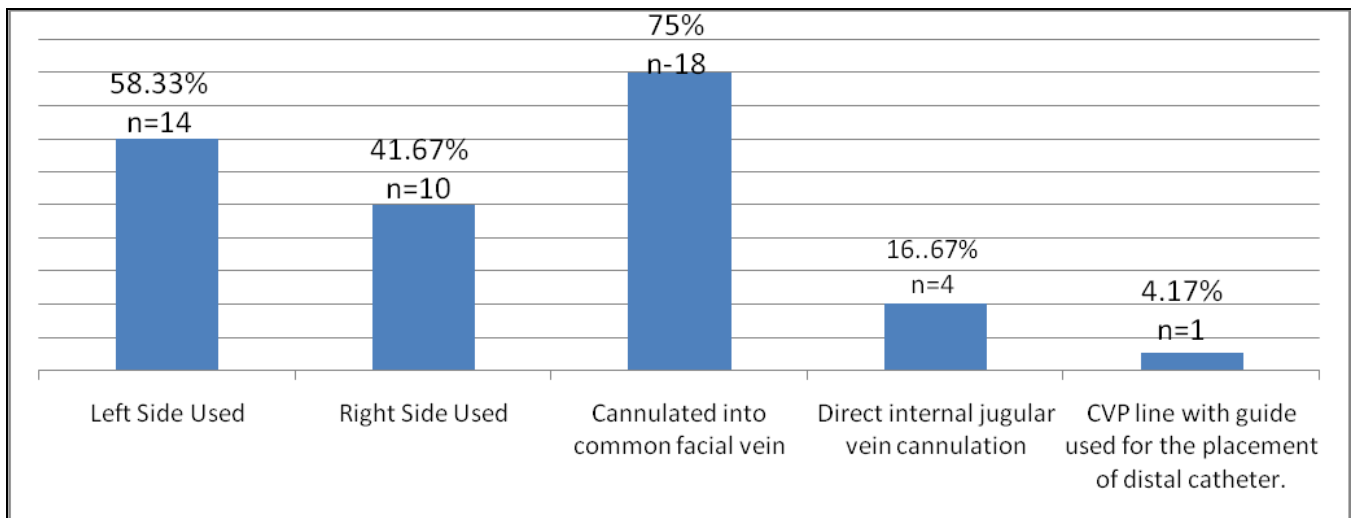
Graph 1: Showing Demographical Pattern.



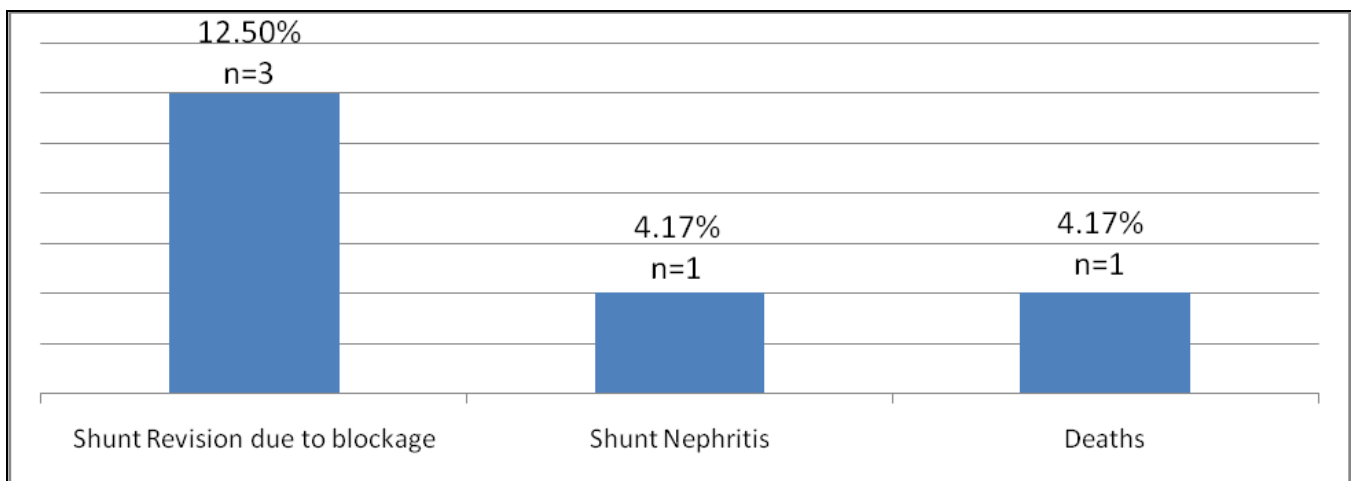
Graph 02: Showing Pre-Op Indications.

DISCUSSION

Out of CSF diversion procedures, VA shunt is less preferable due to its few dreadful complications as compared to VP shunt which has many complications but less life threatening.^{17,22,23,24} In the present scenario ventriculoperitoneal shunt and endoscopic third ventriculostomy are the main procedures in the treatment of hydrocephalus. Ventriculopleural shunt⁸ is less popularized due to the expected complication of hydrothorax which can be prevented with the use of programmable valves and anti-siphon device.⁹ In failed cases of VP shunt, peritoneal cavity may be given second look by laparoscopy; or ventriculo-omental bursa²¹ or ventriculo-gall bladder shunt¹² may be tried. Pudenz¹⁵ was the pioneer to suggest right ventricle



Graph 3: Showing Techniques.



Graph 4: Showing Complications.

(ventriculo-auriculostomy) as the suitable site for drainage of CSF and to prevent retrograde flow of blood. In our series we have used VA shunt as a third choice in those patients who have failed VPS and ETV. We used open method. Mostly we have used left side because right side had scaring or infections during previous operations. We have cannulated jugular vein via common facial by doing venesection under microscope. Many authors have used percutaneous technique by Seldinger method under ultrasound guidance²⁵, fluroscopic²⁶ or transesophageal echocardiography²⁷ for the proper placement of distal end of catheter into right atrium through jugular or subclavian vein. We used to confirm distal catheter with radiographs at the level of D₆.

Pulmonary hypertension, bactremia, shunt nephritis, breakage and migration of shunt tube are complications reported in literature.¹⁶⁻¹⁹ we have few complications like shunt nephritis in 2 patients for which antibiotics were used. 3 patients had proximal shunt block for which shunt revision was performed. There was one death in this study most probably due to fits leading to inhalation.

CONCLUSION

When ETV has failed and peritoneal cavity has been violated by adhesions, infection, pseudo cyst or ascites; VA shunt is preferable third option in the treatment of hydrocephalus. Distal end of VA shunt can be cannulated by open method and confirmed with radiographs. Patients can be followed for the complications and their management.

Address for Correspondence:

Dr. Muzamil Dilber

M.S. Neurosurgery, Senior WMO

*Department of Neurosurgery, Peoples University of
Medical and Health Sciences, Nawabshah*

REFERENCES

- Shannon CN, Acakpo-Satchivi L, Kirby RS, Franklin FA, Wellons JC. Ventriculoperitoneal shunt failure: an institutional review of 2-year survival rates. *Childs Nerv Syst.* 2012; **28**: 2093-99.
- Ali M, Usman M, Khan Z, Khan KM, Hussain R, Khanzada K. Endoscopic third ventriculostomy for obstructive hydrocephalus. *J Coll Physicians Surg Pak* 2013; **23** (5): 338-41.
- Brohi SR, Brohi AR, Siddiqui MA, Mughal SA, Saeed S. Outcome of endoscopic third ventriculostomy in hydrocephalus. *J Surg Pak Jan – Mar 2010*; **15** (1): 25-8.
- Moses ZB, Ozpinar A, Abd-El-Barr MM, Quinonez LG, Emani SM, Goumnerova LC. Direct heart shunt placement for CSF diversion: technical note. *J Neurosurg Pediatr.* 2016 Dec; **25** (6): 663-66.
- Liu A, Sankey EW, Jusué-Torres I, Patel MA, Elder BD, Goodwin CR, et al. Clinical outcomes after ventriculoatrial shunting for idiopathic normal pressure hydrocephalus. *Clin Neurol Neurosurg.* 2016; **143**: 34-8.
- Akhtar N, Khan AZ, Yousaf M. Experience and outcome of ventricular-atrial shunt: a multi centre study. *J Ayub Med Coll Abbottabad,* 2015; **27** (4): 817-20.
- Craven C, Asif H, Farrukh A, Somavilla F, Toma AK, Watkins L. Case series of ventriculopleural shunts in adults: a single-center experience. *J Neurosurg.* 2017; **126** (6): 2010-16.
- Beach C, Manthey DE. Tension hydrothorax due to ventriculopleural shunting. *J Emerg Med.* 1998; **16**: 33-36.
- Oliveira MF, Teixeira MJ, Reis RC, Petitto CE, Gomes Pinto FC. Failed Ventriculoperitoneal Shunt: Is Retrograde Ventriculosinus Shunt a Reliable Option? *World Neurosurg.* 2016; **92**: 445-53.
- Morota N, Ihara S, Araki T. Torkildsen shunt: re-evaluation of the historical procedure. *Childs Nerv Syst.* 2010; **26** (12): 1705-10.
- Rivero – Garvía M, Pancucci G, Morcillo J, Millán A, Márquez – Rivas J. Ventriculobiliary Shunts, Another Option. *Pediatr Neurosurg.* 2015; **50** (3): 152-6.
- Konar SK, Maiti TK, Bir SC, Kalakoti P, Nanda A. Robert H. Pudenz (1911 – 1998) and Ventriculoatrial Shunt: Historical Perspective. *World Neurosurg.* 2015; **84** (5): 1437-40.
- Nulsen FE, Spitz EB. Treatment of hydrocephalus by direct shunt from ventricle to jugular vein. *Surg Forum,* 1951: 399-403.
- Pudenz RH, Russell FE, Hurd AH, Shelden CH. Ventriculo-auriculostomy; a technique for shunting cerebrospinal fluid into the right auricle; preliminary report. *J Neurosurg.* 1957; **14**: 171-79.
- JM, Prakash UB. Development of pulmonary hypertension after placement of a ventriculoatrial shunt. *Mayo Clin Proc.* 1993; **68**: 1177-82.
- Al-Schameri AR, Hamed J, Baltsavias G, Winkler P, Machegger L, Richling B, et al. Ventriculoatrial Shunts in Adults, Incidence of Infection, and Significant Risk Factors: A Single – Center Experience. *World Neurosurg.* 2016; **94**: 345-51.
- Hung CC, Chuang HY, Lin HL, Chu YT, Cheng CH. Intramuscular Migration of Venous Catheter as a Rare Complication of Ventriculoatrial Shunt: Case Report and Literature Review. *J Neurol Surg A Cent Eur Neurosurg.* 2017; **78** (4): 412-16.
- Al-Natour MS, Entezami P, Nazzal MM, Casabianca AB, Assaly R, Riley K, et al. Superior vena cava synd-

- rome with retropharyngeal edema as a complication of ventriculoatrial shunt. *Clin Case Rep.* 2015; **3 (10)**: 777-80.
19. Farach SM, Danielson PD, Chandler NM. Diagnostic laparoscopy for intra-abdominal evaluation and ventriculoperitoneal shunt placement in children: a means to avoid ventriculoatrial shunting. *Laparoendosc Adv Surg Tech A.* 2015; **25 (2)**: 151-4.
 20. Matushita H, Cardeal D, Pinto FC, Plese JP, de Miranda JS. The ventriculoomental bursa shunt. *Childs Nerv Syst.* 2008; **24**: 949-53.
 21. Pasqualin A, Mazza C, Da Pian R. Results of treatment with ventriculoatrial and ventriculoperitoneal shunt in Infantile nontumoral hydrocephalus. *Childs Brain,* 1980; **7**: 1-12.
 22. Clark DJ, Chakraborty A, Roebuck DJ, Thompson DN. Ultrasound guided placement of the distal catheter in paediatric ventriculoatrial shunts – an appraisal of efficacy and complications. *Childs Nerv Syst.* 2016; **32 (7)**: 1219-25.
 23. Hung AL, Vivas-Buitrago T, Adam A, Lu J, Robison J, Elder BD, *et al.* Ventriculoatrial versus ventriculoperitoneal shunt complications in idiopathic normal pressure hydrocephalus. *Clin Neurol Neurosurg.* 2017; **157**: 1-6.
 24. David J. Clark, Aabir Chakraborty, Derek J. Roebuck, Dominic N. P. Thompson. Ultrasound guided placement of the distal catheter in paediatric ventriculoatrial shunts — an appraisal of efficacy and complications. *Childs Nerv Syst.* 2016; **32**: 1219-25.
 25. Limanówka B, Sagan L, Janik S, Rzewuska B, Kojder. Distal ventriculoatrial shunt catheter implantation under fluoroscopy guidance through the left internal jugular vein as a rescue technique - a case report. *Pomeranian J Life Sci.* 2015; **61 (1)**: 48-50.
 26. Dhanyee AS, Singh G, Manayalil BP. Revision of ventriculoatrial Shunt with transesophageal echocardiogram guidance. *J Neurosurg Anesthesiol.* 2015; **27 (4)**: 358-9.

AUTHORS DATA

Name	Post	Institution	E-mail	Role of Authors
Dr. Muzamil Dilber	M.S. (Neurosurgery), Senior WMO	Department of Neurosurgery, Peoples University of Medical and Health Sciences, Nawabshah	shamsbrohi@yahoo.com	Paper Writing
Dr. Abdul Razaq Mari	Assistant Professor			Data Collection
Dr. Hamid Akbabr Shaikh	Assistant Professor			Data Collection
Dr. Fahmida Arab Mallah	M.S. (Neurosurgery), Senior Registrar			Data Analysis
Dr. Ali Raza Brohi	Professor Pediatric Surgery			Proof Reading
Dr. Shams Raza Brohi	Professor Neurosurgery			Overall Supervision
Dr. Qamer Raza Brohi	Assistant Professor Neurosurgery	Bhittai Medical and Dental College, Mirpur Khas		Graphs

Date of Submission: 5-10-2017

Date of Printing: 15-12-2017

Peer Reviewed by Dr. Babar Butt, Nabeel Chaudary, Fauzia Sajjad and Chief Editor Prof. Dr. Muhammad Anwar Chaudary and others.