

Idiopathic Intracranial Hypertension (IIH) – Management with Lumboperitoneal Shunt: A Review of 50 Cases

ASHRAF SHAHEEN, RIZWAN MASOOD BUTT, MANZOOR AHMED

Hafiz Abdul Majid, Nazir Ahmed

*Department of Neurosurgery Unit-I, Lahore General Hospital
Postgraduate Medical Institute, Lahore*

ABSTRACT

Idiopathic intracranial hypertension (IIH) is a syndrome of increased intracranial pressure without causative lesions of Brain on MRI or CT. A 5 year Study from Jan 2004 to December 2008 has been conducted at department of neurosurgery, Lahore general hospital, unit I. A total of 50 patients have undergone lumboperitoneal shunting for IIH., Predominantly patients were females i-e; 41 (82%) patients. Headache was present in all the 50 (100%). Headache associated with visual symptoms was present in 12 (24%). Patient. Patients selection was based upon positive response to lumbar Puncture or lumbar drain. Procedure was done through open method. Postoperative clinical improvement occurred in 46 (92%) patients. Worsening of the symptoms was noted in 1 (2%) patient.

Conclusion: LP Shunt seems to be effective and safe procedure as the definitive measure in the management of IIH.

Key words: Idiopathic intracranial hypertension, benign intracranial hypertension, lumboperitoneal shunt.

INTRODUCTION

Idiopathic intracranial hypertension (IIH) has been formerly known as Benign intracranial hypertension. It is a syndrome of increased intracranial pressure without causative lesions of brain on MRI or CT.^{1,2} The pathogenesis of IIH remains to be clarified. Certain conditions give similar clinical picture. Cerebral venous hypertension is caused by venous sinus thrombosis, neoplastic obstruction or dural arteriovenous malformation. In practice, the diagnosis of IIH is made when venous obstruction and other causes of raised intracranial pressure have been ruled out on neuroimaging.³ An association between IIH and obesity and recent weight gain.^{4,6} Secondary IIH may arise in association with medical conditions such as obstructive sleep apnoea, SLE, renal impairment, and medications as tetracyclines, vitamin A and oral contraceptives. The mechanism of these associations is not clear.^{7,8} Management starts with medical measures failing these surgical methods are employed. Initially, serial lumbar

punctures, diuretics, weight reduction, Carbonic anhydrase inhibitor (Diamox), analgesics, antidepressants and, anticonvulsants are used. Commonly used surgical options include lumboperitoneal shunting and optic nerve sheath decompression.

AIMS AND OBJECTIVES

To ascertain that Lumboperitoneal shunting is safe and effective option in the management of IIH.

PATIENTS AND METHODS

It is a 5 year study from Jan 2004 to December 2008. In total, 50 patients of IIH received LP shunt. All cases were diagnosed by clinical assessment and CT scan. Only those patients were included in the study who showed positive response to lumbar Puncture, or lumbar drain. The procedure was performed under G/A. An open method was used. The insertion of lumbar

portion of One piece catheter in subarachnoid space was done after midline incision, separation of muscles, excision of interspinous ligament with ligamentum flavum in the midline. Intradural insertion was done under direct vision. The catheter was fixed in position with silk suturing to the dura. Flank incision was made 5 cm above and along iliac crest. Once peritoneal is opened, the peritoneal end of the shunt system was inserted and fixed with silk sutures. Satisfactory functioning of the system was observed with egress of CSF through the peritoneal catheter. Wound was closed in layers.

RESULTS

In our study females were 41 (82%) and males patients were 9 (18%) (See Figure 1).

The presenting symptoms included headache and

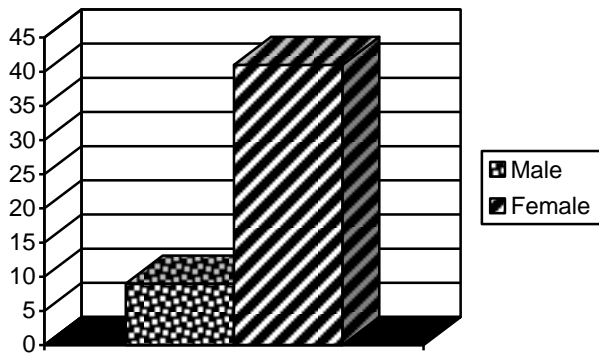


Figure 1: Sex incidence in 50 patients who had Lumboperitoneal shunt.

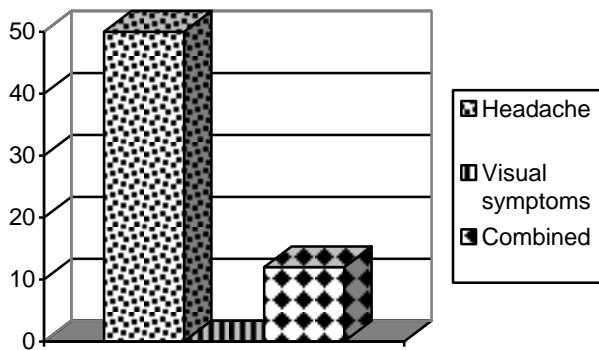


Figure 2: Preoperative clinical features in patients with LP shunting

visual disturbances. Headache was present in all the 50 (100%) patients. Headache associated with visual symptoms was present in 12 (24%) patient. There was no patient having visual symptoms alone.

All patients received lumboperitoneal shunt device. Good clinical improvement occurred in 46 (92%) patients, while 3 (6%) showed some improvement till the time of discharge. Worsening of the symptoms was noted in 1 (2%) patient. This patient improved later on. Findings are depicted in the figure no. 3.

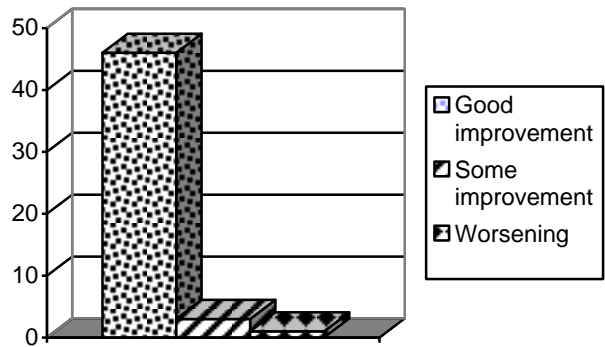


Figure 3: Postoperative improvement after LP shunting.

DISCUSSIONS

The pathogenesis of IIH remains to be clarified. Mainly cerebral venous hypertension is caused by venous sinus thrombosis, neoplastic obstruction or dural arteriovenous malformation are to be blamed. In practice, the diagnosis of IIH is made when venous obstruction and other causes of raised intracranial pressure have been ruled out on neuroimaging.³ An association between IIH and obesity and recent weight gain exists. Secondary IIH occurs in association with obstructive sleep apnoea, systemic lupus erythematosus, renal impairment and with drugs as tetracyclines, vitamin A and oral contraceptives. In many cases, IIH can improve after a single diagnostic and therapeutic lumbar puncture, with modest weight reduction and treatment of associated medical conditions. Serial lumbar punctures, diuretics, Carbonic anhydrase inhibitor (Acetazolamide), analgesics, antidepressants and anticonvulsants all may be employed at some stage. Surgical options are considered when the visual disturbance and severe headache are not controlled by medical measures. Surgical options include lumboperitoneal shunting, ventriculoperitoneal shunting, optic

nerve sheath fenestration. In the past, even bitemporal decompressive craniectomies were tried. The selection of procedure is still controversial and a matter of choice of the clinical team. Lumbo peritoneal shunt (LPS) remains the most widely utilized method. When LP shunting was done the symptoms improved in 82% of patients. LPS is considered, the first surgical procedure for patients with severe visual loss and intractable headache.⁹ The incidence of serious complications is low. The major drawback was frequent revisions. Other complications include, obstruction, infection, tonsillar herniation (acquired Chiari 1 malformation), shunt migration and subdural haematoma. Some patients might be shunt intolerant leading to low pressure symptoms such as headache, head heaviness, vertigo and vomiting may occur and are managed by conservative measures. Lower limb pain due to radiculopathy, superficial wound infection, may also occur.⁹ Overall, LP shunting is a safe procedure. Serious complications are uncommon.^{10,11} In our series the incidence of complications is comparable to previous studies.

CONCLUSION

LP Shunt seems to be effective as the definitive measure in the management of IIIH.

Address for Correspondence:

Dr. Ashraf Shaheen

Department of Neurosurgery Unit-I

Lahore General Hospital,

Postgraduate Medical Institute, Lahore

REFERENCES

1. Digre KB, JJ Corbett Idiopathic intracranial hypertension (pseudotumor cerebri): a reappraisal. *Neurologist*, 2001; 7: 2–67.
2. Friedman DI, Papilledema and pseudotumor cerebri. *Ophthalmol Clin North Am*, 2001; 14: 129–147.
3. Biousse V, Bousser MG.: Benign intracranial hypertension. *Rev Neurol*, 2001; 157: 21–34.
4. Walker RW.: Idiopathic intracranial hypertension: any light on the mechanism of the raised pressure? *J Neurol Neurosurg Psychiatry*, 2001; 71: 1–7.
5. Sussman JD, Sarkies N, Pickard JD. Benign intracranial hypertension. Pseudotumour cerebri: idiopathic intracranial hypertension. *Adv Tech Stand Neurosurg*, 1998; 24: 261–305.
6. Soler D, Cox T, Bullock P, Calver DM, Robinson RO. Diagnosis and management of benign intracranial hypertension. *Arch Dis Child*, 1998; 78: 89–94.
7. Lochead J, Elston JS Doxycycline induced intracranial hypertension. *BMJ*, 2003; 326: 641–642.
8. Lee AG, Golnik K, Kardon R, Wall M, Eggenberger E, Yedavally S.: Sleep apnea and intracranial hypertension in men. *Ophthalmology*, 2002; 109: 482–485.
9. Burgett RA., Purvin VA and Kawasaki A.: Lumboperitoneal shunting for pseudotumor cerebri), *Neurology*. 1997; 49: 734-739.
10. Wang VY, Barbaro NM, Lawton MT, Pitts L, Kunwar S, Parsa AT, Gupta N, McDermott MW. : Complications of lumboperitoneal shunts. *Neurosurgery*. 2007 Jun; 60 (6): 1045-8.
11. Bret J P, Huppert B., Massini, Lapras C. and Fischer G.: Lumbo-peritoneal shunt in non-hydrocephalic patients, A review of 41 cases *Acta Neurochirurgica*. 1986. Volume 80, Numbers 3-4 / September.