

Use of Closed Drainage System for a Period Between 3 To 7 Days, Under Antibiotic Cover is Safe in Chronic Subdural Hematoma Treatment

RIZWAN MASOOD BUTT, MANZOOR AHMAD, ASHRAF SHAHEEN

Shahzad Shams, Waqas Hashmi

Department of Neurosurgery, Services Hospital, Lahore

ABSTRACT

Chronic subdural hematoma is a common neurosurgical problem in the elderly. There has been interest in the use of closed system drainage after initial irrigation. This may lead to infection. The objective of our study was to assess the risk of infection with the use of drain over a period of 7 days. In 27 patients closed system drainage was used. It was removed whenever drainage became less than 25 ml/24 hours. The upper limit for keeping the drain was 7 days. None of the patients required the drain for more than 7 days. The risk of meningitis was assessed. There was no patient who developed local wound infection or meningitis.

Conclusion: *It is safe to use closed drainage system for continued drainage of chronic subdural hematoma under antibiotic cover for 7 days.*

Key words: *Chronic subdural hematoma, burr hole irrigation, continuous drainage.*

INTRODUCTION

In contemporary neurosurgery, three principal techniques are used for draining chronic subdural hematoma; twist drill craniostomy, burr hole craniostomy, and craniotomy.¹ Twist drill and burr hole craniostomy are the first tier treatment.¹ Treatment through a burr hole, irrigation and closed system drainage under local anesthesia is simple, safe and effective.² But due to drainage catheter, the risk of infection is increased. In our study we wanted to establish whether use of drain between 3-7 days in subdural space under antibiotic cover is safe in regards to infection.

PATEINTS AND METHODS

In the patients with chronic subdural hematoma (CSH) requiring surgery, 1 or 2 burr holes were made according to the size and location of hematoma. Injection co-amoxiclav was used as a single drug. It was given prior to surgery and then for the duration the drain was kept in. Local head shaving was done just before the

incision was given. Area was cleaned with povidone iodine. For drainage system, we used feeding tube number 8 – 12, depending upon apparent density of hematoma on gross observation. In cases thick fluid came out, wide bore (No. 12) tube was used. The feeding tube was connected with drainage bag and the connection was sealed with aseptic technique. The drain was used till 24 hours passed with minimal fluid drained out. Minimal duration the drain was used was 3 days. In some cases drain was used uptill 1 week. Once the fluid drainage rate was less than 25 ml/24 hours, it was removed.

The hemorrhage site was mostly unilateral. In recurrent cases, extended maintenance of a drainage catheter increases the possibility of infection and tension pneumocephalus.³ Intraoperatively, the head of the patient is placed at the same height as his or her heart, and enough intravenous fluid infused to accomplish the temporary swelling of the brain, which resulted in the rapid obliteration of the subdural space.³ Prolonged duration of drainage does not increase the

frequency of infection. Usually 3 days of drainage is necessary, for outer membrane of CSH to restore a balance between coagulation and fibrinolysis, which terminates vicious cycle and resolves the hematoma.⁴

RESULTS

Among 27 patients there were 24 males and 3 females.

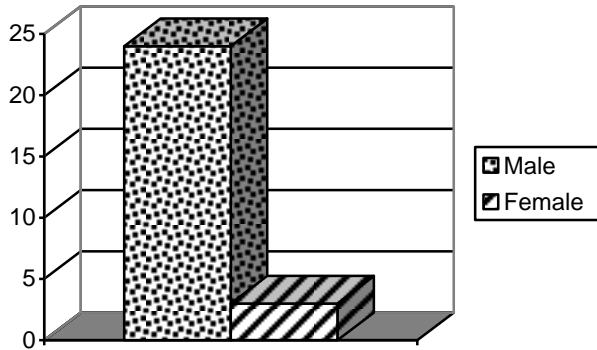


Fig. 1: Sex distribution among 27 patients with chronic subdural haematoma.

Age range was 3 weeks till 75 years of age. Both adult and paediatric patients were included. Age distribution was as; one patient was less than 1 year, 1 between 1 to 10 years, 3 patients between 41 to 50 years, 9 between 51 to 60 years, 11 between 61 – 70 years, and 3 between 71 – 80 years (Figure 2). Demographically, patients came from different cities of Punjab and Khyber Pakhtoon khawah and it is not possible to ascertain catchment area.

The drain was fixed with scalp stay silk sutures and polyfax ointment was applied. Turban dressing

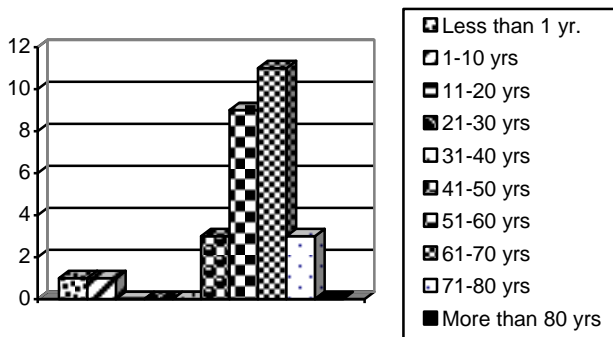


Fig. 2: Incidence according to age among 27 patients.

was applied at the end. Dressing was changed after 24 hours and then on alternate days till day 7 when drain was removed (Figure 3). Sutures were removed on day 9.

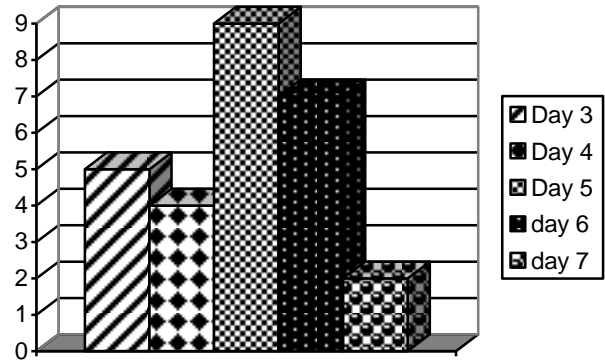


Fig. 3: Day of removal of the drainage tube.

Hospital stay ranged from 8 days to 3 weeks. There were 6 patients who were discharged between 3 to 7 days of surgery, 5 stayed between 8 to 14 days, 9 were discharged between 15 to 21 days, 6 were discharged between 22 to 30 days and 1 patient stayed for more than 30 days postoperatively (Figure 4). Follow up was done for 3 months for any evidence of local wound infection, meningitis or recurrence.

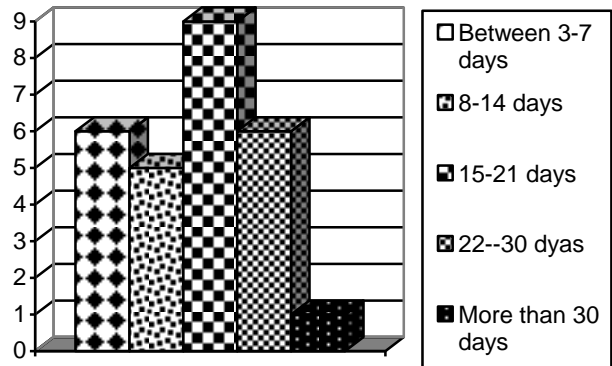


Fig. 4: Days of discharge after surgery.

DISCUSSION

A common problem with chronic subdural hematoma evacuation is recurrence of collection even after observed clinically complete evacuation at the first attempt of drainage. To circumvent this problem,

closed drainage system may be used. For any intracranial drain, there is a risk of infection. In our setup we are always afraid of infection. The rules of antisepsis are sometimes ignored by paramedical staff, so we ask doctors only to manipulate intracranial drains. These are not left to be fiddled by paramedical staff. Incidence of chronic subdural hematoma (CSH) is 1/100,000 cases in subjects > 70 years old (average age: 72 years). There is history of trauma in all cases. The average time between injury and onset of symptoms is 6 weeks.² Male to female ratio is 5:1 and all of the patients were in their sixties or older.³ In females, lesser exposure to trauma and estrogen's defensive effect on the blood vessels is said to be the reason of this lesser incidence. The higher incidence among the aged is said to be due to antithrombotic usage, venous fragility and augmentation of the subdural space (6~11% of the whole intracranial space).³ Review of literature shows that different centers have compared various techniques for the drainage of chronic subdural hematoma. A difference of opinion has been found, as some centers claim that drainage is better, some claim that irrigation and catheter placement is superior while others conclude that both are of equal value. One of the studies showed that leaving in the drain (drainage group) is better as postoperative hospitalization was shorter and recurrence was less frequent.⁵

Other studies showed that both groups are equal as there was no significant difference between recurrence rates although drainage method is simpler.⁶⁻⁹ Another study showed that the technique of two burr holes combined with a subperiosteal passive closed-drainage system is a technically easy, highly effective, safe, and cost-effective method of treatment.¹⁰

COMPLICATIONS

The overall complication rate is 10.9%. The complications include recurrence, seizures, intracerebral hemorrhage, infection, tension pneumocephalus, and cerebral infarction.¹⁰ Recurrence of chronic subdural hematoma ranges between 2.3% to 13%.^{3,4,10} The patients were discharged from hospital about 2 weeks after surgery, reappearance of the symptoms occurred within 1 to 44 days (14.6 days on average) and surgical complications (20.5%) were encountered in 20.5% patients.^{3,11} The most frequent minor complication was *seizures* (6.6% to 13.6%), superficial and deep wound infection (1.6%).^{10,11} The most frequent major surgical complications were *intracerebral hemorrhage and subdural empyema* (2.1% each).¹¹

The drain in direct contact with the hematoma capsule increases the risk of postoperative seizures and spread of infection to intracranial compartments. Microorganisms like *Klebsiella pneumoniae* may directly infect the subdural space with iatrogenic contamination. It is treated by intravenous meropenem for 6 weeks.¹⁰ Medical complications occur in 15.7% patients.¹¹

Tension Pneumocephalus has also been reported after evacuation of chronic subdural hematoma.¹² *Cerebral infarction* has been said to occur because of the intracranial hypotension during the drainage. It can be circumvented by replacement with Hartmann's solution, and closed-system drainage.¹³

PROGNOSIS

Overall, the postoperative outcome of chronic subdural hematoma has not improved substantially over the past 20 years.¹ Generally, patients have good prognosis³ except in cases with bilateral hematomas.¹¹ More than 80% of patients recover completely, 10% may have neurological or mental deficits and 7% suffer from epilepsy.¹³ Surgical mortality rate is reported to be 1.1%- 3.4%.^{9,15}

CONCLUSION

It is safe to use close drainage system for continued drainage of chronic subdural hematoma under antibiotic cover for 7 days.

Address for Correspondence:

*Dr. Rizwan Masood Butt
Department of Neurosurgery
Services Hospital, Lahore
Cell: 0333-4232040*

REFERENCES

1. Weigel R, Schmiedek P, Krauss J K. Outcome of contemporary surgery for chronic subdural hematoma: evidence based review. *J Neurol Neurosurg Psychiatry* 2003; 74 (7): 937-43.
2. Mauro Soto-Granados. Treatment of chronic subdural hematoma through a burr hole. *Cir.* 2010; 78: 203-7.
3. Koivisto T, Jääskeläinen JE. Chronic subdural haematoma--to drain or not to drain? *Lancet.* 2009 Sep 26; 374 (9695): 1040-1.
4. GJ Yu, CZ Han, M Zhang, HT Zhuang, YG Jiang, Prolonged drainage reduces the recurrence of chronic sub-

- dural hematoma. *Br J Neurosurg.* 2009 Dec; 23 (6): 606-11.
5. Han HJ, Park CW, Kim EY, Yoo CJ, Kim YB, Kim WK. One vs. Two Burr Hole Craniostomy in Surgical Treatment of Chronic Subdural Hematoma. *J Korean Neurosurg Soc.* 2009 Aug; 46 (2): 87-92.
 6. Gurelik M, Aslan A, Gurelik B, Ozum U, Karadag AÖ, Kars HZ. A safe and effective method for treatment of chronic subdural hematoma: The Canadian Journal of Neurological Sciences 2007; 34 (1): 84-7.
 7. Erol FS, Topsakal C, Ozveren MF, Kaplan M, Tiftikci MT. Irrigation vs. closed drainage in the treatment of chronic subdural hematoma. *Journal of Clinical Neuroscience* 2005; 12 (3): 261-3.
 8. Smely C., Madlgr A and Scheremet R. Chronic subdural hematoma- a comparison of two different treatment modalities. *Acta Neurochir (Wein)* 1997; 139: 818-26.
 9. Zumofen D, RegliL, Levivier M, Krayenbühl N. Chronic subdural hematomas treated by burr hole trepanation and a subperiosteal drainage system. *Neurosurgery* 2009; 64 (6): 1116-21.
 10. Engelhard III HH, Sinson GP, Reiter GT, Rohde V, Graf G and Hassler W. Complications of burr-hole craniostomy and closed-system drainage for chronic subdural hematomas: a retrospective analysis of 376 patients *Neurosurgical Review Springer Berlin / Heidelberg* 2002; 25 (1-2).
 11. Shaikh N, Masood I, Hanssens Y, Louon A, Hafiz A. Tension pneumocephalus as complication of burr-hole drainage of chronic subdural hematoma: A case report. *Surg Neurol Int* 2010; 1: 27.
 12. Aung TH, Wong WK, Mo HP, Tsang CS. Management of chronic subdural hematoma: burr hole drainage, replacement with Hartmann's solution and closed-system drainage *HKMJ* 1999; 5 (4): 383-6.
 13. Kotwicaa, Brzeziskia Z J. Chronic subdural hematoma treated by burr holes and closed system drainage: Personal experience in 131 patients. *British Journal of Neurosurgery* 1991; 5 (5): 461-5.
 14. Robinson RG. Chronic subdural hematoma: surgical management in 133 patients. *Journal of neurosurgery* 1984; 61 (2): 263.