

Craniovertebral Junctional Injuries and Management

FAUZIA SAJJAD, KHALID MEHMOOD, MUHAMMAD ANWAR CHAUDHRY

Zafar Iqbal, Nauman Shakeel, Tariq Salahuddin

Department of Neurosurgery Unit II, Lahore General Hospital, Lahore

ABSTRACT

Objective: *Craniovertebral junction injuries are less common. They are unique in their presentation and need specialized management. The objective was to determine diagnosis initial management and ultimate surgical procedures performed and efficacy of these procedures.*

Materials and Methods: *A five year study from April 2003 to Oct. 2008 was conducted at department of neurosurgery unit II Lahore general hospital Lahore. A total of fifteen patients were included. All patients with upper cervical trauma with all modes of injuries were included irrespective of their age and sex. All patients were evaluated with routine X-rays cervical spine, anteroposterior, lateral and open mouth views. While dynamic views were advised only in those having osodontoideum. C.T with saggital reconstruction and MRI were performed in all patients to further augment and detect bony and soft tissue details. In all modes of injuries we maintain their airway breathing and circulation.*

Clinical Presentation: *Out of total fifteen patients mostly were young in their twenties and thirtees, only two patients (13.33%) were below twenty and one patient (6.66%) was above fourty years. The main culprit was road traffic accident in most of patients (thirteen patients 80%) followed by fall in two patients (13.33%) and assault in one patient (6.66%). The odontoid fracture with reductable atlantoaxial instability was appeared to the most common problem in five patients (33.33%). In two patients (13.33%) transverse ligament found to be intact. In two other cases (13.33%) atlas fracture was simultaneously found. Osodontoideum detected in two patients (13.33%) while basilar invagination seen in one patient (6.66%). Irreducible atlantoaxial instability was seen in three patients (20%). Out of fifteen patients, three patients (20%) were neurologically intact, while one patient (6.66%) had complete injury. Eleven patients (73%) had partial injury.*

Surgical Procedures: *In order to achieve stability, we performed posterior instrumentation and bony fusion in all nine reducible injury patients (60%). Atlanto axial fusion performed in seven patients (46.66%), while in two patients (13.33%) having concomitant C₁ injury occipitocervical fusion was done. Initial transoral decompression, prior to posterior fusion was done in all four (26.66%) non reducible injury patients. Transodontoid screw fixation was done in two patients (13.33%) having intact transverse ligament.*

Outcome: *Overall 07 (46.66%) cases revealed excellent results all recovered without any complication. Four (26.66%) cases had some complication but recovered within 02 weeks and result was labeled as good. Two cases who had neurological deterioration, recovered slowly within 03 months. Recovery was labeled as fair. One patient who suffered neurological deterioration did not recovered and result was labeled as poor.*

Complications: *One patient (6.66%) died after severe chest infection, although severe chest infection observed in three patients (20%). Mild wound infection and wound dehiscence seen in one patient (6.66%) each. These patients managed conservatively successfully. Neurological deterioration observed in three patients (20%), out of them two patients (13.66%) improved with 3 months.*

INTRODUCTION

Spinal cord trauma is the most unfavourable thing happening in an individual. Craniovertebral junctional injuries are rare but not uncommon, constituting 25% of all cervical spinal trauma. The craniovertebral junction is the most complex and dynamic region of cervical spine. The unique anatomy, articulations, physiological ranges of motion and rotation make this area more vulnerable to trauma.¹

Craniovertebral junction includes bony articulations between two occipital condyles, C₁ and C₂, and the complex ligamentous system linking these three bones into one functional joint. There are two separate groups of ligaments, among them the transverse ligament or the horizontal part of cruciate ligament is of utmost importance for stability.² The principal structural ligaments bypass the atlas, extending from the bony elements of the basion at the skull base to the odontoid process of C₂. Ligamentous injuries alone may have fatal sequelae if remained undetected. Besides osseoligamentous injuries, neurovascular damage usually accompanied the trauma.

The primary imaging modalities used for evaluation of the craniovertebral junction (CVJ) include plain radiography, computed tomography (CT), and magnetic resonance imaging (MRI). Plain radiographs include anteroposterior and lateral views of the cervical spine, while open mouth views reserved for evaluation of the atlantoaxial and atlanto-occipital articulations. Recently the advent of multidetector computed tomography (MDCT), by using various craniometric lines and angles, is of great value for detection of craniovertebral junction injuries. Dynamic views can be obtained in suspected clinical instability cases. No doubt both Computed tomography and MRI have complementary roles, for better insight into the normal anatomy and pathology of this complex area.^{3,4}

Timely injury recognition and determination of stability, is of utmost importance for proper management. Immobilization and reduction are the initial steps of treatment. Reduction usually achieved with cranial skeletal traction in the emergency room using fluoroscopy.⁵ Traction is absolutely contraindicated in distraction injuries, where early application of halo or postural reduction are helpful. Sometimes vasopressor support and intravenous methylprednisolone are indicated, although the role of steroids in the treatment of acute spinal cord injuries is controversial.²

Definitive surgical intervention is indicative in patients with dislocations and distractive upper

cervical spine. Presence of a spinal cord injury is indicative of possible decompression and surgical stabilization, to maximize the chance for neurologic recovery. Selection of anterior or posterior approach is dependent on reducibility.^{6,7}

Non operative treatment options consist of skeletal traction, bracing, and halo immobilization.^{1,2}

MATERIALS AND METHODS

A five year study from April 2003 to Oct. 2008 was conducted at department of neurosurgery unit II Lahore general hospital Lahore. A total of fifteen patients were included. All patients with upper cervical trauma with all modes of injuries were included irrespective of their age and sex. All patients were evaluated with routine X-rays cervical spine, anteroposterior, lateral and open mouth views. While dynamic views were advised only in those having osodontoideum. C.T with sagittal reconstruction and MRI were performed in all patients to further augment and detect bony and soft tissue details. In all modes of injuries we maintain their airway breathing and circulation. We put our patients on analgesics and steroids if needed. We immobilized cervical spine with crutchfield cervical traction. The main idea was to see whether instability is reducible or not. Initially applied ten pounds and gradually increase the weight day by day up till twenty pounds. Many patients even reduced on seventh or eighth day. Finally we performed different surgical procedures to achieve stabilization.

RESULTS

Age Incidence

Out of total fifteen patients mostly were young in their twenties and thirties, only two patients (13.33%) were below twenty and one patient (6.66%) was above forty years 7 patients were between 20 – 30 years and 5 were 30 – 40 years of age (Graph 1).

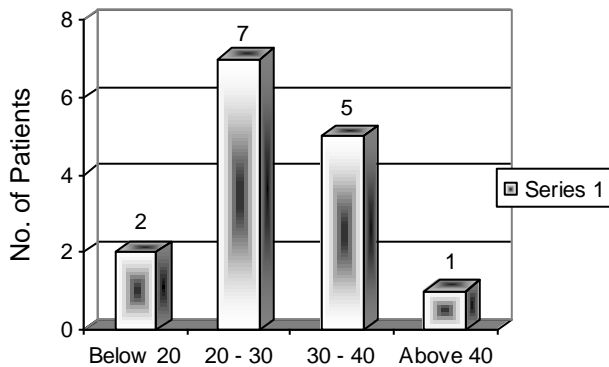
Sex Incidence

Males were predominantly involved. Thirteen patients (87%) were males and only two patients (13%) were female (Graph 2).

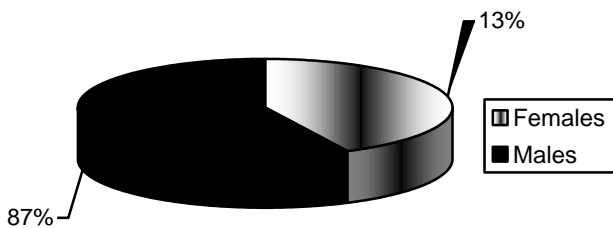
Mode of Injury

The main culprit was road traffic accident in most of patients (thirteen patients 80%) followed by fall in two

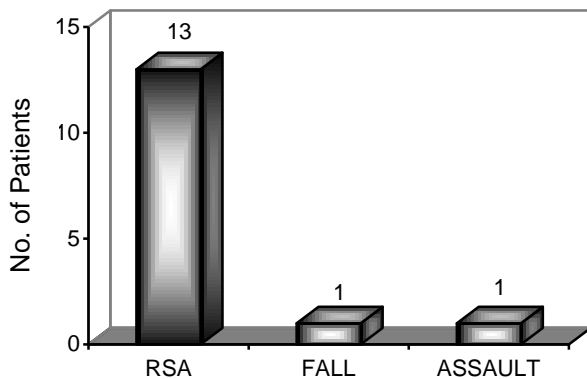
patients (13.33%) and assault in one patient (6.66%) (Graph 3).



Graph 1: Age Incidence.



Graph 2: Sex Incidence.



Graph 3: Etiology.

Type of Injury

The odontoid fracture with reducible atlantoaxial instability was appeared to be the most common

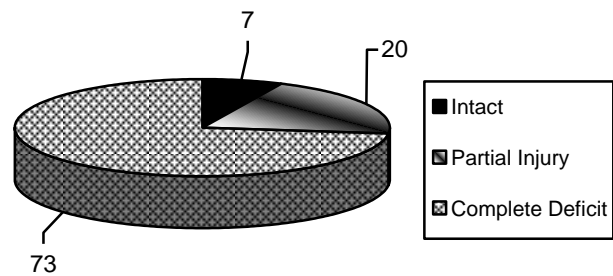
problem in five patients (33.33%). In two patients (13.33%) transverse ligament found to be intact. In two other cases (13.33%) atlas fracture was simultaneously found. Osodontoideum detected in two patients (13.33%) while basilar invagination seen in one patient (6.66%). Irreducible atlantoaxial instability was seen in three patients (20%) (Table 1).

Table 1: Type of Injury.

S. No.	Type of Injury	No.
1.	Odontoid # Type II	9
	- Intact Transverse Ligament	2
	- Reduceable Atlanto Axial Instability (AAI)	5
	- # Atlas and Odontoid # Type II	2
2.	OS Odontoideum	2
3.	Basilar Invagination	1
4.	Irreducible Atlanto Axial Instability (AAI)	3
	Total	15

Clinical Presentation

Out of fifteen patients, three patients (20%) were neurologically intact, while one patient (6.66%) had complete injury. Eleven patients (73%) had partial injury (Graph 4).



Graph 4:

Surgical Procedures

In order to achieve stability, we performed posterior instrumentation and bony fusion in all nine reducible injury patients (60%). Atlanto axial fusion performed in seven patients (46.66%), while in two patients

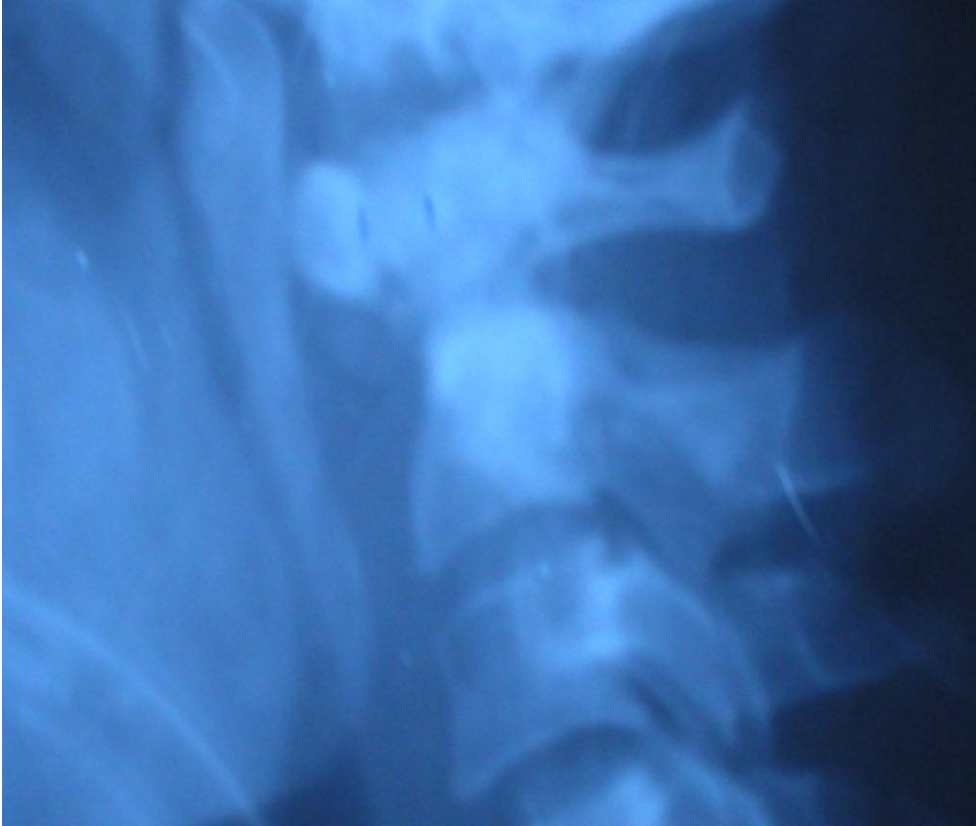

Fig. 1: *Fracture Odontoid
Preoperative X-ray.*

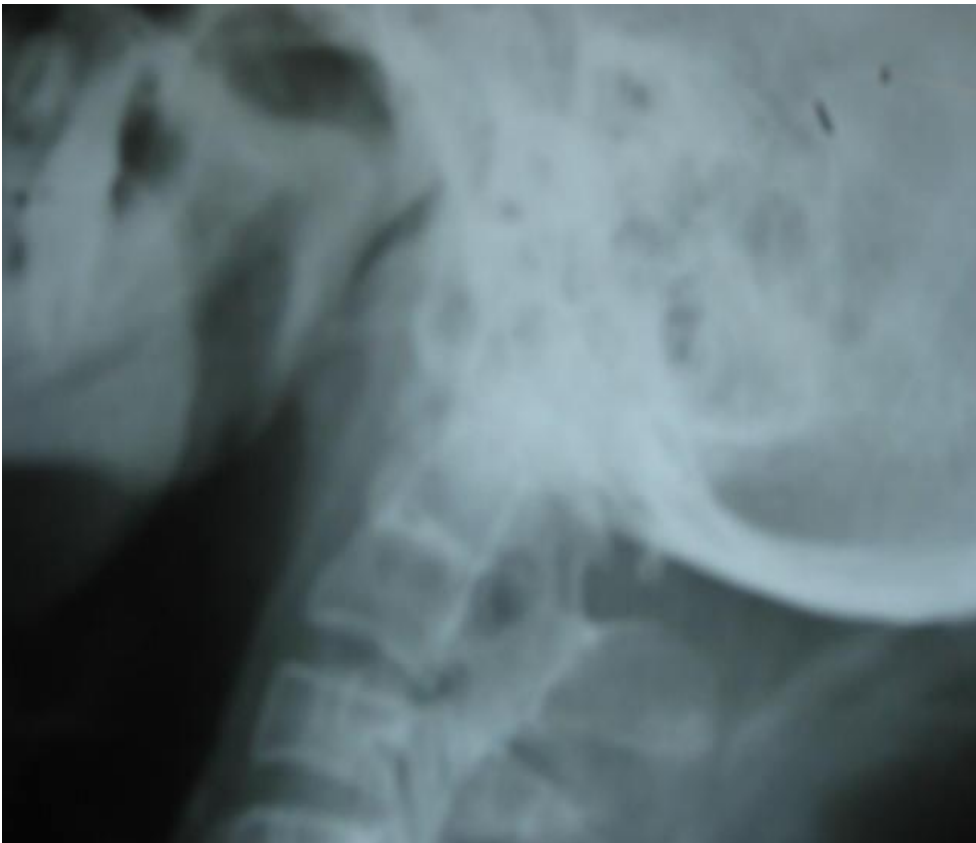

Fig. 2a: *Basilar
Invagination Preoperative
X-ray.*

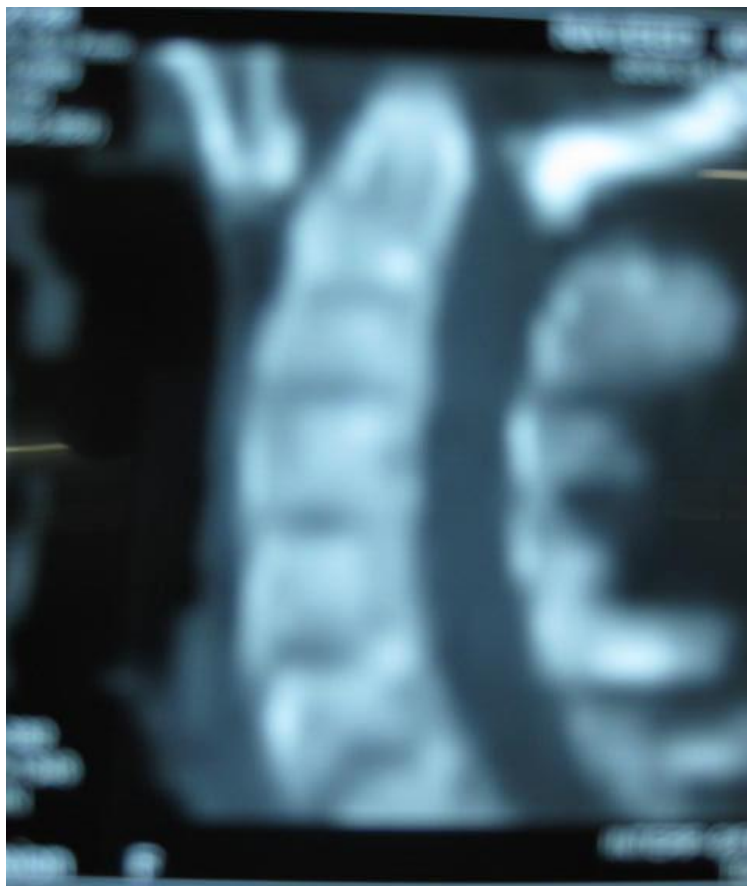


Fig. 2b: *Basilar Invagination
Preoperative CT Scan
Craniocervical Junction.*

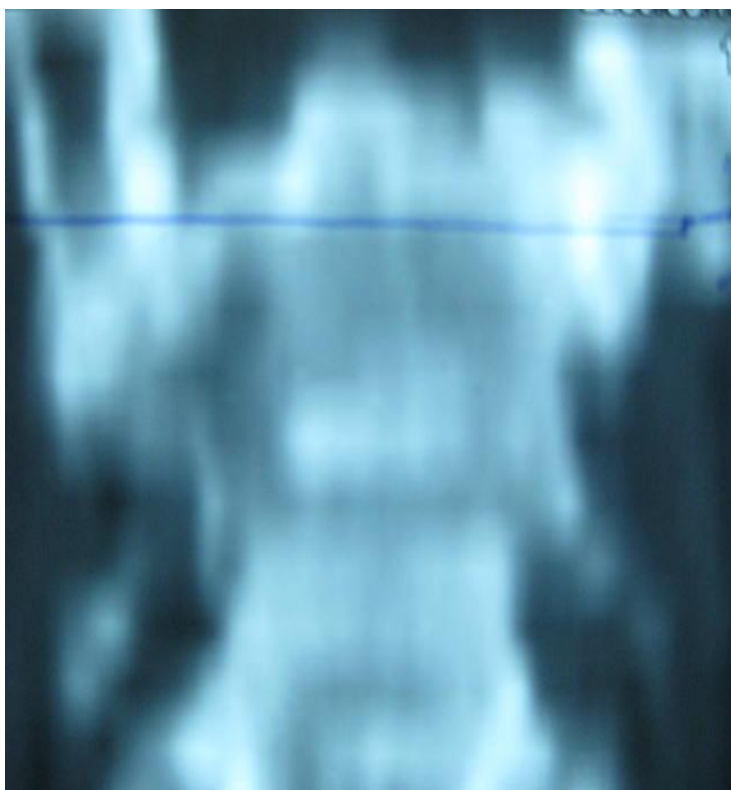


Fig. 2c: *Basilar Invagination CT
Scan Craniocervical junction
Preoperative.*

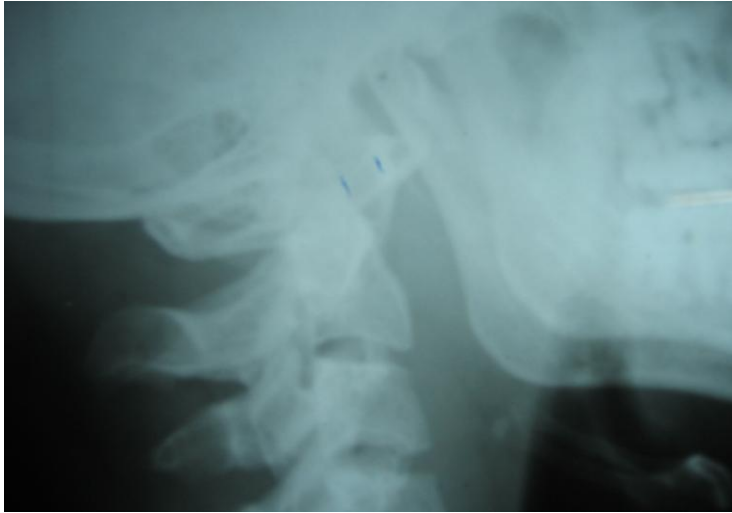

Fig. 3a:

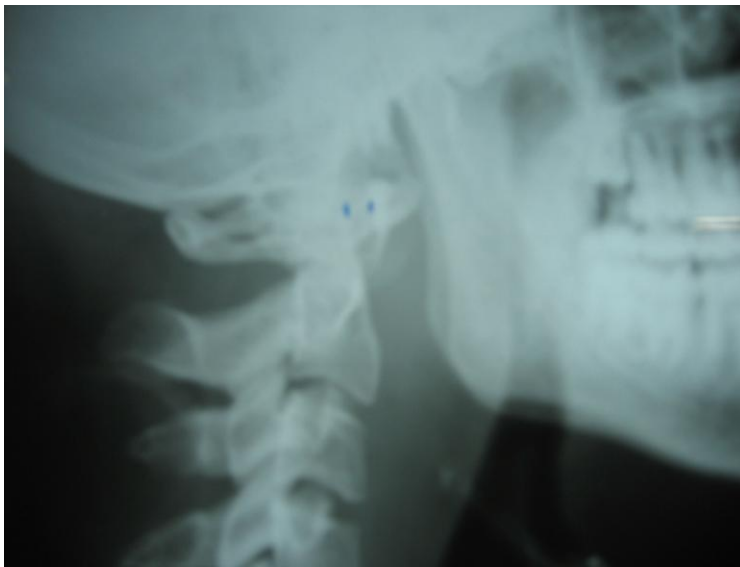

Fig. 3b:

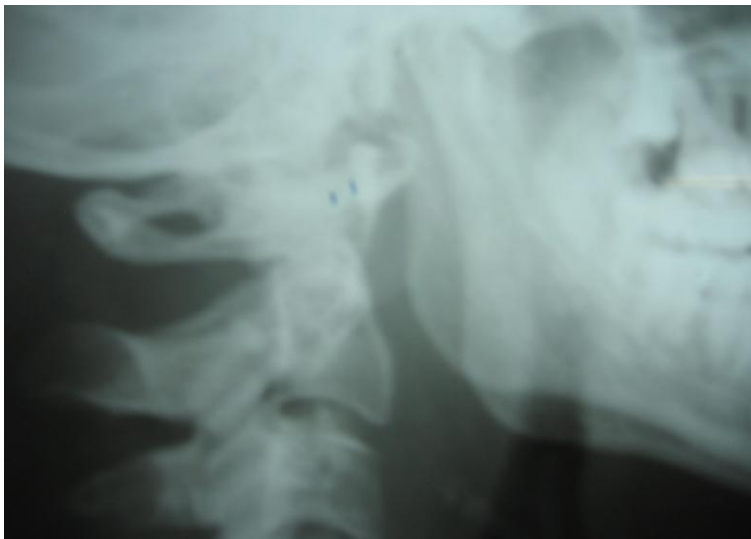


Fig. 3c:

Fig. 3a,b,c:
*Comparison of Reduction by
Crutchfield Cervical Traction.*

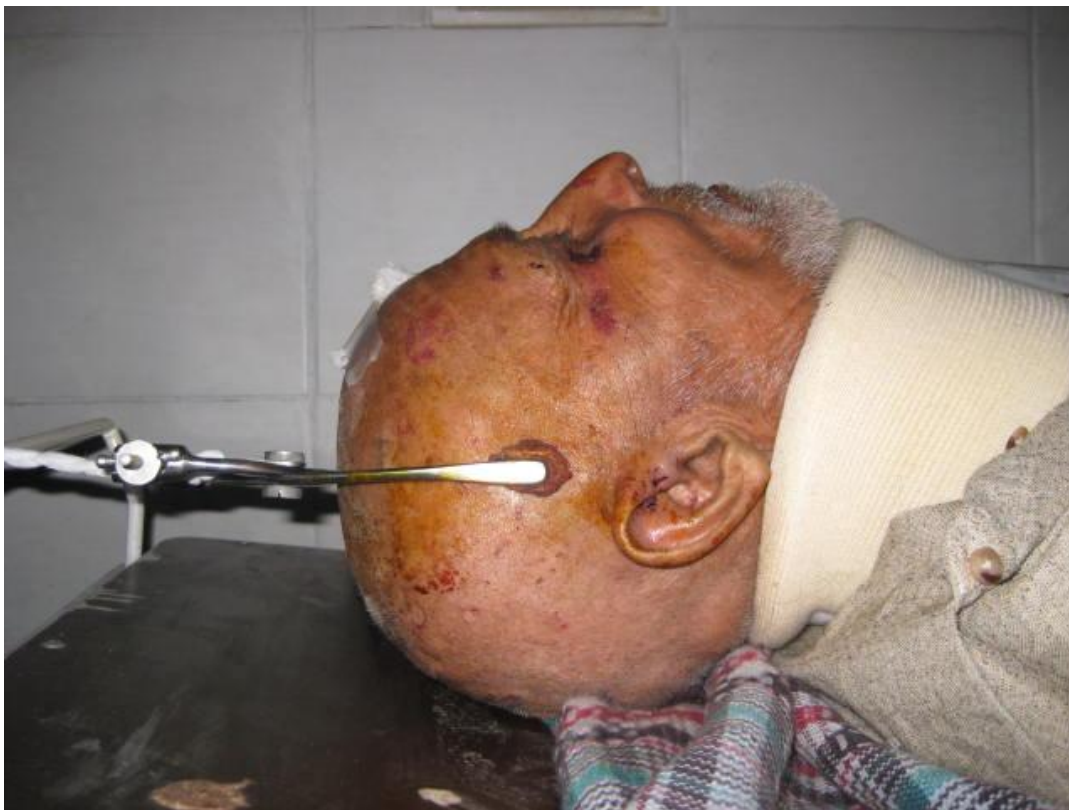

Fig. 4: *Crutchfield Cervical Traction for Reduction of Dislocation.*

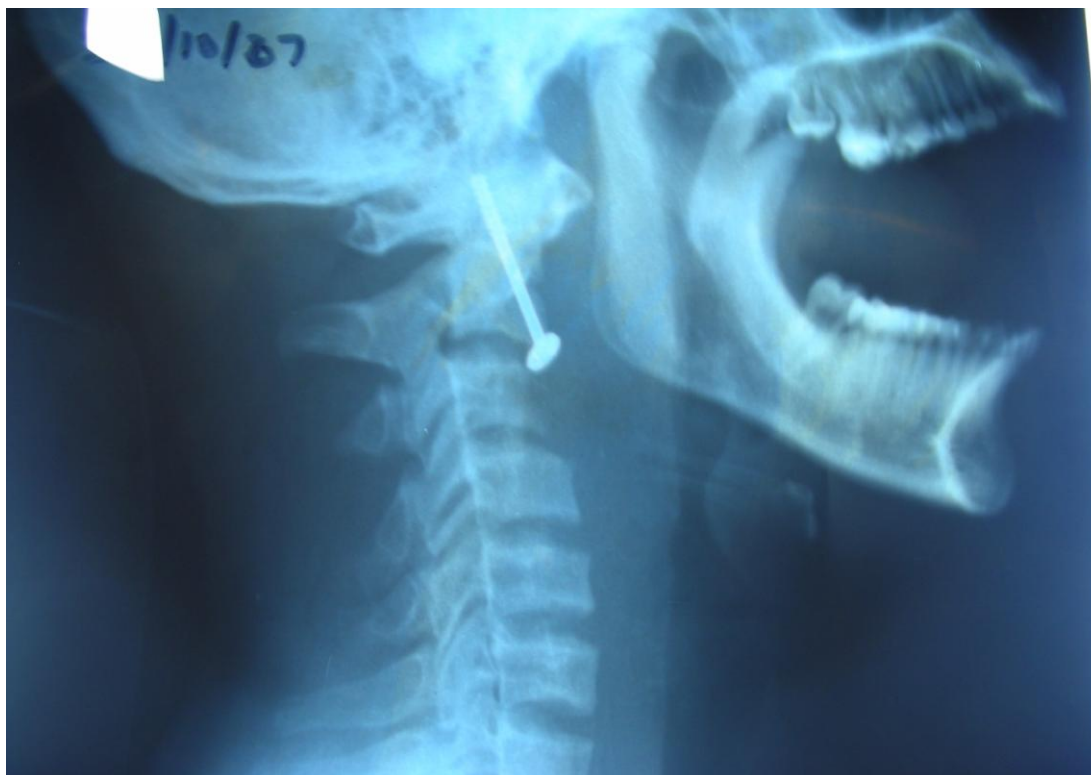

Fig. 5a: *Odontoid Screw Fixation Postoperative X-rays.*

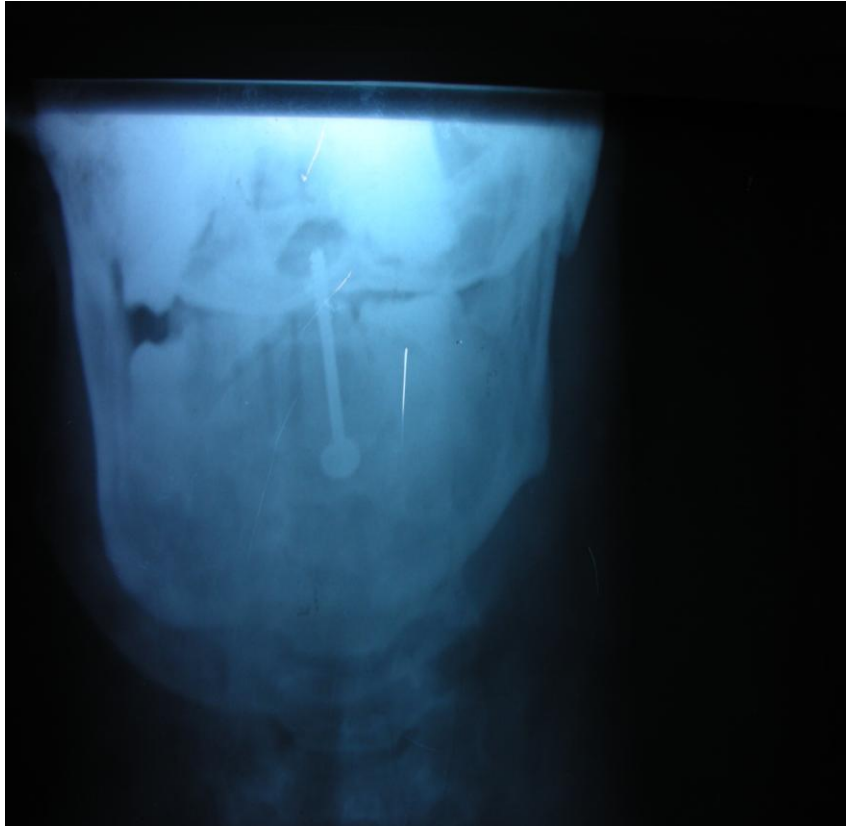

Fig. 5b: *Odontoid Screw Fixation Postoperative X-rays.*

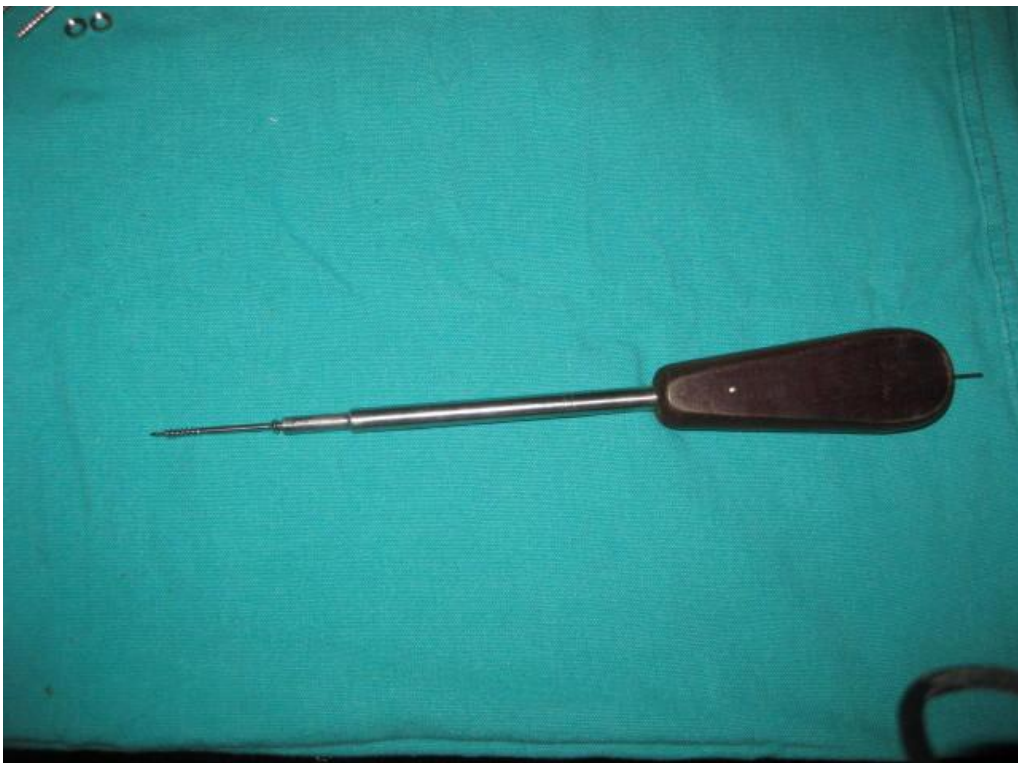

Fig. 6: *Odontoid Screw Ready for Application.*

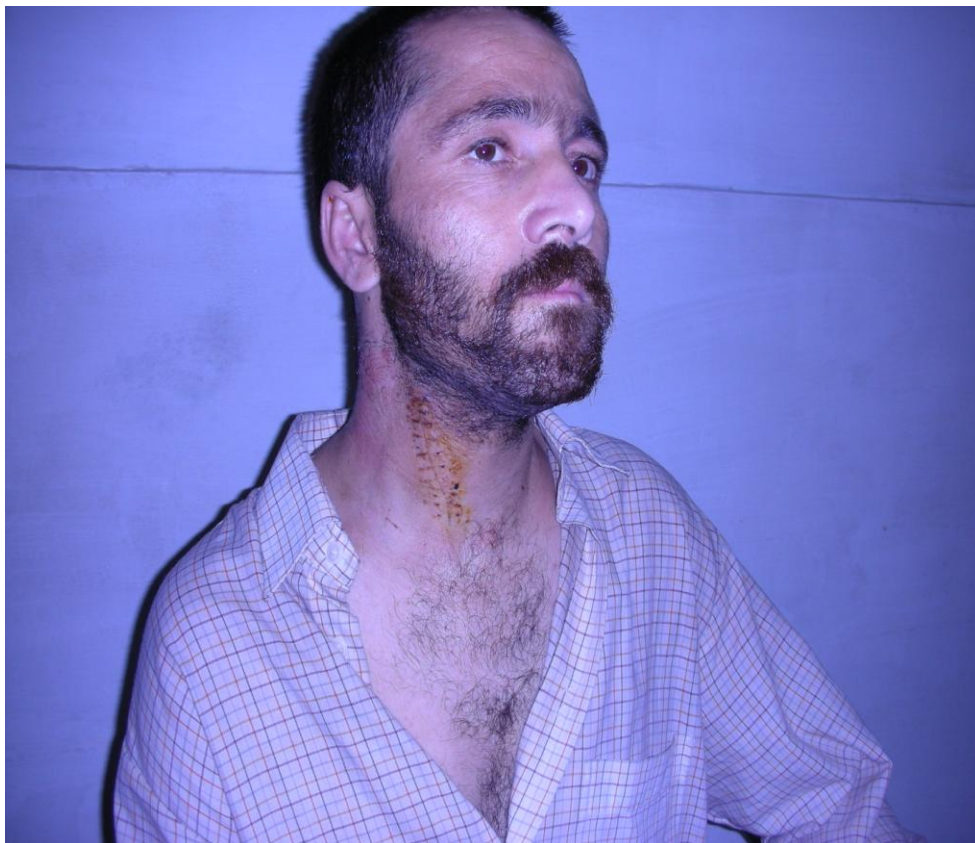

Fig. 7: *Odontoid Screw Fixation ---- Excellent Recovery of the Patient.*

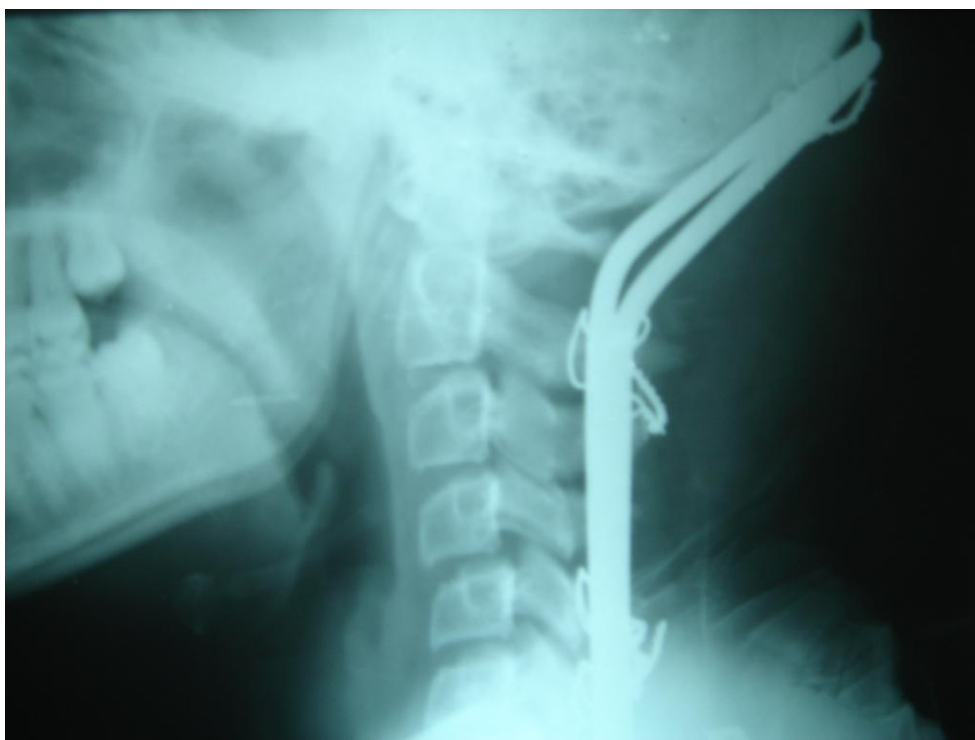

Fig. 8a: *Occipitocervical Fusion Postoperative X-rays.*

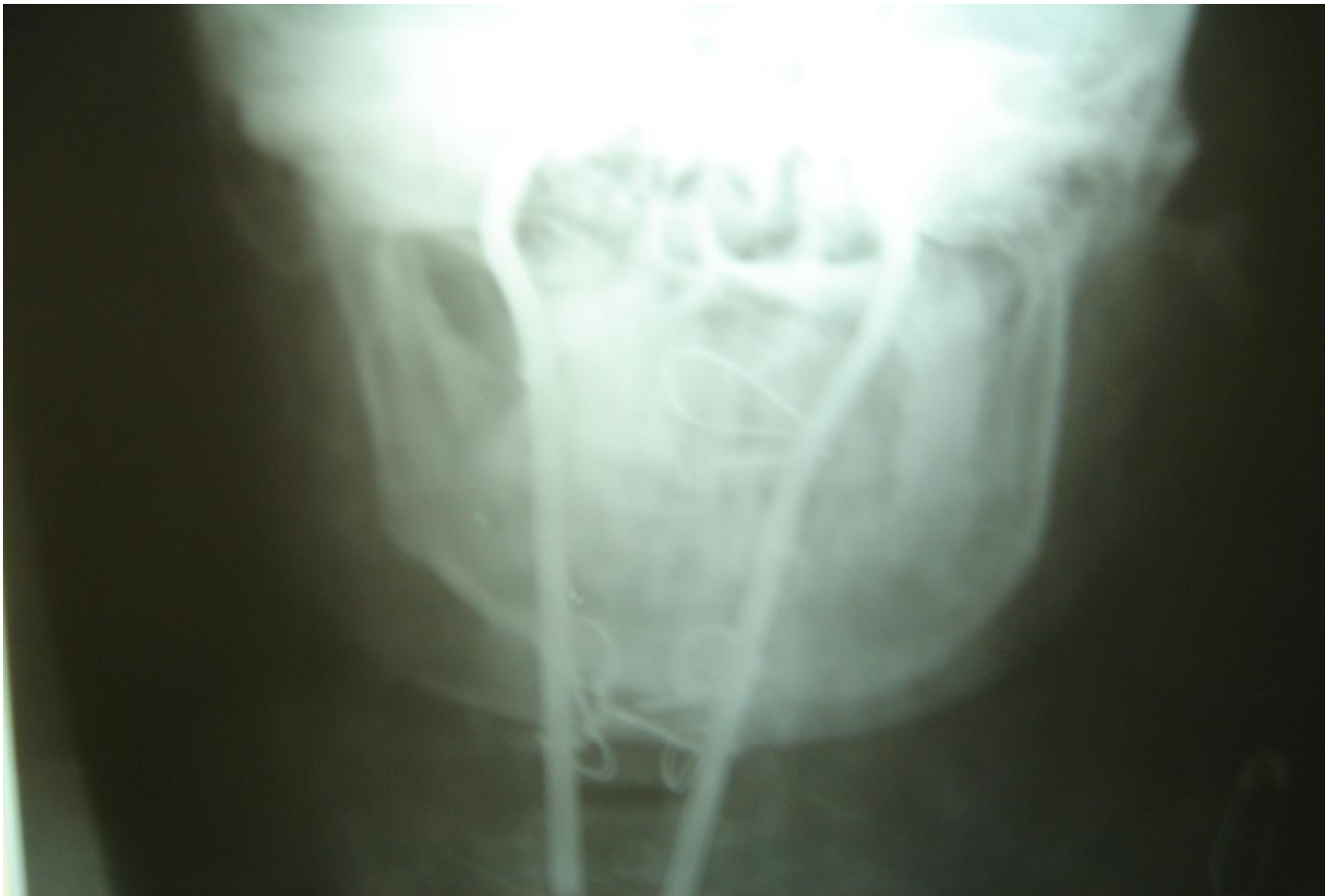


Fig. 8b: Occipitocervical Fusion Postoperative X-rays.

Table 2: Surgical Procedures Performed.

S. No.	Surgical Procedure	No. of Patients
1.	Atlantoaxial Fusion	7
	Gallies Fusion	4
	Brooks Fusion	3
2.	Occipitocervical Fusion	2
3.	Transodontoid Screw Fixation	2
4.	Transoral Decom and Post Fixation	4
	Total	15

(13.33%) having concomitant C₁ injury occipitocervical fusion was done. Initial transoral decompression, prior to posterior fusion was done in all four (26.66%) non reducible injury patients. Transodontoid screw fixation was done in two patients (13.33%) having intact transverse ligament (Table 2).

Outcome

Table 3 shows the surgical procedure, its associated complications outcome of complication after treated and net outcome of the study. Overall 07 (46.66%) cases revealed excellent results all recovered without any complication. Four (26.66%) cases had some complication but recovered with 02 weeks and result was labeled as good. Two cases who had neurological determination, recovered slowly in 03 months. Recovers was labeled as for one patient who suffered neurological determination did not recovered and result was labeled as poor.

Complications

Our one patient (6.66%) died after severe chest infection, although severe chest infection observed in three patients (20%). Mild wound infection and wound dehiscence seen in one patient (6.66%) each. The result was labeled as good as they recovered within 02 weeks. These patient were managed conservatively

Table 3: Surgical Procedure Complications Outcome.

No.	Surgical Procedure and Number of Cases	Complication	Outcome of Complications	Net Outcome
1.	Atlantoaxial Fusion 07 cases Gall's Fusions 4 cases	No complication 01 Case Wound Injection 01 Case Chest Injection 02 Cases	Recovered in 2 weeks Recovered in 2 weeks 01 case Death in 01 case	Excellent 01 case Good = 1 Good 1 Case Mortality 1 Case
	Brook's Fusion 3 cases	Neurological Deterioration 01 Case No Complication 02 Case	Recovered in 2 Months	Fair = 01 Excellent = 02 Cases
2.	Occipitocervical Fusion 2 cases	Neurological Deterioration 01 Case No Complication 01 Case	Recovered slowly within 2 Months	Fair = 01 Excellent = 01 Case
3.	Transoral Decompression and Posterior Decompression 04 cases	Wound Dehiscence 01 Case Chest Injection 01 Case Neurological Deterioration 01 Case No Complication 01 Case	Recovered in 2 Weeks Recovered well, 01 case No Recovery	Good = 1 Case Good = 1 Case Poor = 1 Case Excellent = 01 Case
4.	Transodontoid Screw Fixation 02 cases			Excellent = 02 Cases
			Net Outcome	Excellent = 07 Cases Good = 04 Cases Fair = 02 Cases Poor = 01 Case Mortality = 01 Case

Table 4: Net Outcome.

Outcome	No.	%
Excellent	7	46.66%
Good	4	26.66%
Fair	2	13.33%
Poor	1	6.66%
Mortality	1	6.66%

successfully. Neurological deterioration observed in three patients (20%), out of them two patients (13.66%) improved with passage of time. The outcome was labeled as "Fair", one who had poor or no recovery was labelled as "poor" outcome (Table 3 & 5).

DISCUSSION

Craniovertebral junction trauma is one of the worst skeletal trauma that carry a high likelihood of death

Table 5: Complication

1	Wound Dehiscence	1	6.66%
2	Wound Infection	1	6.66%
3	Chest Infection	3	20%
4	Neurological Deterioration	3	20%
5	Death due to chest injection	1	6.66%

and severe morbidity. Many times craniovertebral junctional injuries are difficult to diagnose on initial imaging studies.⁴ Successful management of these injuries depends on familiarity with the normal anatomic relationships of this region of the spine and recognition of the critical consequences of injured structures.

Craniovertebral junction is a zone of transition between mobile head and relatively rigid spine. The incidence of trauma to this region was significantly low in the past. Probably with advancement in medical emergency services, now make it possible to deal these

patients immediately at site of injury with proper initial resuscitation, followed by their shifting to respective neurosurgical intensive care units. Thus increase in number of such trauma patients are observed in Neurotrauma centers, because of reduced incidence of on spot death, as well as by prevention of progression of neurological symptoms due to proper immobilization of spine.¹

Among spinal cord injuries upper cervical spine trauma is relatively rare. While high cervical injuries are relatively more common in children, as the fulcrum for flexion and extension is at C₂ – C₃, as compared to at C₅ – C₆ in adults. In our study we detected fifteen patients over a period of five years; mostly our patients were young males that are comparable to most of international studies on spinal injuries.⁸ In USA each year 11200 new cases are reported, mostly in young males after road traffic accidents.

Common traumatic injuries at the CVJ include atlanto-occipital dislocation, atlantoaxial subluxation/dislocation, odontoid fractures, and fractures of the ring of C₁ (Jefferson fractures. Odontoid fracture was most commonly found in our patients. That is comparable to international literature, as Type II odontoid fractures are the most common nondistractive fractures of the upper cervical spine, associated with significant morbidity and even mortality in many studies. The frequency of neurological injury with type II odontoid fractures ranges from 18% to 25%. Fracture nonunion and missed injuries are the common causes of complications. Pseudarthrosis of a type II odontoid fracture that is defined as the absence of fracture site bridging after 4 months of treatment, is a leading cause of secondary neurologic deterioration.⁹⁻¹¹

We didn't find an isolated case of atlas fracture, however combined C₁ – C₂ trauma detected in two patients. Atlantoaxial instability seen in eight patients, in five patients it was reduced with crutchfield cervical traction, while in three patients it was irreducible.

Definitive treatment of craniocervical trauma is to achieve stability by instrumentation and bony orthodesis. We utilized occipitocervical, and atlantoaxial posterior fixation in all reducible injuries. While open mouth reduction followed by posterior fusion in non reducible injuries. Our management plan is comparable with different studies.¹² Transodontoid screw fixation of C₂ was performed in only those patients having intact transverse ligament. Odontoid is a pivot around which skull and atlas rotates. The beauty of transodontoid screw fixation is that it provide stability but not at expense of limited mobility.¹³

Overall our complication rate is slightly higher, probably because of poor back up services. Our three patients developed severe chest infection postoperatively and one patient died due to bad chest injection. Three patients even deteriorated neurologically but 2 recovered gradually within 3 months. In our study young patients subjected to transodontoid screw fixation revealed excellent results which is comparable to other international studies.¹⁴

CONCLUSION

Craniovertebral Trauma needs to be diagnosed in time, they are rare but less common and complicated. It is mandatory to use proper clinical and radiological diagnostic modalities. We are convinced if managed properly their outcome is quite rewarding. The surgical approach had to be catered according to the type of fracture / instability reducibility or vice versa.

Address for Correspondence:

Dr. Fauzia Sajjad

Assistant Professor

Department of Neurosurgery Unit II

Lahore General Hospital, Lahore

REFERENCES

1. Mendle E, Henstschel SJ, Guiot BH, Injuries to cervical Spine. In, *Principals of Neurosurgery* by Rengachary SS, Ellenhogan RG, PP: 369-80.
2. Aldy R, Lobato RD, Gomez P, Cervical spine fractures; In, *Manual of Neurosurgery*, James DP, PP: 723-30.
3. G.Y. El-Khoury, D.L. Bennett and G.J. Ondr, Multi-detector-row computed tomography, *J Am Acad Ortho Surg* 2004; 12: pp. 1-5.
4. C. Van Gilder, A.H. Menezes and K.D. Dolan, Radiology of the normal craniocervical junction. In: J.C. Van Gilder, A.H. Menezes and K.D. Dolan, Editors, *The Craniocervical Junction and Its Abnormalities*, Futura, New York, NY 1987: pp. 29-68.
5. Tranlis VC, Kaufman HH, Atlanto-occipital dislocation: In Rengachary SS, *Neurosurgery* 2nd Edition Vol. 2BPP; 2871-90.
6. Zavanone M, Guerra P, Rampini P, et al. Traumatic fractures of the craniocervical junction. Management of 23 cases. *J Neurosurg Sci* 1991; 35: 17-22.
7. Fairholm D, Lee ST, Lui TN. Fractured odontoid: The management of delayed neurological symptoms. *Neurosurgery* 1996; 38: 38-43.
8. Wertheim SB, Bohlman HH. Occipitocervical fusion. Indications, technique, and long-term results in thirteen patients. *J Bone Joint Surg Am* 1987; 69: 833-836.

9. Geisler FH, Cheng C, Poka A, et al. Anterior screw fixation of posteriorly displaced type II odontoid fractures. *Neurosurgery* 1989; 25: 30–37; Discussion 37–38.
10. Clark CR, White AA 3rd. Fractures of the dens. A multicenter study. *J Bone Joint Surg Am* 1985; 67: 1340–1348.
11. Braun JP. Traumatic and posttraumatic lesions of crani-overtebral junction. *Radiologie* 1978, Feb; 18 (2): 58–61.
12. Borm W, Kast E, Richter HP, et al. Anterior screw fixation in type II odontoid fractures: Is there a difference in outcome between age groups? *Neurosurgery* 2003; 52: 1089–1092; Discussion 1084–1092.
13. Schatzker J, Rorabeck CH, Waddell JP. Fractures of the dens (odontoid process). An analysis of thirty-seven cases. *J Bone Joint Surg Br* 1971; 53: 392–405.
14. Anderson S, Rodrigues M, Olerud C. Odontoid fractures: High complication rate associated with anterior screw fixation in the elderly. *Eur Spine J* 2000; 9: 56–59.