

MVD as the First Line Therapy after Failed Medical Treatment; for Idiopathic Trigeminal Neuralgia

ATTIQ-UR-REHMAN, ABDULLAH HAROON, ASIF SHABBIR

Abdul Majid, Shahid Hameed

Department of Neurosurgery Unit – I, PGMI / Lahore General Hospital, Lahore

ABSTRACT

Objective: To analyze the outcome of MVD as a first choice therapy when medical treatment has failed for the definitive management of Idiopathic Trigeminal Neuralgia.

Material and Methods:

Study was conducted at the Department of Neurosurgery PGMI / Lahore General Hospital, Lahore. This was a prospective observational case series from January 2007 to December 2008, 50 selected patients of Idiopathic Trigeminal Neuralgia diagnosed after radiological and clinical exclusion of secondary causes of Neuralgia presenting in whom medical management had failed were offered MVD as the first Intervention. All the patients were followed for one year post-operatively.

Results: Mean age was 59.2 years and minimum age 47 year and maximum 72 years. There was 16 males (32.0%) and females were 34 (68.0%). Male to female ratio was 1: 2.16. In 15 (30.0%) patients facial pain was on left side and 35 (70.0%) patients had right sided pain. V₁ was found in 1 (2.0%) patient, V₃ in 2 (4.0%) patients, V₁ and V₂ in 2 (4.0%) patients, V₁₋₃ in 17 (34.0%) patients, V_{2,3} in 28 (56.0%) patients. An Arterial loop was found in 37 (74.0%) patients as the compressing agent and a Vein only in 4 (8.0%) patients. Mixed artery and vein in 8 (16.0%) patients. Thick arachnoid was the compressing agent in 1 (2.0%) patient. Out of 50 patients 46 (92.0%) had Excellent outcome, 3 (6.0%) patients had Good outcome, 1 (2.0%) patient was in Fair outcome group. No patients were in Bad and Failure outcome groups.

Conclusion: Microvascular Decompression of trigeminal nerve is a safe and first choice therapy when medical treatment has failed for the definitive management of Idiopathic Trigeminal Neuralgia in otherwise medically fit patients provided Surgeon has adequate experience of performing the procedure.

Key Words: Idiopathic trigeminal neuralgia, Microvascular decompression, Fascial Pain.

Abbreviations: MVD = Microvascular Decompression, TGN = Trigeminal Neuralgia.

INTRODUCTION

Trigeminal neuralgia is a debilitating facial pain disorder. When medications fail, procedures including percutaneous glycerol rhizotomy, percutaneous radio-frequency rhizotomy percutaneous balloon compression rhizolysis, stereotactic radiosurgical rhizolysis (GKS) i.e gamma knife surgery, and MVD are available to the patient. Because the safety, efficacy, and durability of MVD for trigeminal neuralgia in the young and elderly patients have been established, many

clinicians view MVD as the first line of treatment when medications fail.¹⁻⁸

We present a case series of 50 selected cases of typical Idiopathic TGN definitively managed by microvascular decompression of Trigeminal nerve after medical treatment has failed.

MATERIALS AND METHODS

From January 2007 to December 2008, 50 selected

patients of Idiopathic Trigeminal Neuralgia presenting through outpatient department of L.G.H were admitted. All the patients were diagnosed as “trigeminal neuralgia” with a typical pain on the basis of history and clinical examination, with a failed medical treatment. All of these patients had been given previous medical therapy (carbamazepine or baclofen), to which they had become refractory or intolerant. MRI Brain was done to rule out any non-idiopathic cases. All the patients underwent microvascular decompression (MVD) of 5th nerve in the Department of Neurosurgery Unit – I Lahore General Hospital Lahore.

Individual symptoms, clinical history, operative findings, and complications were recorded.

Operative results were assessed by clinical follow up and periodic phone surveys. The outcome of intervention was graded by an independent reviewer other than the operating surgeon.

Out come was rated at the end of one year according to following criteria,

Excellent. (Immediate complete relief of pain with no complication)

Good. (Complete relief of pain with in 3 month)

Fair. (Good relief of pain with in 6 month no recurrence within 1 year)

Bad. (Relief of pain is good but significant neurological deficit beyond 3month)

Failure. (No relief of pain at all.)

Surgical Technique

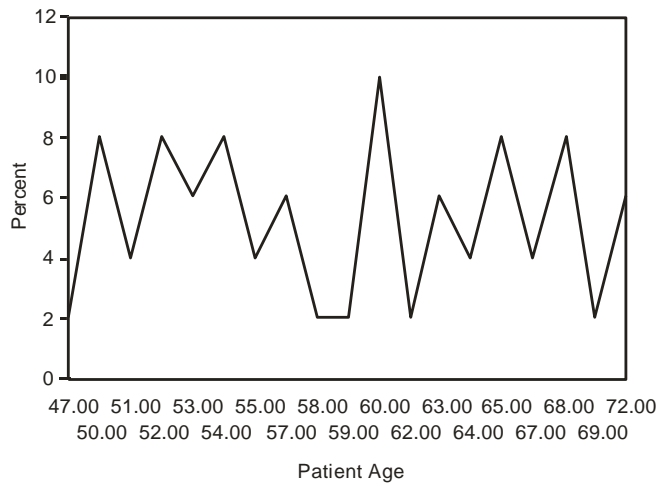
An MVD was performed under general anesthesia with the patient in the contralateral decubitus position A retromastoid incision was made behind the hairline, and a craniectomy about the asterion was performed. The intersection of the transverse sinus and sigmoid sinuses was identified, and the dura was opened. After appropriate brain relaxation was achieved with CSF drainage, the cerebellum was gently elevated and retracted, and the trigeminal nerve was identified and examined for vascular contact at the root entry zone. Most compressive vessels were decompressed using shredded Sugicel pledgets, while some veins, if smaller than the caliber of the superior cerebellar artery, were coagulated using bipolar cautery. Statistical analysis was performed with SPSS.

RESULTS

Age Incidence

Peak age was observed at around 60 years of age.

Mean age was 59.2 years and minimum age 47 year and maximum 72 years (Graph 1).



Graph 1: Age Incidence.

Sex Incidence

There were 16 males (32.0%) and 34 females (68.0%). Male to female ratio was 1: 2.16.

Table 1: Sex Incidence.

Sex	Number	Percentage
Male	16	32%
Female	34	68%
Total	50	100%

Side Involved

In 15 patients (30.0%) facial pain was on left side and 35 patients (70.0%) had right sided pain. Right sided nerve compression was found to be nearly double than left (Table 2).

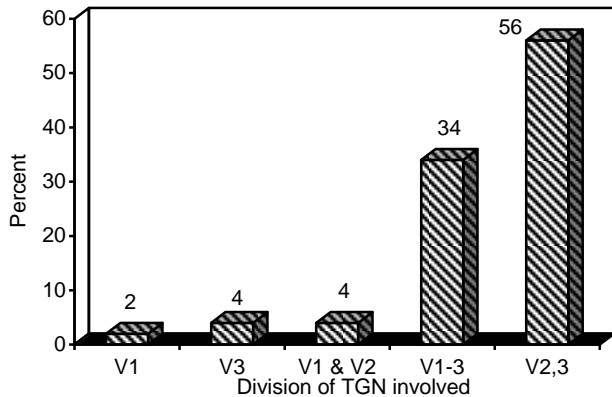
Table 2: Side Involved.

Side	Number	Percentage
Right Side	35	70%
Left	15	30%
Total	60	100%

Division of Trigeminal Nerve Involved

V₁ was found in 1 patient (2.0%), V₃ in 2 patients

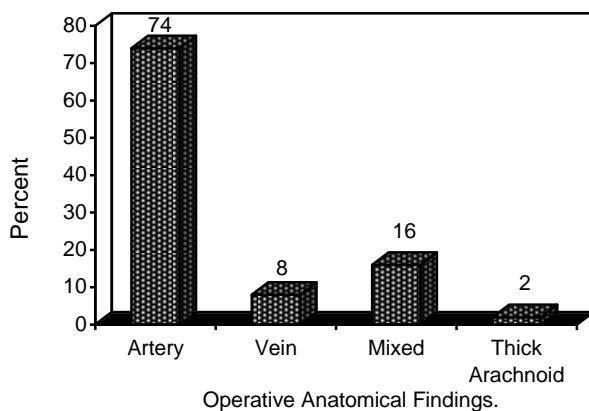
(4.0%), V₁ and V₂ in 2 (4.0%) patients, V₁₋₃ in 17 (34.0%) patients, V_{2,3} in 28 (56.0%) patients (Graph 2).



Graph 2: Division of TGN Involved.

Table 3: Division of TGN Involved.

Division	No.	Percentage
V ₁	1	2%
V ₃	2	4%
V _{1 and 2}	2	4%
V ₁₋₃	17	34%
V _{2,3}	28	56%
Total	50	100%



Graph 3: Operative Anatomical Findings.

Compression of Root Entry Zone

In a total of 50 patients undergoing MVD of Trigeminal Nerve an Artery was found in 37 (74.0%) patients

as the compressing agent and a Vein only in 4 (8.0%) patients, Mixed artery and vein in 8 (16.0%) patients. Thick arachnoid was the compressing agent in 1 patient i.e. patients (Graph 3 and Table 4).

Table 4: Operative Findings.

Compressive Patients	Number	Percentage
Artery	37	74%
Vein	4	8%
Mixed Artery and Vein	8	16%
Thick Arachnoid	50	100%

At the end of one year Out of 50 Total 46 (92.0%) patients had Excellent outcome, 3 (6.0%) patients had Good outcome, 1 (2.0%) patient was in Fair outcome group. No patients were in Bad and Failure outcome groups (Table 5).

Table 5: Outcome.

Outcome	Frequency	Percent	Valid Percent	Cumulative Percent
Excellent	46	92.0	92.0	92.0
Good	3	6.0	6.0	98.0
Fair	1	2.0	2.0	100.0
Total	50	100.0	100.0	

DISCUSSION

The best known description of trigeminal neuralgia (TGN), or a similar condition, was written in the second century AD by Aretaeus of Cappadocia, a contemporary of Galen. Also known for his descriptions of migraine, he makes reference to a pain in which 'spasm and distortion of the countenance take place'.⁹ Jujani, an 11th century Arab physician, mentions unilateral facial pain causing spasms and anxiety in his writings. Interestingly, he suggests that the cause of the pain is 'the proximity of the artery to the nerve'.¹⁰

The first full account of TGN was published in 1773 when John Fothergill presented a paper to the Medical Society of London. He described the typical features of the condition in detail, including paroxysms of unilateral facial pain, evoked by eating or speaking or touch, starting and ending abruptly, and associ-

ated with anxiety.⁹ Some time earlier, Nicolaus Andre Â had used the term 'tic douloureux' to describe what he thought was a new clinical entity. However, it has been suggested, that no more than two of the patients he described in fact had TGN.¹⁰

While, drug therapy remains the first line of treatment for trigeminal neuralgia (TGN), many patients do not achieve sufficient pain relief or suffer from side – effects. Furthermore, increasing numbers of patients are questioning the safety of long term medication. For these cases modern surgical treatments offer a safe and effective option with emphasis on microvascular decompression, a procedure which is reconstructive rather than destructive.¹¹

The concept of microvascular decompression of the trigeminal nerve described by Dandy in 1934,¹² rediscovered by Gardner and Miklos,¹³ and fully recognized and popularized by Jannetta¹⁴ was a milestone in the management of medically intractable trigeminal neuralgia. In the past 30 years thousands of patients have undergone successful microvascular decompression and today it represents one of the most widely used surgical options for trigeminal neuralgia. Several studies agree on high rate of long term success and even authors against the concept of microvascular compression perform it for its effectiveness.¹⁵

Some of the criticisms about MVD are based on presumed high mortality and morbidity. In our series there was no mortality and no permanent morbidity. At the end of one year Out of 50 Total patients 49(98.0%) patients were completely pain free and only 1 (2.0%) patient had Minor Trigeminal Complaints. Out of 50 patients 46 (92.0%) had Excellent outcome, 3 (6.0%) patients had Good outcome, 1 (2.0%) patient was in Fair outcome group. No patients were in Bad and Failure outcome groups. Ataxia, disequilibrium, and gait disturbances sometimes found in the early postoperative period. Fully recovered within 4 weeks without rehabilitation. Mean hospital discharge stay was 5 days post-operatively. The clinical and patient characteristics in our study were in line with the trends observed in other International and Pakistani studies.¹²⁻¹⁸ All our patients had failed medial treatment and were offered MVD as the interventional treatment of choice and majority had per-operative evidence of a vessel on 5th nerve.

Prior to the late 1970s surgical approaches were not without risk or side – effects. The standard approaches then were neuro-destructive, consisting of Gasserian ganglion alcohol injection, percutaneous radio-

frequency thermocoagulation (RFL) and fractional section of the sensory root – now known as partial sensory rhizotomy (PSR), carried out via a posterior fossa approach in the retro-mastoid region.¹⁹ By contrast, the early 1980s saw the introduction of non-destructive procedures; retrogasserian glycerol injection²⁰ and microvascular decompression.³ Microvascular decompression (MVD) has not only resulted in improved results but has led to a better understanding of the pathophysiology of Trigeminal Neuralgia. Importantly, the non-destructive procedures do not usually cause facial numbness.

MVD is now established as a safe and effective treatment for Trigeminal Neuralgia TGN in patients where medication has failed. Our study has indicated that MVD should be offered earlier and preferably as first – line treatment before any injection therapy which can adversely affect the operative success rate. Partial sensory rhizotomy still remains a good back-up procedure for those patients without vascular compression and gives a long – term cure rate similar to MVD. Meticulous surgical technique is essential and experience helps; it has been confirmed that surgeons performing high numbers of MVD procedures achieve better results.²¹

In a recent study of literature for respective long-term outcomes of various surgical modalities for trigeminal neuralgia by Tatli et al²² the authors have concluded that each surgical technique for treatment of trigeminal neuralgia has merits and limitations however, MVD provides the highest rate of long – term patient' satisfaction with the lowest rate of pain recurrence.

Stereotactic radiosurgery gamma knife surgery, might be considered an improvement of percutaneous and surgical techniques, but Pagni et al²³ has reported in a recent study that contrary to the expectations, the rate of complete pain relief at long term is lower. Gamma knife surgery and RFR (Radio Frequency Rhizotomy) are less effective than MVD which, in spite of the risks it entails, remains the choice treatment for typical trigeminal neuralgia.

CONCLUSION

It is concluded from our study that Microvascular Decompression is the first choice therapy when medical treatment has failed for the definitive management of Idiopathic Trigeminal Neuralgia in otherwise medically fit patients, provided Surgeon has adequate experience of performing the procedure.

Address for Correspondence

Dr. Attiq-ur-Rehman

Assistant Professor Department, of Neurosurgery

Postgraduate Medical Institute

Lahore General Hospital, Lahore

Cell: 0300-8411271

REFERENCES

1. Ashkan K, Marsh H: Microvascular decompression for trigeminal neuralgia in the elderly: a review of the safety and efficacy. *Neurosurgery* 2004; 55: 840–850.
2. Barker FG II, Jannetta PJ, Bissonette DJ, Larkins MV, Jho HD: The long-term outcome of microvascular decompression for trigeminal neuralgia. *N Engl J Med* 1996; 334: 1077–1083.
3. Javadpour M, Eldridge PR, Varma TR, Miles JB, Nurmikko TJ: Microvascular decompression for trigeminal neuralgia in patients over 70 years of age. *Neurology* 2003; 60: 520.
4. Kondo A: Follow-up results of microvascular decompression in trigeminal neuralgia and hemifacial spasm. *Neurosurgery* 1997; 40: 46–52.
5. Sekula RF, Marchan EM, Fletcher LH, Casey KF, Jannetta PJ: Microvascular decompression for trigeminal neuralgia in elderly patients. *J Neurosurg* 2008; 108: 689–691.
6. Sheehan J, Pan HC, Stroila M, Steiner L: Gamma knife surgery for trigeminal neuralgia: outcomes and prognostic factors. *J Neurosurg* 2005; 102: 434–441.
7. Sindou M, Leston J, Howeidy T, Decullier E, Chapuis F: Microvascular decompression for primary Trigeminal Neuralgia (typical or atypical). Long – term effectiveness on pain; prospective study with survival analysis in a consecutive series of 362 patients. *Acta Neurochir (Wien)* 2006; 148: 1235–1245.
8. Theodosopoulos PV, Marco E, Applebury C, Lamborn KR, Wilson CB: Predictive model for pain recurrence after posterior fossa surgery for trigeminal neuralgia. *Arch Neurol* 2002; 59: 1297–1302.
9. Rose FC. Trigeminal neuralgia. *Arch Neurol* 1999; 56: 1163-4.
10. Ameli NO. Avicenna and trigeminal neuralgia. *J Neurol Sci* 1965; 2: 105-7.
11. Coakham. The Surgical Treatment of Trigeminal Neuralgia. *ACNR • Volume 7, Number 2 • May / June 2007.*
12. Dandy WE. Concerning the cause of trigeminal neuralgia. *Am J Surg* 1934; 24: 447–55.
13. Gardner WJ, Miklos MV. Response of trigeminal neuralgia to decompression of sensory root. Discussion of cause of trigeminal neuralgia. *JAMA* 1959; 170: 1773–6.
14. Jannetta PJ. Arterial compression of the trigeminal nerve at the pons in patients with trigeminal neuralgia. *J Neurosurg* 1967; 26: 159–62.
15. Adams CBT. Microvascular decompression: an alternative view and hypothesis. *J Neurosurg* 1989; 57: 1–12.
16. Amjad S. Trigeminal neuralgia: analysis of pain distribution and Nerve involvement. *Pakistan oral & dental journal* Vol 28, No. 1; 2010.
17. Mumtaz Ali, Muhammad Pervez Khan, Abdul Aziz Khan, Zahid Khan. Idiopathic trigeminal neuralgia: clinical Presentations and operative findings on Microvascular decompression. *JPMI* 2009; Vol 23, No. 04: 322-325.
18. Riaz Ur Rehman, Azmatullah, Farooq Azam, Mohammad Ilyas. Microvascular Decompression in Patients with Intractable Idiopathic Trigeminal Neuralgia. *Journal of Surgery Pakistan (International)* 16 (1) January – March 2011.
19. Surgical Treatment of trigeminal neuralgia. Editorial. *BMJ* 1977; Vol 2: pt 6089.
20. Hakanson S. Trigeminal neuralgia treated by the injection of glycerol into the trigeminal cistern. *Neurosurgery* 1981; 9: 638-46.
21. Kalkanis SN, Eskander EN, Carter BS, Barker FG. Microvascular decompression surgery in the United States, 1996 – 2000: mortality rates, morbidity rates and the effects of hospital and surgeon volumes. *Neurosurgery* 2003; 52: 1251-61.
22. Tatli, M., Satici, O, Kanpolat, Y. Sindou, M. Various surgical modalities for trigeminal neuralgia: literature study of respective long – term outcomes. *Acta Neurochirurgica* , 2008; Volume: 150 Issue: 3; 243-55.
23. Pagni CA, Fariselli L, Zeme S. Trigeminal neuralgia. Non-invasive techniques versus microvascular decompression. It is really available any further improvement? *Acta Neurochir Suppl.* 2008; 101: 27-33.