

Recurrence of A.com – ACA Complex Cerebral Aneurysms after Coiling

ZUBAIR AHMED, UMAIR RASHEED, FAREEHA RAUF

Khurram Ishaque, M. Farooq

Department of Neuroradiology, PGMI / AMC / Lahore General Hospital, Lahore

ABSTRACT

Objective: To assess the recurrence of A.com – ACA complex cerebral aneurysms after coiling.

Materials and Methods: This study was conducted from July 2010 to December 2013 at the department of Neuroradiology, PGMI, Lahore General Hospital, Lahore. A total of 50 patients with cerebral aneurysms at the level of A.com – ACA complex were included in this study of both gender (male and female) and in the age range of 45 – 65 years.

Results: Out of 50 patients, there were 20 (40%) males and 30 (60%) female patients. Their age ranged from 45 – 65 years. The maximum numbers of patients were in their fifth and sixth decade of life. In our study successful coiling was done in all patients with minimal recurrence/recanalization of cerebral aneurysms at A.com – ACA complex.

Conclusion: Coiling is minimally invasive endovascular procedure routinely performed to treat cerebral aneurysms with an aim to highlight the significance of recognizing the large sized aneurysms recurrence / recanalization by regular follow up and early intervention to decrease morbidity and mortality of the patients.

Keywords: Cerebral aneurysm, endovascular coiling, A.com – ACA complex.

Abbreviations: GDCs = Guglielmi detachable coils. SAH = Subarachnoid hemorrhage.

INTRODUCTION

An intracranial aneurysm (also called cerebral or brain aneurysm) is a cerebrovascular disorder in which there is a balloon – like bulge of an artery wall. As an aneurysm grows, it thins and weakens. It can become so thin that it leaks or ruptures, releasing blood into the subarachnoid space around the brain. This bleeding is called a subarachnoid hemorrhage (SAH) and is life threatening.

The incidence of intracranial aneurysms is variable throughout the world and is approximately 6% in the international population, with rates being higher in Asian/Finnish populations and those with a high – risk profile. In those patients without any risk factors, the incidence is approximately 2%. Cerebral aneurysms are classified both by size and shape. According to size, are classified as below: **Small aneurysms** have a

diameter of less than 15 mm. **Larger aneurysms** 15 – 25 mm, **giant aneurysms** 25 – 50 mm and **super giant aneurysms** more than 50 mm have diameter (15 to 25 mm), giant (25 to 50 mm), and super giant (more than 50 mm).

Most intracranial aneurysms are asymptomatic and are never detected. Some of them are discovered incidentally in neuroimaging studies while some produce symptoms due to compression of neighboring cranial nerves or adjacent brain tissue. Others are detected only after they have ruptured and caused subarachnoid hemorrhage, a devastating type of stroke associated with 32% to 67% case fatality and 10% to 20% long – term dependence in survivors due to brain damage.¹

Cerebral aneurysms are mainly treated either by surgical clipping or by endovascular coiling. Coils accomplish from the inside what a surgical clip would

accomplish from the outside: they stop blood from flowing into the aneurysm but allow blood to flow freely through the normal arteries. Endovascular treatment of intracranial aneurysms was first described by Fedor Serbinenko, a Russian neurosurgeon in early 1970s.^{2,3} He used vascular catheter with detachable latex balloon to treat aneurysms, either by depositing balloon directly in aneurysm lumen or by occluding the artery from which the aneurysm arose. In 1991, Guido Guglielmi was the first to describe the technique of occluding aneurysms from an endovascular approach with electrolytic detachable platinum coils, termed Guglielmi detachable coils (GDCs).^{4,5}

As clinical experience with this technique has increased along with improvement coil design, endovascular coiling has been used with increasing frequency even in patients who could be treated by conventional surgical clipping.^{6,7} Furthermore, some centers are treating patients with surgical clipping only if they cannot be treated primarily by endovascular coiling.⁸

While a large meta - analysis found the outcomes and risks of surgical clipping and endovascular coiling to be statistically similar, no consensus has been reached. In particular, the large randomized control trial International Subarachnoid Aneurysm Trial appears to indicate a 7% mortality in lower, eight year rate and **28.6% - 33.6% of aneurysm recurrence within a year in aneurysms treated with coiling.**⁹⁻¹¹ There is 6.9 times greater rate of late retreatment for coiled aneurysms.¹²

Follow-up Protocol

Because the risk of aneurysm recurrence after endovascular coiling is higher than surgical clipping, all patients with coiled aneurysms are advised to return after 6, 12, and 24 months for a **diagnostic angiogram** to monitor for a **residual or recurring** aneurysm. A patient whose aneurysm ruptured should be checked earlier **at 3 months**.

MATERIALS AND METHODS

This study was conducted from July 2010 to December 2013 at the department of Neuroradiology, PGMI, Lahore General Hospital, Lahore. A total of 50 patients were included in this study of both gender (male and female) and in the age range of 45 - 65 years with history of subarachnoid hemorrhage. Endovascular coiling was done in all patients **with one year follow-up** by 3D angiography to note any recurrence / **reca-**

nalization of cerebral aneurysms at A.com - ACA complex.

RESULTS

Out of 50 patients, there were 20 (40%) male and 30 (60%) female patients. Their age ranged from 45 - 65 years. The maximum number of patients were in their fifth and sixth decade of life. In our study endovascular coiling was successfully done in all patients with recurrence / recanalization of aneurysms at A.com - ACA complex by regular radiological follow-up.

DISCUSSION

Intracranial aneurysms are potentially life threatening and disabling vascular lesions, which can pose formidable treatment challenges. Aneurysms may be treated in different ways, depending on the type of aneurysm, its location in the brain, and the patient's medical condition. **The standard method for treating a cerebral aneurysm is by doing aneurysm clipping,** although coiling due to its minimal invasiveness, early recovery, less complications and early discharge has wide advantage over surgical clipping and considered treatment of choice now a days.

Endovascular coiling is a procedure to thrombose / clot an aneurysm (a weak area in the wall of an artery) as shown in figure 1.

Coiling doesn't require a surgical procedure. Rather, a catheter is inserted in an artery in Groin and

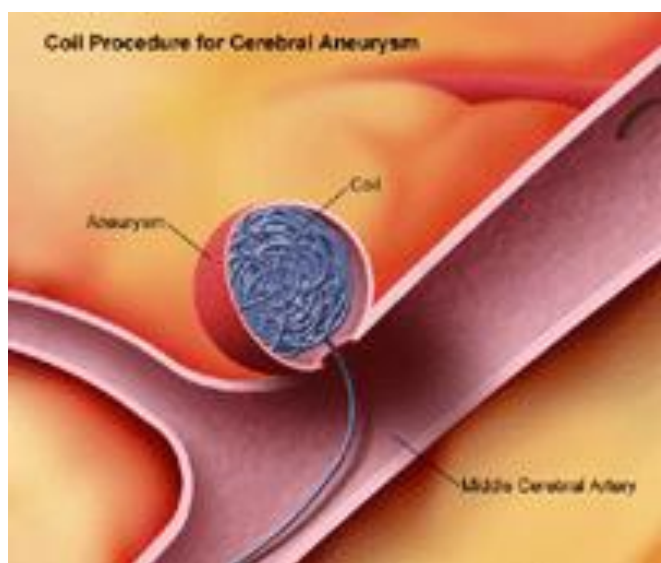


Fig. 1:

advanced it into the affected artery in the brain under fluoroscopic guidance. The coils used in this procedure are made of soft platinum metals and other materials and come in a variety of shapes, sizes, and coatings that promote clotting.

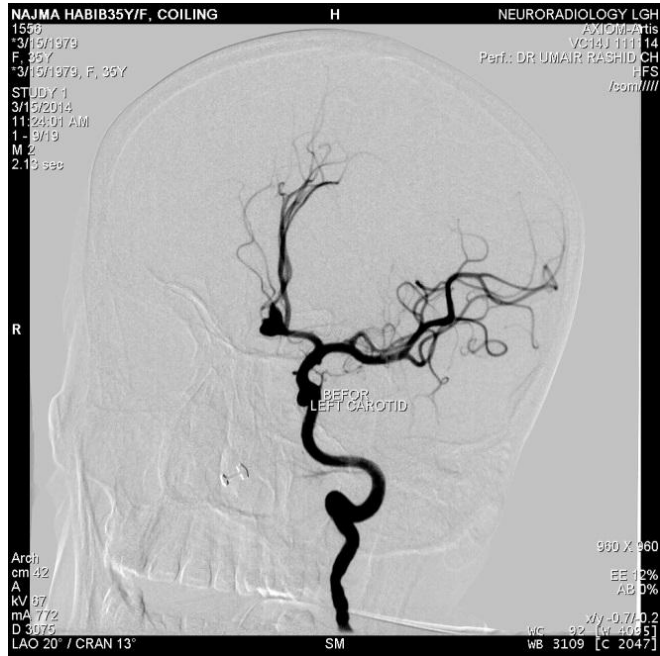


Fig. 2: Pre-coiling DSA.

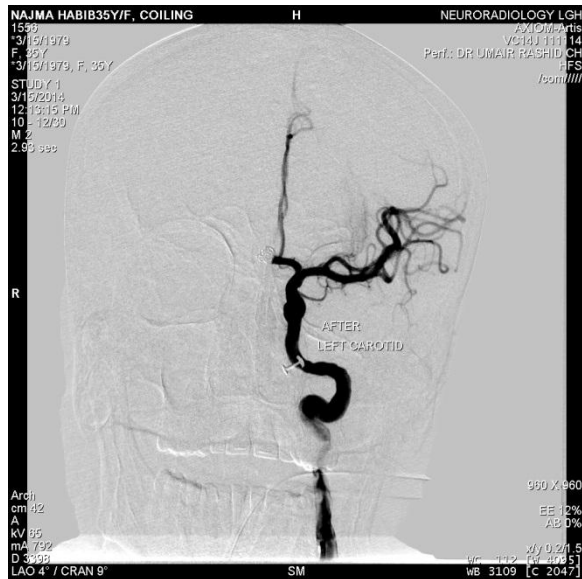


Fig. 3: Post-coiling DSA.

In our study of 50 patients including 20 males and 30 female patients, all of them had aneurysm of dif-

ferent size and shape at the level of A.com – ACA territory and had successfully undergone endovascular clipping as shown in figure 2 and 3. Patients were alright and discharged with advice to return after 6, 12, and 24 months after coiling for a diagnostic angiogram to monitor for a residual or recurring aneurysm.

From 1992 to 2002, *Jean Raymond, et al* conducted study on 383 post-coiled patients and found that

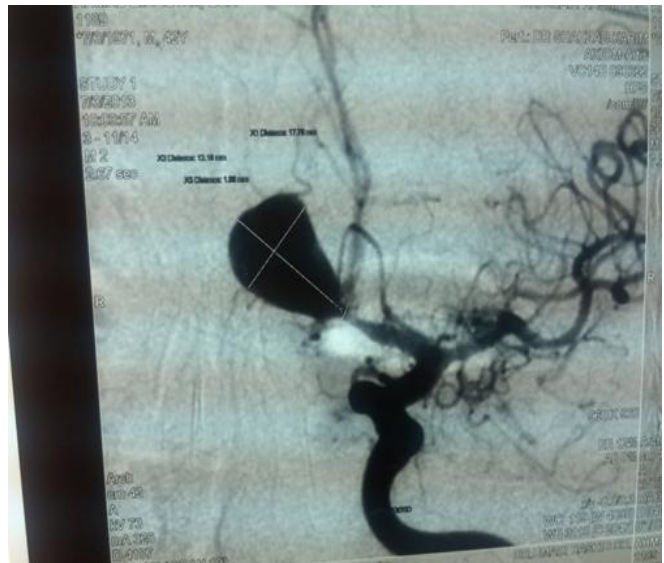

Fig. 4: Pre-coiling large sized aneurysm.

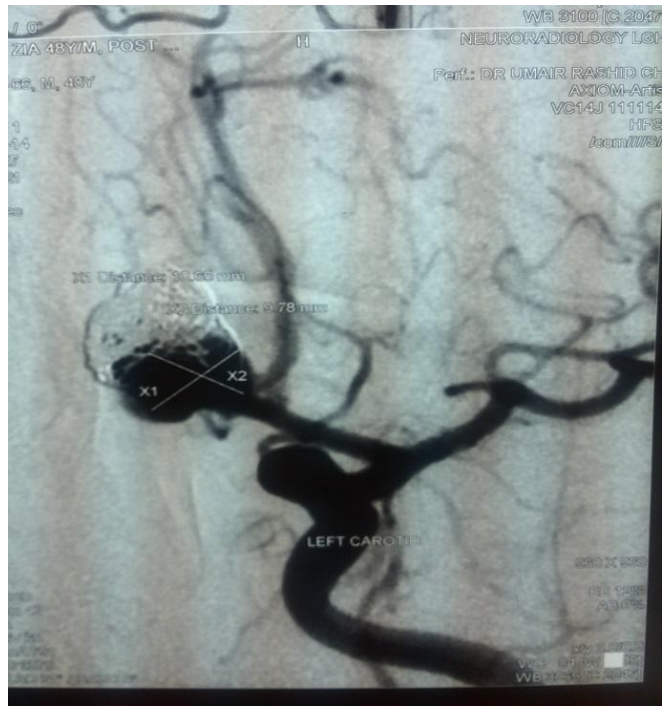


Fig. 5: Recanalization of aneurysm after one year.

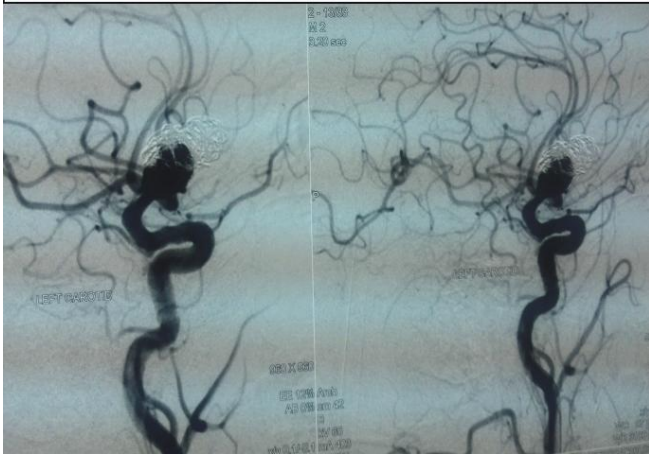


Fig. 6: Post-coiling recanalization after one year.

recurrences were found in 33.6% of treated aneurysms that were followed up and that appeared at a mean \pm SD time of 12.31 ± 11.33 months after treatment. Variables determined to be significant predictors ($P < 0.05$) of a recurrence included aneurysm size ≥ 10 mm, incomplete initial occlusions, and duration of follow-up.

In 2013, **Robert Corns, et al**, studied 239 post-coiled patients and revealed 34% recurrence after 6 months follow-up through angiography. He also advocated that aneurysms of A.com – ACA complex were less likely to recur or require treatment while aneurysms of the posterior communicating arteries were more likely to recur.

Molyneux A, et al, in 2002 followed 2143 post-coiled patients and found 34% recurrence of aneurysm.

In our study 50 patients were followed up radiologically (DSA) after one year and found that 01 (2%) out of 50 patients were presented with recurrence of aneurysm in the A.com – ACA territory as shown in figure 5 and 6. Rest of the patient’s angiography was un-remarkable.

The aneurysm that recurs was large sized A.com aneurysm as shown in figure 4.

CONCLUSION

As the risk of recurrence of large sized and residual aneurysm at A.com – ACA complex after endovascular coiling is higher than surgical clipping, all patients with coiled aneurysms are strictly advised to return (particularly the large ones) after 6, 12, and 24 months for a diagnostic angiogram / CTA to monitor

for a residual or recurring aneurysm. As early recognizing of recurring aneurysm will lead us to early intervention and decrease morbidity and mortality of the patient.

Address for Correspondence:

Dr. Zubair Ahmed

Department of Neuroradiology, PGMI / Lahore

General Hospital, Lahore

Email: zooobby@yahoo.com

REFERENCES

1. Hop JW, Rinkel GJ, Algra A, van Gijn J. Case – fatality rates and functional outcome after subarachnoid hemorrhage: a systematic review. *Stroke*, 1997; 28: 660–664.
2. Serbinenko FA. [Catheterization, and occlusion of major cerebral vessels and prospects for the development of vascular neurosurgery]. *VoprNeirokhir*. 1971; 35: 17–27.
3. Serbinenko FA. Balloon catheterization and occlusion of major cerebral vessels. *J Neurosurg*. 1974; 41: 125–145.
4. Guglielmi G, Vinuela F, Dion J, Duckwiler G. Electrothrombosis of saccular aneurysms via endovascular approach, part 2: preliminary clinical experience. *J Neurosurg*. 1991; 75: 8–14.
5. Guglielmi G, Vinuela F, Sepetka I, Macellari V. Electrothrombosis of saccular aneurysms via endovascular approach, part 1: electrochemical basis, technique, and experimental results. *J Neurosurg*. 1991; 75: 1–7.
6. Johnston SC, Wilson CB, Halbach VV, Higashida RT, Dowd CF, McDermott MW, Applebury CB, Farley TL, Gress DR. Endovascular and surgical treatment of unruptured cerebral aneurysms: comparison of risks. *Ann Neurol*. 2000; 48: 11–19.
7. Johnston SC, Zhao S, Dudley RA, Berman MF, Gress DR. Treatment of unruptured cerebral aneurysms in California. *Stroke*, 2001; 32: 597–605
8. Raftopoulos C, Mathurin P, Boscherini D, Billa RF, Van Boven M, Hantson P. Prospective analysis of aneurysm treatment in a series of 103 consecutive patients when endovascular embolization is considered the first option. *J Neurosurg*. 2000; 93: 175–182.
9. Mitchell P, Kerr R, Mendelow AD, Molyneux A. Could late re-bleeding overturn the superiority of cranial aneurysm coil embolization over clip ligation seen in IS-AT? *Journal of Neurosurgery*, 2008; 108: 437-442.
10. M; Spelle, L, Mounayer, C, Salles – Rezende, MT, Giansante – Abud, D, Vanzin – Santos, R, Moret. “Intracranial aneurysms: treatment with bare platinum coils – aneurysm packing, complex coils, and angiographic recurrence”, 2007; 243 (2): 500–8.

11. Raymond, J; Guilbert, F, Weill, A, Georganos, SA, Juravsky, L, Lambert, A, Lamoureux, J, Chagnon, M, Roy. "Long-term angiographic recurrences after selective endovascular treatment of aneurysms with detachable coils". Stroke, 2003; 34 (6): 1398–1403.
12. Campi, A; Ramzi N, Molyneaux AJ, Summers, PE, Kerr, RS, Sneade, M, Yarnold, JA, Rischmiller, J, Byrne. "Retreatment of ruptured cerebral aneurysms in patients randomized by coiling or clipping in the International Subarachnoid Aneurysm Trial (ISAT)". Stroke, 2007; 38 (5): 1538–44.

AUTHORS DATA

| Name | Post | Institution | E-mail |
|---------------------|-----------------------------------|--|------------------|
| Dr. Zubair Ahmed | PGR | Department of Neuroradiology, PGMI / Lahore General Hospital, Lahore | zoobby@yahoo.com |
| Dr. Umair Rasheed | Consultant Chief Neuroradiologist | | |
| Dr. Fareeha Rauf | Consultant Neurosurgeon | | |
| Dr. Khurram Ishaque | Assistant Professor Neurosurgery | | |
| Dr. M. Farooq | Consultant Neuroradiologist | | |