

# The Role of Decompressive Craniectomy in Traumatic Cerebral Contusions; A Prospective Observational Study

MEWAT SHAH, MUHAMMAD MUKHTAR KHAN, ASAD NABI

*Muhammad Ali Nouman, Atif Aman, Muhammad Nasir*

*Department of Neurosurgery, Hayatabad Medical Complex, Peshawar*

## ABSTRACT

**Background:** To investigate the role of decompressive craniectomy in traumatic cerebral contusions in terms of factors affecting outcome and the various surgical strategies which can be taken into consideration for contusion resection and cerebral decompression.

**Material and Methods:** The study was conducted from July 2013 to June 2014 at Department of Neurological Surgery Hayatabad Medical Complex Peshawar. A total of 35 patients were enrolled. The criteria included patients with traumatic cerebral contusion(s) who were eligible to undergo surgical decompression. The surgical procedures for intervention were classified according to the individual patient needs. Demographic data, inclusion parameters, surgical procedures, post-operative outcome and complications were recorded and analysed.

**Results:** Thirty five patients were included with a mean age of  $37.8 \pm 13.8$  years, 23 (65.7%) males and 12 (34.3%) females. The median Glasgow coma score at arrival was  $8 \pm 2.4$ , median Glasgow comma score at discharge was  $9 \pm 5$ . The median Glasgow outcome score at 3 months was  $4 \pm 1.6$  and a mean total hospital stay of  $10.9 \pm 8.1$  days.

**Conclusion:** Cerebral contusions comprise one of the most serious kind of traumatic brain insult with long term physical, mental and economic sequelae while imparting a heavy load of hospital inpatient mortality and morbidity.

**Keywords:** Head injury, brain contusion, traumatic brain injury, neurosurgery.

**Abbreviations:** GCS = Glasgow Coma Scale.

## INTRODUCTION

Brain trauma is one of the most disabling condition leading to lifelong physical, cognitive, emotional and social impairments. Traumatic brain injury even in its milder form may lead to drastic effects in terms of morbidity and mortality. In the developed countries the lifetime cost of brain trauma care is estimated to be more than 60 billion dollars annually, which is one of the largest expenditures in healthcare. The situation in developing countries is worse, as the brunt of patient's care falls directly upon the families and individuals who care for the patient. Worldwide an estimated 10 million people suffer from brain trauma annually.<sup>1,2</sup>

Among the various forms which a traumatic brain

lesion may take, contusion is one of the most severe form, having grave percentage of long-term morbidity and high mortality. Cerebral contusion are postulated to result from focal tearing of intracerebral vessels causing punctate haemorrhages which coalesce to expand the size and build fluid around itself to induce intracranial hypertension and even a transtentorial herniation.<sup>3,4</sup>

Various attempts have been made to postulate definitive clinical practice guidelines and to present the best surgical techniques for the treatment of cerebral contusions. Scales and classifications were also described in order to estimate the amount of structural damage, reach the optimal mode of treatment or to

take the best course of action when certain situation develops. However, despite all such attempts, the guidelines and practices of the neurotrauma specialists are still changing all over the world where some favour surgical intervention while many hold their knife back until the circumstances warrant its use.<sup>5-8</sup>

It is true that almost 25% of patients with moderate TBI and almost all of those with severe TBI have intraparenchymal contusions or intracerebral bleeds, however, only 25% of craniotomies or craniectomies are performed for the treatment of these lesions. This demonstrates the prevailing clinical practices of treating these lesions with medical means and constant monitoring. However, in cases where the patient's condition needs intervention, it is far better to intervene than to withhold invasive treatment.<sup>9-11</sup>

The most recent clinical recommendations from Brain Trauma Foundation of the American Association of Neurological Surgeons recommend surgical intervention for cerebral contusions in cases where the volume exceeds 25 – 30 cc (recently > 50 cc), midline shift of more than 5 mm on CT scan, deteriorating clinical status of the patient and persistently raised intracranial pressure due to the expansion of the contusion mass.<sup>9,10</sup>

Various operative techniques have been employed in order to resect the cerebral contusion, to decompress the ipsilateral hemicranium or to remove the particular cerebral lobe(s) in order to relieve the persistently raised intracranial pressure.<sup>12,20,21</sup>

Cerebral contusions can occur at any site in the brain and all of them have grave consequences for patients, however, contusions in the frontal and temporal lobes, unilaterally or bilaterally have frequently been operated upon and have been noted to respond to surgical treatment.<sup>13-16</sup>

Decompressive craniectomy / craniotomy was first introduced by Kocher in 1901 for relieving a persistently raised intracranial pressure. Since then it has been subjected to multiple studies so that its effect could be documented. This technique has been receiving a reappraisal among the neurotrauma specialists and for the last two decades multiple randomised controlled trials as well non randomised clinical studies have demonstrated that decompressive craniectomy do have a positive role in relieving the intracranial pressure of a head trauma patient, when all else fails. However, a class I evidence is still lacking and the recommendations are solely based upon class III studies.

Decompressive craniectomy for patients with traumatic contusions is usually limited to those pati-

ents who manifests either persistent intracranial hypertension, GCS  $\leq$  8, midline shift of  $\geq$  5 mm and/or a volume of  $\geq$  30 cc. In developing countries like Pakistan, due to the lack of invasive intracranial pressure monitoring equipment and lack of well-equipped neurointensive care units, the clinical examination and frequently repeated CT scan of brain is used in order to identify expanding haemorrhagic contusion or the sequelae of intracranial hypertension. The grave outcome of severe TBI, lack of RCTs for surgical treatment of this subgroup and the general assumption that surgical decompression of a contusion is the only effective treatment option when conservative means are exhausted; studies into the effectiveness of decompressive craniectomy for cerebral contusion with regard to various factors affecting the outcome is the most warranted scientific effort which must be undertaken by the neurotrauma teams all around the globe.<sup>17-19</sup>

## MATERIAL AND METHODS

The current study was conducted at the Department of Neurosurgery, Hayatabad Medical Complex Peshawar, which is a well – equipped tertiary care department serving the population of the province of Khyber Pakhtunkhwa (> 20 million people according to 2012 estimates). The duration of the study was 12 months, from July 2013 to June 2014. The study was conducted in a prospective manner, where patients with contusions were received and kept under observation clinically and radiologically. Repeat CT scans were performed **two times in the first 24 hours** and once every day for the first 7 days or as warranted by the clinical findings. Patient who deteriorated clinically, those in whom the contusion was rapidly expanding due either to coalescing haemorrhages or surrounding oedema, those with midline shift of  $\geq$  5 mm on CT scan, signs of persistent raised intracranial pressure with compression of the basal cisterns or those who were presenting with concomitant subdural or extradural haematoma or highly depressed skull fractures were operated upon.

The surgical approach was selected as was guided by the radiological findings and according to the individual patient needs. Postoperatively the patients were admitted to the high dependency unit and were monitored over their clinical and neurological course. Frequent repeat CT scans were obtained and note was made of the clinical findings.

Data was also collected about the patient demographics i.e. gender, age, and the clinical variables such as

arrival GCS, time since injury, systolic BP, pupillary status, CT based diagnosis, presence of midline shift (MLS), presence or absence of other intracranial haematomas such as subdural or extradural haematomas, total volume of contusion, associated trauma and presence or absence of comorbidities. The surgical indication and surgical intervention procedure were also recorded. Postoperative course was recorded in terms of vitals, postoperative GCS, complication development, total hospital length of stay and the GCS of the patient at the time of discharge. The clinical outcome was recorded in terms of Glasgow outcome score at 1 month and 3 months period. Presence or absence of complications were noted and treated accordingly.

Four main types of craniectomies were performed, namely, bifrontal craniectomy,

- left or right temporal craniectomy,
- left or right frontal craniectomy and
- left or right parietotemporal craniectomy.

Craniectomies were classified according to expansion duroplasty at closure or no duroplasty.

Informed consent was taken from all patients who were included in the study. All the baseline investigations and radiological tests required were obtained from the hospital labs.

The data was analysed using SPSS v20.0. Both parametric and non-parametric tests were performed for various independent variables with regard to the dependent variables and note was made of the significance of each clinical factor that could affect the outcome.

## RESULTS

There were 182 patients of closed head injury diagnosed as having cerebral contusions. Out of these 35 (19.2%) patients were operated according to the defined criteria. Out of the 35 patients, there were 23 (65.7%) males and 12 (34.3%) females. Mean age was 37.8 years (SD = 13.8), where the minimum age was 12 years and maximum 65 years. There were 18 (51.4%) cases of RTA, 9 (25.7%) cases of fall, 7 (20%) cases of physical assault and 1 (2.9%) cases of crush injury. Median GCS at presentation was 8 (SD = 2.4) with 60% (21) patients with GCS  $\leq$  8 and no patient with a GCS above 13.

The median systolic BP was found to be 120 (SD = 31.8) with 30% (11) patients having a systolic BP of  $\leq$  100 mmHg. The diagnoses at CT brain was bifrontal contusions in 8 (22.9%) patients, followed by 5 (14.3%) patients of right temporal, 5 (14.3%) patients

each of right and left parietotemporal, 4 (11.4%) patients each of right and left frontal and 3 (8.6%) patients with left temporal contusions. The surgical procedure performed were similar to the incidence of individual diagnoses, i.e. bifrontal craniectomies in 8 patients, 5 right temporal craniectomies, 5 right and 5 left parietotemporal craniectomies, 4 right and 4 left frontal craniectomies and 3 left temporal craniectomies respectively. Expansion duroplasty was performed in 25 (71.4%) patients while 10 (28.6%) patients were closed without dural closure.

Pupillary reactivity was present in 20 (57.1%) patients with the rest 15 (42.9%) patients found to have non-reactive pupils either bilaterally or unilaterally. Midline shift of  $\geq$  5 mm on CT brain was present in 30 (85.7%) patients. There were 7 (20.0%) cases who also had a concomitant haematoma along with the presence of contusion.

Surgical indication included neurologic deterioration in 11 (31.4%) cases, increasing size of the contusion in 11 (31.4%) cases and increasing midline shift in 13 (37.1%) cases. Four (11.4%) patients had associated trauma to other areas of the body, such as the face and musculoskeletal system. 9 (25.7%) patients presented with comorbidities present before trauma such as hypertension, diabetes, asthma etc.

The mean 'time since injury' was 6.3 hours (SD =  $\pm$  2.2) which wasn't found to be significantly related to outcome at discharge or outcome at 3 months follow up ( $p = 0.75$ ). However, it (time since injury) was correlated positively to the pupillary abnormalities (reactive vs. non-reactive pupils) which were observed in these patients ( $p = 0.03$ ).

The complications recorded were 12 (34.8%) cases of aspiration pneumonia, 9 (26%) cases of hospital acquired pneumonia, 5 (14.5%) cases of postoperative CSF leak through the wound, 2 (5.8%) cases of acute meningitis, 8 (23.2%) cases of progressive neurologic deterioration despite decompression, 5 (14.5%) cases of postoperative seizures, 3 (8.7%) cases of adult respiratory distress syndrome, 7 (20.3%) cases of wound infection and 3 (8.7%) patients developed hydrocephalous during the course of their illness. One patient who was a middle aged female developed acute heart failure for which the cause could not be ascertained. Some patients usually had a combination of multiple complications, for example one patient had adult respiratory distress syndrome with concomitant wound infection and postoperative seizures.

A mean contusion volume of 35.0 cc was noted with a standard deviation of  $\pm$  9.0 cc. 74.3% (26)

**Table 1: GCS at Discharge.**

GCS	N	Percentage
3	13	37.1
7	1	2.9
8	2	5.7
9	2	5.7
10	1	2.9
11	2	5.7
12	2	5.7
13	2	5.7
14	3	8.6
15	7	20.0
Total	35	100.0

patients presented below a contusion volume of  $\leq 40$  cc. Mean total hospital stay was 10.9 days (SD = 8.1). The median GCS at discharge was 9 (SD = 5.0). About 71.4% (n = 25) patients were discharged at a GCS of  $\leq 13$  (Table 1). The median GOS at 1 month was 3 (SD = 1.3) while median GOS at 3 months was 4

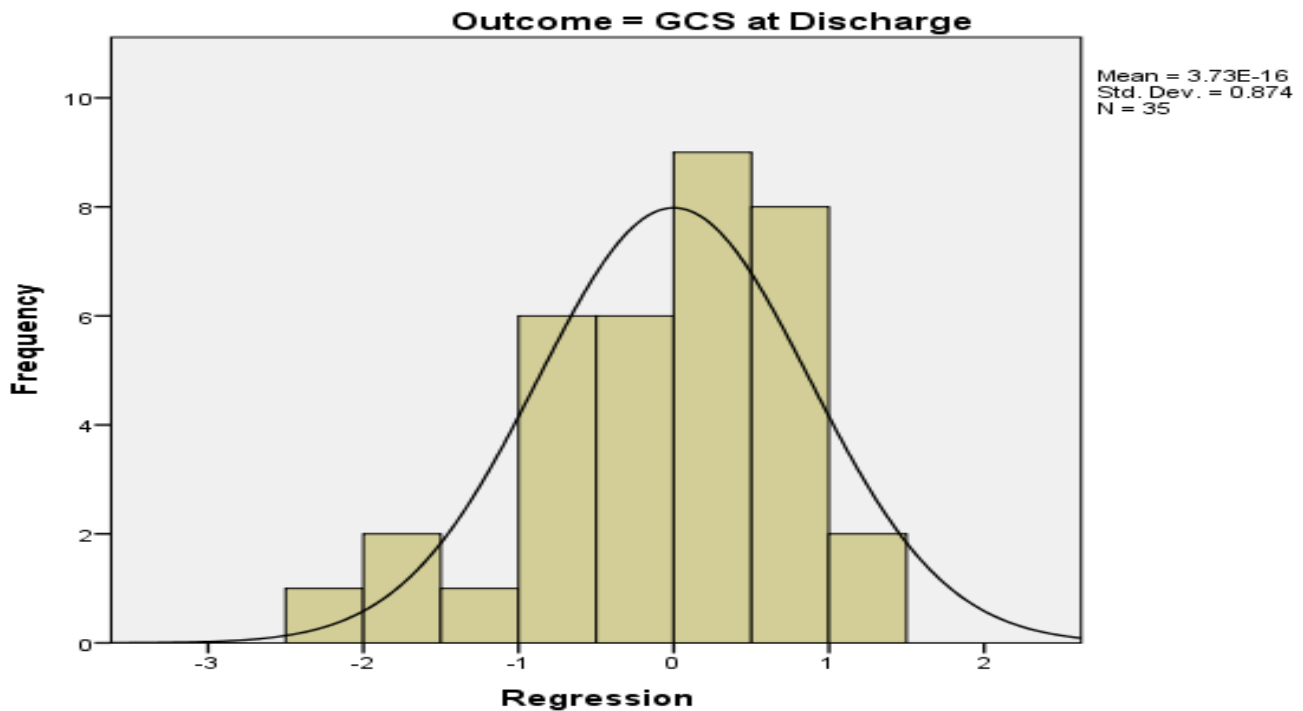
(SD = 1.6). Only 27.3% (n = 9) patients were noted to score a GOS of 5 at 3 months (Table 2).

**Table 2: GOS at 3 Months.**

GOS	N	Percentage
1: (Dead)	14	40.0%
2: (Vegetative)	0	0
3: (Moderately Disabled)	4	11.4%
4: (Minor Disability)	8	22.9%
5: (Full Recovery)	9	25.7%
Total	35	100.0

The mortality was 12 (37.1%) patients at discharge while 2 more patient died of complications at a follow up of 3 months.

The Pearson correlation was significant for age of the patient and GCS at discharge ( $p < 0.001$ ), Co-morbidities and GCS at discharge ( $p < 0.001$ ), age and co-morbidities ( $p = 0.009$ ) and also GCS at presentation and pupillary status ( $p = 0.03$ ) were positively correlated.



**Figure 1: Frequency of GCS at Discharge.**

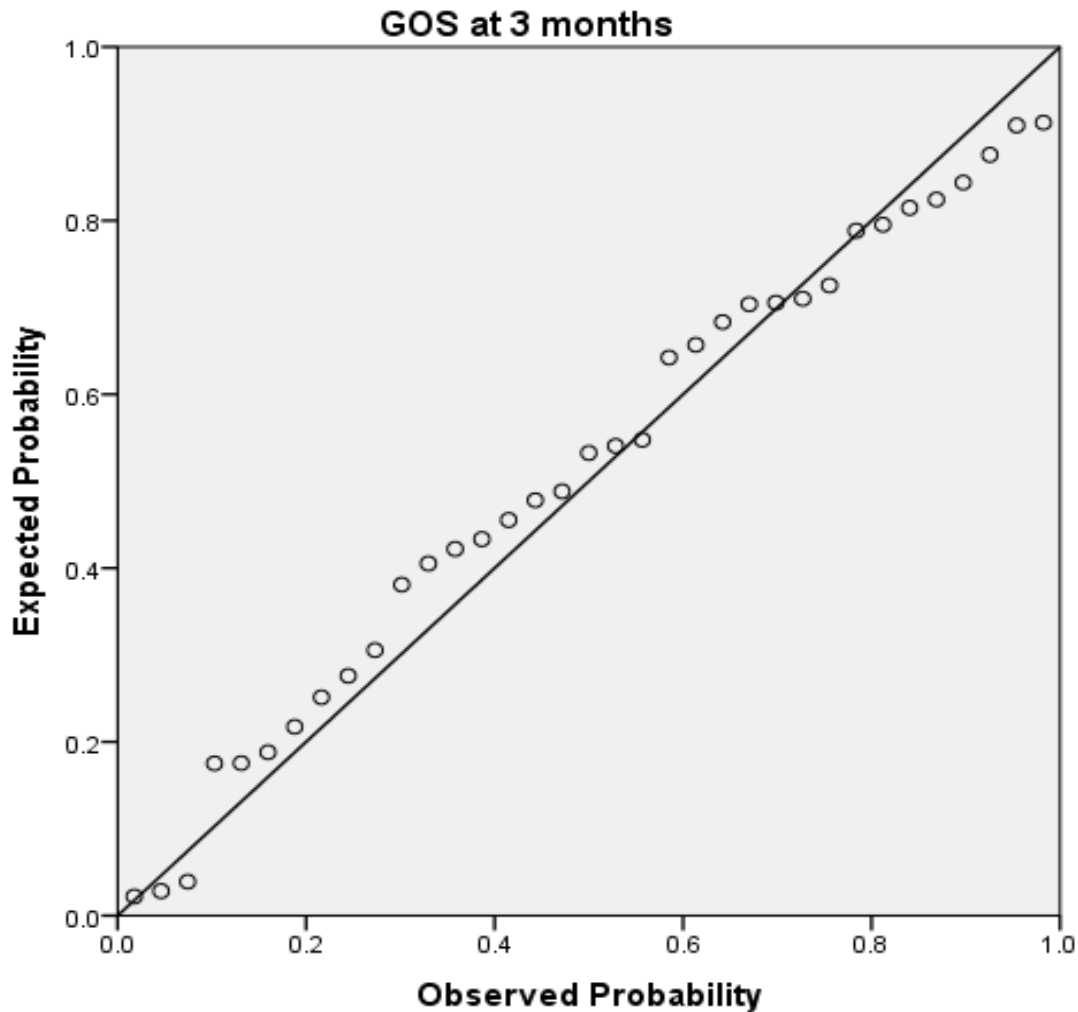


Figure 2: Expected vs. Observed Probability for GOS at 3 Months.

ANOVA while taking GCS at discharge as the outcome variable showed statistical significance ( $p < 0.001$ ) to the following predictors (if kept constant); Co-morbidities, GCS at presentation, midline shift, volume of contusion, pupillary reflex, systolic BP, patients' age and gender.

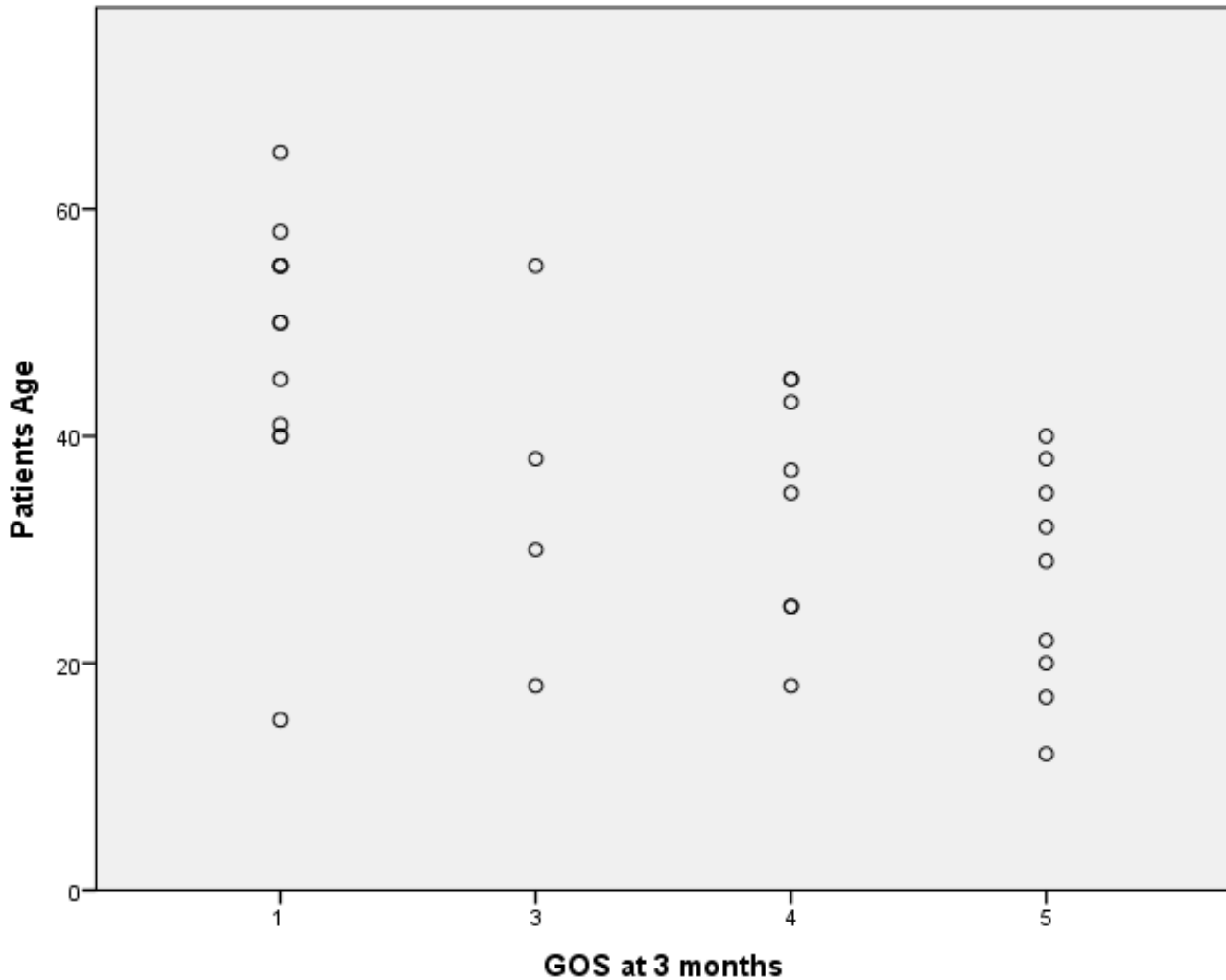
Similarly, Pearson correlation remained significant for GOS at 3 months when linear regression was performed for age ( $p < 0.001$ ) (Figure 3), co-morbidities ( $p < 0.001$ ) and GCS at arrival to pupillary reflex ( $p = 0.03$ ).

## DISCUSSION

Cerebral contusion is a grievous injury which is associated with high mortality and prolonged morbidity in terms of longer hospital stay and lengthy recovery

period. Similarly, many patients who suffers from this condition remains disabled, physically and behaviourally for a long period or even for the rest of their lives. The premise of decompressing a contused area of the brain is based on the findings of accumulating increased tissue breakdown (Mathai et al, Kawamata et al, Katayama et al),<sup>9-11</sup> coalescing punctate haemorrhages into larger haematoma and sequestration of fluids both within and around the contusion. The natural course of such a condition is understandably local swelling, increasing intracranial hypertension, reduced cerebral blood flow, ischemia and even transtentorial herniation.<sup>9</sup>

The development of a contusion is divided into three stages, where stage I (first 24 hours) is denoted by rapid development of swelling due to tissue breakdown and increase in the local osmolarity of more than



**Figure 3:** Age vs. GOS at 3 Months.

400 mosmol/kg. In stage II (24-48 hours) the activation of coagulation and inflammatory cascades start disrupting the blood brain barrier. The stage III (> 48 hours – 7 days) is characterized by expanding oedema with lysis of local RBCs, reactive oxygen species, inflammatory cytokines and complement activation which create a state of persistently raised intracranial pressure and consequently reduced cerebral blood flow. This has been shown that early intervention into reducing the expansion of a contusion or its effects on the rest of the brain tissue eventually improves outcome. However, on the other hand there are studies which demonstrates low benefit to the patients who undergo surgical decompression with or without a craniectomy (Mathai et al).

The role of repeat CT of the brain, osmotic diuretic therapy, hyperventilation and eventually decomp-

ressive craniectomy are to be favoured by the fact that neurotrauma centres in developing countries like Pakistan lacks invasive intracranial pressure monitoring and even a total lack of dedicated neurointensive care units. It has been shown that clinical and radiological evaluation of patients with severe traumatic brain injury helps in earlier recognition of the red flags for evolving irreversible neurologic deterioration and timely intervention by means of surgical decompression and resection of the contusion may actually save lives, although sometimes at the expense of prolonged or irreversible disabilities (Kawamata et al, Lobato et al, Sinha et al).<sup>13,15,19,25</sup>

Our study demonstrated that in severe traumatic brain injury associated with cerebral contusions the mortality and even prolonged morbidity could be reduced effectively only if vigilance is maintained. Patients

with severe traumatic brain injury and those with contusions are known to have a mortality of more than 70%, which could be reduced to less than 40% by earlier intervention as is evident from our study. Findings in a study by Sinha et al was a mortality of 50% to 63% postoperatively.<sup>19</sup>

Decompressive craniectomy for patients with severe TBI and contusions should be focused primarily on salvaging the malignant intracranial hypertension which could lead to rapid death, and also keeping in mind the neurologic dysfunction which could be associated with wide cerebral lobe resection. There should also be consideration of factors which clearly affect the outcome in such patients, such as age, extensive trauma to other systems, comorbidities and the effect of structural brain injury located in eloquent areas. Without consideration of the above factors, it would certainly be an effort in vain and patients will be a subject of irrelevant surgical exploration. Studies by Binghui et al and Sinha et al took approximately the same demographic and clinical variables which could affect the outcome and they concluded that i) Cerebral contusions should be aggressively managed and intervention contemplated earlier if a good postoperative outcome has to be suspected and, ii) in performing contusion resection, the safest method would be to focus on the contusion focus instead of gross cerebral lobe resection. This strategy would result in higher percentage of patients scoring favourable outcome on the GOS.<sup>19,21,24</sup>

Our study has demonstrated achievement of a GOS at 3 months (Table 2) of good outcome (GOS = 4 and 5) in about 50% of patients (48.6%), while only 12.1% of patients remain at unfavourable outcome (GOS = 2 and 3). The mortality of 40% is lower than the reported mortality of the non-operative groups (95% mortality for severe TBI in a study by Ghalige et al).<sup>24,26</sup> Factors such as age, time between injury and initiation of treatment, time of the surgical intervention after admission, GCS at presentation, pupillary abnormalities and trauma to eloquent cerebral cortical areas and also the presence or absence of subarachnoid haemorrhage, acute subdural and extradural haematomas are shown to clearly affect the outcome after decompressive craniectomy in these patients. This is consistent with the findings of Tjahjadi et al and Saini et al who found that lower GCS, age, CT changes of cerebral swelling, and midline shift are associated with poor outcome or earlier surgical intervention.<sup>24,25,28</sup> Decompressive craniectomy therefore, should only be sought in those patients who present with localised intraparenchymal lesions who do not respond to medi-

cal therapy of increasing ICP and those who needs earlier rescue from the devastating effects of malignant intracranial hypertension. Such observations are also recorded by Mathai et al, Sinha et al and Akyuz et al.<sup>9,19,20,23</sup> An epidemiologic study by De Silva et al found a 30% mortality for patients from economically advanced countries and more than 50% mortality from low or middle income countries with severe TBI. Similarly the good outcome (GOS = 4, 5) for severe TBI groups were ranging from 35% to 48% which is consistent with findings of the current study.<sup>27</sup>

The commonest complication in our study were respiratory abnormalities, such as aspiration pneumonia (34.8%), hospital acquired pneumonia (26%) and TBI associated adult respiratory distress syndrome (8.7%). Similarly, wound infection was observed in 20%, CSF leaks in 14% while hydrocephalous was observed in 8.7% patients. A study by Ban et al into complications associated with decompressive craniectomy were similar but at a lower rate than were observed in our study. For instance the postoperative wound infection was observed in 4.5% while postoperative epilepsy was observed in 3.4% of cases. These findings were not concurrent with our study where a very high percentage of postoperative wound infection was noted.<sup>29</sup>

These complications need special consideration. Earlier safety of the airway and respiratory function is of prime importance and specifically in unconscious patients the airway need to be managed long before arrival at hospital emergency. This shows that professional rescuers at the trauma scene should be well versed in earlier and effective endotracheal intubation and the risks associated with not establishing the airway. Rapid and efficient rescue could translate into dramatic improvements in patient outcome irrespective of the kind of surgical intervention.

## **CONCLUSION**

The study shows the grievous nature of severe TBI and the occurrence of cerebral contusion is a definitive risk for higher mortality and prolonged disability. Surgical intervention at the right moment can however, change the course of this fatal condition and lead to improved outcomes in cohorts of severe traumatic brain injury. Further studies into the effectiveness of decompressive craniectomy and the factors which affect the final outcome are required in order to establish a definitive course of action in such patients.

*Address for Correspondence:*  
*Dr. Muhammad Mukhtar Khan*  
*MBBS, FCPS II*  
*Postgraduate Resident*  
*Department Neurosurgery*  
*Hayatabad Medical Complex, Peshawar*

## REFERENCES

1. Kurland D, Hong C, Aarabi B, Gerzanich V, Simrad M. Hemorrhagic progression of a contusion after traumatic brain injury: A review. *Journal of Neurotrauma*. January, 2012; 29: 19-31.
2. Son S, Yoo CJ, Lee SG, Kim EY, Park CW, Kim WK. Natural course of initially non-operated cases of acute subdural hematoma: The risk factors of hematoma progression. *J Korean Neurosurg Soc*. September, 2013; 54: 211-219.
3. Sharma D, Vavilala MS. Perioperative management of adult traumatic brain injury. *Anesthesiol. Clin*. June, 2012; 30 (2): 333-346.
4. Garcia A. Critical care issues in the early management of severe trauma. *Surg. Clin. North. Am*. December, 2006; 86 (6): 1359-1387.
5. Yuan F, Ding J, Chen H, Guo Y, Wang G, et al. Predicting progressive hemorrhagic injury after traumatic brain injury: derivation and validation of a risk score based on admission characteristics. *J. Neurotrauma*. Aug. 2012; 29 (12): 2137-2142.
6. Bullock MR, Chesnut R, Ghajar J, Gordon D, Hartl R, Newell DW, et al. Surgical management of traumatic parenchymal lesions. *Neurosurgery*. 2006 Mar; 58 (3 Suppl): S25-46.
7. Huang X, Wen L. Technical considerations in decompressive craniectomy in the treatment of traumatic brain injury, 2010; 7 (6): 385-390.
8. Schnüriger B, Inaba K, Abdelsayed GA, Lustenberger T, Eberle BM, Barmparas G, et al. The impact of platelets on the progression of traumatic intracerebral hemorrhage. *J Trauma*. Apr. 2010; 68 (4): 881-5.
9. Mathai KI, Sengupta SK, Shashivadhanan, Sudumbekar SM. Surgery for cerebral contusions: Rationale and practice. *Indian J. Neurotrauma*. Jun. 2009; 6 (1): 17-20.
10. Kawamata T, Katayama Y. Surgical management of early massive edema caused by cerebral contusion in head trauma patients. *Acta. Neurochir. Suppl*. 2006; 96: 3-6.
11. Katayama Y, Kawamata T. Edema fluid accumulation within necrotic brain tissue as a cause of the mass effect of cerebral contusion in head trauma patients. *Acta. Neurochir. Suppl*. 2003; 86: 323-7.
12. Qiu BH, Qi ST, Zeng H, Mo YP, Yu L, Xu SX. Operative strategies for bilateral brain contusion and laceration. *Zhonghua Yi Xue Za Zhi*. 2013 Jun. 18; 93 (23): 1791-4.
13. Kawamata T, Katayama Y. Cerebral contusion: a role model for lesion progression. *Prog. Brain Res*. 2007; 161: 235-41.
14. Ragaisis V. Brain contusion: morphology, pathogenesis and treatment. *Medicina*. 2002; 38 (3): 243-249.
15. Kim JJ, Gean AD. Imaging for the diagnosis and management of traumatic brain injury. *Neurotherapeutics*. January, 2011; 8: 39-53.
16. Lobato RD, Alen JF, Perez-Nuñez A, Alday R, Gómez PA, Pascual B, et al. Value of serial CT scanning and intracranial pressure monitoring for detecting new intracranial mass effect in severe head injury patients showing lesions type I-II in the initial CT scan. *Neurocirugia (Astur)*. Jun. 2005; 16 (3): 217-234.
17. Eghwudjakpor PO, Allison AB. Decompressive craniectomy following brain injury: factors important to patient outcome. *Libyan. J. Med*. 2010; 5: 4620.
18. Polin RS, Ayad M, Jane JA. Decompressive craniectomy in pediatric patients. *Crit. Care*, 2003; 7 (6): 409-410.
19. Sinha S, Rathore YS, Mahapatra AK, Sharma BS. Surgical outcome of brain contusions treated by decompressive craniotomy with or without lobectomy at high volume tertiary care trauma centre. *Indian J Neurotrauma*. Jun. 2014; 11 (1): 5-9.
20. Akyuz M, Ucar T, Acibas C, Kazan S, Yilmaz M, Tuncer R. Effect of early bilateral decompressive craniectomy on outcome for severe traumatic brain injury. *Turkish Neurosurgery*, 2010; 20 (3): 382-389.
21. Binghui QIU, Shuxiang XU, Luxiong FANG, Silky Chotal, Weiguang LI, Songtao QI. Surgical strategies for neurological function preservation in severe brain contusion. *Turkish Neurosurgery*, 2012; 22 (3): 329-335.
22. Aarabi B, Hesdorffer DC, Simard JM, Ahn ES, Aresco C, Eisenberg HM, et al. Comparative study of decompressive craniectomy after mass lesion evacuation in severe head injury. *Neurosurgery*, 2009 May; 64 (5): 927-39; discussion 939-40.
23. Aarabi B, Hesdorffer DC, Ahn ES, Aresco C, Scalea TM, Eisenberg HM. Outcome following decompressive craniectomy for malignant swelling due to severe head injury. *J. Neurosurg*. 2006 Apr; 104 (4): 469-79.
24. Ahmadi SA, Meier U, Lemcke J. Detailed long-term outcome analysis after decompressive craniectomy for severe traumatic brain injury. *Brain Inj*. 2010; 24 (13-14): 1539-49.
25. Tjahjadi M, Arifin MZ, Gill AS, Faried A. Early mortality predictor of severe traumatic brain injury: A single center study of prognostic variables based on admission characteristics. *Indian J. Neurotrauma*. Jun. 2013; 10 (1): 3-8.
26. Ghalige HS, Karthik K, Rathod SS, Rangaswamy R, Khairnoor A, Thingujam D, et al. Factors predicting outcome of traumatic brain injury: A study from Manipur.



- Aug. 2014; 4 (1): 1790-1793.
27. De Silva MJ, Roberts I, Perel P, Edwards P, Kenward MG, Fernandes J, et al. Patient outcome after traumatic brain injury in high-, middle- and low-income countries: analysis of data on 8927 patients in 46 countries. *Int. J. Epidemiol.* 2009; 38: 452–458.
28. Saini NS, Rampal V, Dewan Y, Grewal SS. Factors predicting outcome in patients with severe head injury: Multivariate analysis. *Indian J Neurotrauma.* Jun. 2012; 9 (1): 45-48.
29. Ban SP, Son YJ, Yang HJ, Chung YS, Lee SH, Han DH. Analysis of complications following decompressive craniectomy for traumatic brain injury. *J Korean Neurosurg. Soc.* 2010 Sep; 48 (3): 244-50.