

Effectiveness of Discectomy for Pain Control in Lumber Radiculopathy

NAEEM-UL-HAQ, MUHAMMAD ISHFAQ, RAMZAN HUSSAIN

Mumtaz Ali, Akram Ullah, Bakht Zar

Department of Neurosurgery, Govt. Lady Reading Hospital, Peshawar

ABSTRACT

Objective: To know about the effectiveness of discectomy for pain control in lumber radiculopathy.

Material and Methods: This prospective observational study was conducted in Neurosurgery Department PGMI Lady reading Hospital Peshawar from May 2013 to April 2014. All patients admitted with Lumber radiculopathy and undergone discectomy for it were included in the study “while excluding myelopathy” and recurrent lumber radiculopathy. Patients age, gender, level of radiculopathy, pre operative symptoms, post operative improvement and deterioration in pain based on visual analogue scale were recorded on a designed Proforma. Patients were followed post-operatively for a minimum of 6 months. Data was entered and analyzed using SPSS version 17 and expressed in the form of tables and charts.

Results: Total 84 patients were include in this study in which males were 51 (60.7%) and females 33 (39.3%). Based on levels of lumber radiculopathy $L_2 - L_3$ cases were 1 (1.2%), $L_3 - L_4$ 3 (3.6%), $L_4 - L_5$ 31 (36.9) and $L_5 - S_1$ 49 (58.3%), Regarding age of the patients majority of the patients were in 3rd Dec. 23 (27.4%) and 4th Dec. 37 (44.0%) while 5th Dec. 20 (23.8%) and above 5th Dec. were 4 (4.8%). While pre operative low back-ache associated with lower limb pain corresponding to the radiculopathy was present in all patients (100%). Post operatively back pain was relieved in 72 (85.71%) and leg pain in 82 (97.61%) cases while back ache and leg pain were not relieved in 12 (14.29%), 2 (2.29%) successively (at the end of 6 months).

Conclusion: Lumber radiculopathy due to prolapsed intervertebral disc occurs most commonly at L_{4-5} , $L_5 - S_1$ in young to middle age peoples and discectomy is cost effective and safe procedure for it if done by experienced hands.

Key Words: L_{4-5} and $L_5 - S_1$ prolapsed intervertebral disc, radiculopathy, discectomy.

INTRODUCTION

Low back pain is a very common entity in clinical practice and it is second most common cause of seeking medical attention. In patients of age < 45 years it is the most common cause of disability and 15% absences and leave from official work occurs due to this reason. Its annual incidence is 5% and life time prevalence ranges from 60 – 95%. In patients of low back pain only 1% presents with nerve root symptoms in which up to 3% occurs due to lumber disc herniation.^{1,2,3,5} Etiology of intervertebral disc prolapse is multifactorial consisting of heavy weight lifting usually greater

than 25 pounds, activities involving whole body vibration like driving of motor vehicle and cigarette smoking etc.⁴ The pathophysiology of lumber radiculopathy due to prolapsed intervertebral disc is not 100% clear. It is mentioned in literature that it is not only due to the mechanical compression but also due to chemical irritation and edema of the nerve root.^{6,7} The natural history of prolapsed intervertebral disc is that first it prolapses then inflammatory changes occurs in it which leads to reabsorption and fibrosis of prolapsed disc material which ends in shrinkage and retraction resulting in relieving the symptoms of radiculopathy.⁶

Lumbar radiculopathy which is also known as sciatica was first described by Mixter in 1934 is characterized by low back pain with radiation of more intense pain to the lower limbs having dermatomal distribution of numbness, paraesthesia, and / or muscle weakness due to compression or irritation of nerve roots originating from lumbar spinal cord. Clinical examination is performed to confirm or refute the diagnosis of nerve root impingement the most important of which is straight leg raising test in addition to check tendon reflexes, motor deficit and sensory deficit.^{5,7-12} Radio-graphically lumbar radiculopathy is diagnosed by MRI and CT scan of lumbosacral spine with myelography. CT scan gives more information about bones while MRI is superior for visualization of soft tissues like spinal cord, nerve roots and soft tissues around vertebral bodies in addition to view the pathology from different direction due to multiplanar ability.

Management of lumbar radiculopathy is done by conservative and surgical methods. Conservative method is provided in the form of either alone or in combination of activity modifications, physiotherapy, progressive exercise, non-steroidal anti-inflammatory drugs, spinal injections and radiofrequency ablation therapy for total 3 months duration. Indications for surgical decompression are if the patient remains symptomatic in spite of 3 months conservative treatment or there is progressive neurologic deficit or development of cauda equine syndrome. The surgical decompression of lumbar spine root is done.⁷ Surgical decompression in the form of discectomy is regarded as impressive and cost effective treatment because it provides immediate pain relief and psychological satisfaction.¹⁵ After the surgery for lumbar radiculopathy some patients in spite of improvement continuously complain for low back-ache with or without radicular pain which is called failed back syndrome and ranges in frequency of 8 – 25%.^{16,17}

Rationale; – Lumbar radiculopathy due to prolapsed intervertebral disc is a common entity presenting to neurosurgeons in our setup because majority of the people of our society are manual workers and laborers. Conservative treatment for it fails in most of the cases due to less community education and compliance problems. Doing this study will help us to compare the results of discectomy for lumbar radiculopathy with both local and international studies and will show us the pros and cons of our technique and treatment protocols and this will be a step for patient betterment.

MATERIAL AND METHODS

This prospective observational study was carried out on 84 patients who had lumbar radiculopathy due to prolapsed intervertebral disc, conducted in Neurosurgery Department of PGMI, Lady Reading Hospital Peshawar from June 2013 to May 2014 with total 1 year duration. Patients having age $\geq 3^{\text{rd}}$ decade with either gender having lumbar radiculopathy due to prolapsed intervertebral disc who underwent lumbar discectomy were included in this study, while patients having lumbar radiculopathy who were managed conservatively, recurrent lumbar prolapsed intervertebral disc with radiculopathy and myelopathy were excluded from the study. All the data was collected and analyzed by descriptive statistics using software SPSS version 17 and represented in the form of graphs and charts.

All the patients were undergone through thorough history, detailed clinical examination and relevant investigations including MRI of the lumbosacral spine. All patients were managed in the ward before the surgery by providing sufficient analgesia.

Before surgical intervention patients were subjected to pre-operative preparation, like complete blood count (CBC) and viral serology (HbsAg and Anti-HCV Ab) and surgical disposables were arranged accordingly. An informed consent was taken, explaining the prognosis. The ethical approval was taken from the hospital ethical committee, "Postgraduate Medical Institute, Institutional Research and Ethics board". Then post operative effectiveness of discectomy for pain control in lumbar radiculopathy was revived by applying visual analogue scale to all patients till six months of follow up post operatively.

RESULTS

Total 84 patients were included in this study in which Males were 51 (60.7%) and Females were 33 (39.29%) (Fig. 1) while according to the age majority of the patients were in 3rd – 4th decades having frequency of 60 (71.4%) and remaining 24 (28.6%) were in 5th or above the 5th decades (Fig. 2). Lower levels of lumbar spine were effected more than upper levels and L₅ – S₁ was on the top having 49 (58.33%) followed by L₄₋₅ 31 (36.90%) and remaining 4 (4.76%) cases were involving L₂ to L₄ (Fig. 3). All the patients were subjected to MRI of lumbosacral spine pre-operatively and when needed post operative MRI of lumbosacral spine was also done in case of failed back syndrome Fig. 4 (pre op MRI of a case).

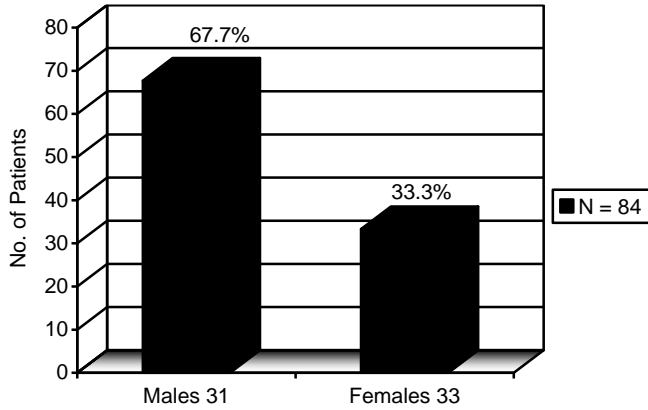


Fig. 1: Distribution of patients according to the gender (n = 84).

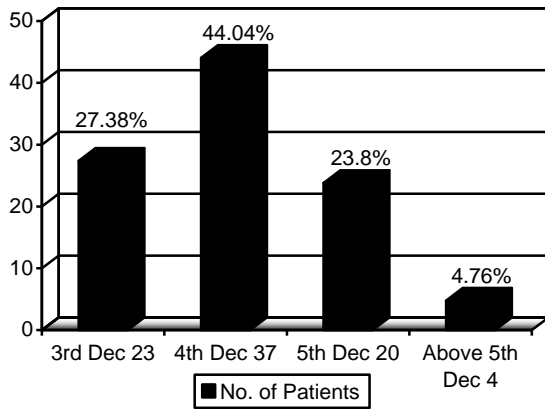


Fig. 2: Age wise distribution of patients (n = 84).

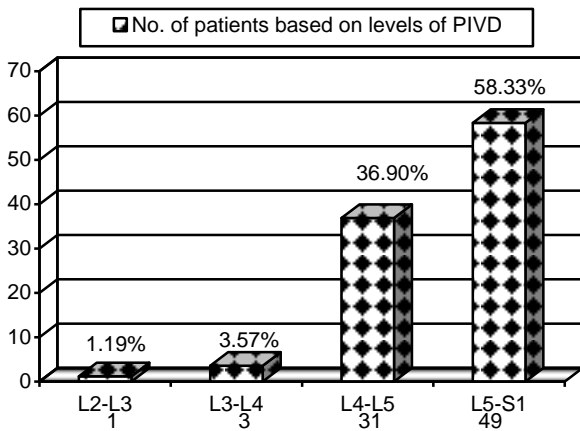


Fig. 3: Level of PIVD causing lumbar radiculopathy (n = 84).

Regarding post operative outcome in terms of pain relief according to visual analogue scale it 82

(97.61%) in legs and 72 (85.71%) in back while leg pain was not relieved in 2 (2.39%) and back pain in 12 (14.29%) cases (Fig. 4).

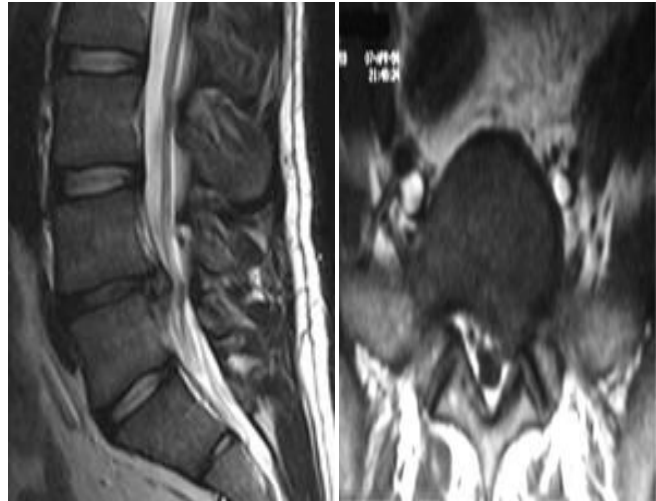


Fig. 4: Pro-operative MRI of a patient showing L₄₋₅ prolapsed intervertebral disc sagittal / Para sagittal view and compression of left side nerve root axial view.

DICUSSION

Lumbar radiculopathy is a common entity which presents to neurosurgeons in their clinical practice most frequently. The natural history of prolapsed intervertebral disc shows that first it prolapse followed by fibrosis leading to improvement in symptomology. Although patients are managed conservatively first by various methods to decrease the misery and improve the quality of life due to pain but still some patients inspite of all, progress for which surgical decompression is most effective way to relieve the pain and misery of the patient.¹⁸ When results of our study were compared to both local and international studies both resemblance and variation were present because the demographic features of the disease and clinical outcome of a procedure depends upon the environment, level of education of peoples, availability of health care facilities and level of expertise doing the procedure vary from region to region in the world.

In our study the patients were from 3rd to above the 5th decades while in Majeed et al²² patients presented with age range of 2nd – above the 5th decades. There is slight difference in the age ranges is due to the fact that in our society majority of the peoples are uneducated and mostly present late with diseases

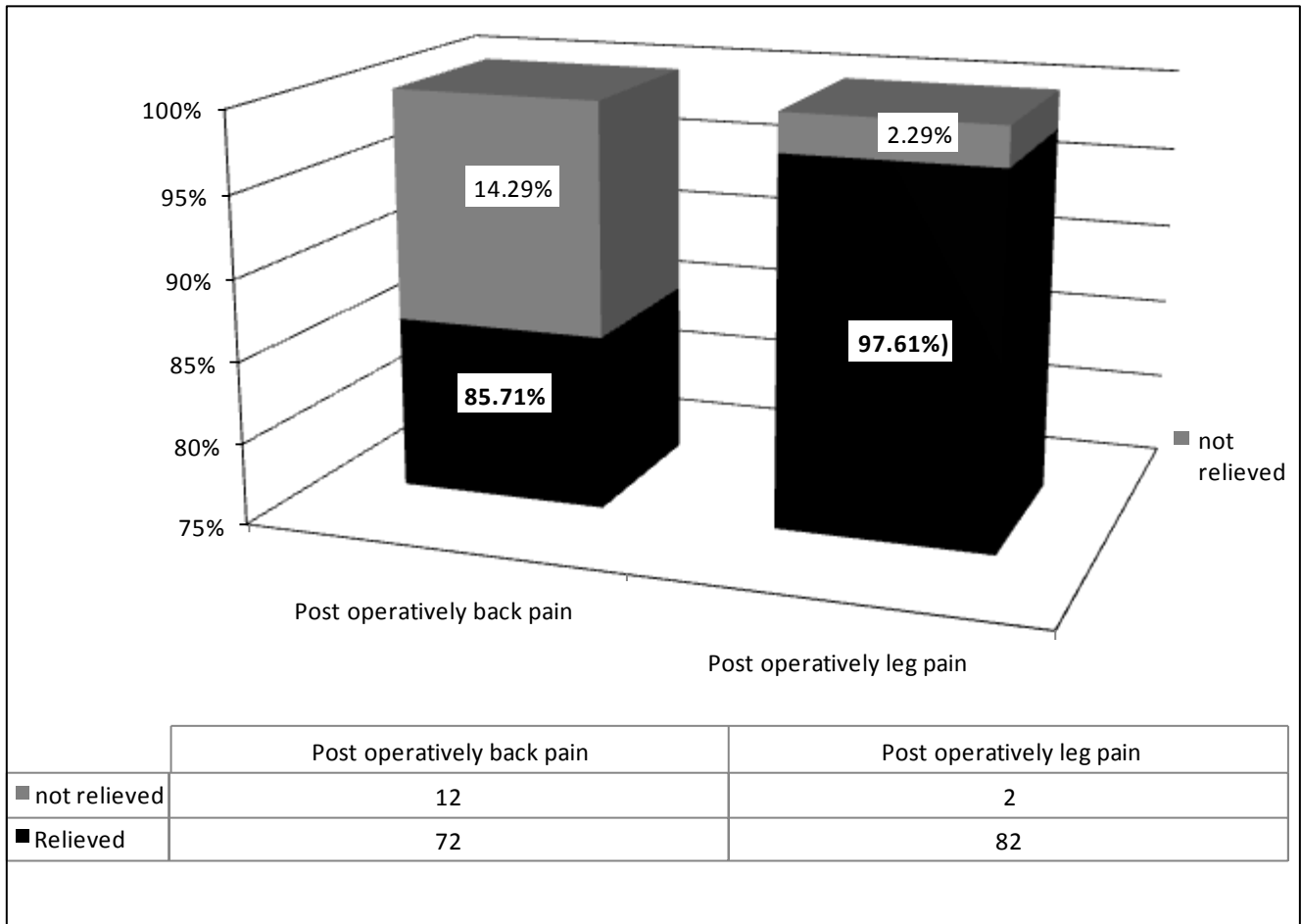


Fig. 5: Post-operative Outcome of Patients in Terms of Pain (n = 84).

as compared to western population where awareness about diseases is more and peoples mostly present early to the health care providers. Males were predominantly effected than females having frequency of 51 (67.7%) and females were 33 (38.3%) with male; female was 1.54:1 while Yoshito and colleagues²¹ has also showed in their study that males are predominantly effected than female. In their study male to females ratio was 1.76:1 which is slightly more than our study the main reason behind it is that their sample size of study was slightly greater than our study. Pro-lapsed intervertebral disc and associated radiculopathy was most common at lower levels of lumbar spine involving L₄₋₅ and L₅ – S₁ having frequency of 80 (92.23%) with greater frequency at L₅ – S₁ in our study while according to Sasani and colleagues²³ also the most common level of involvement was L₄₋₅, L₅ – S₁ having frequency of 100%. Similarly in other international studies^{24,25} the most common level of pro-

lapsed intervertebral disc was also L₅ – S₁. There is slight difference of percentages from Sisani and colleagues study because they collected all cases of far lateral discs herniation while in our study all types of lumbar intervertebral discs herniation were included.

When the patients were followed till to the 6 months post operatively and assessing them by visual analogue scale out of 84 patients back pain was relieved in 72 (85.71%) and leg pain in 82 (97.61%). Asch et al²⁰ conducted a study on 212 patients for post operative outcome of discectomy in lumbar radiculopathy in 2002 with total 2 years follow up and leg pain relief according to a visual analog scale (VAS) was 80% while back pain relief (VAS) was 77% this may be because of their long study duration, more sample size and follow up for greater duration. In another study²⁶ post operative leg pain relief was 96% which is comparable to ours one. Similarly Lew and colleagues²⁷ documented post-operative leg pain relief in 90%

cases after transforaminal percutaneous endoscopic discectomy in the treatment of far-lateral and foraminal lumbar disc herniations in which success rate is slightly lower than our one this is because endoscopic technique needs slightly more experience than open technique Post operatively back pain was not relieved in 12 (14.29%) cases while leg pain in 2 (2.29%) cases in our study. The frequency of failed back syndrome after lumbar discectomy for radiculopathy is variable in literature. Martin et al³⁰ has documented the frequency of failed back syndrome up to 19% in their study to which our results are comparable. In other international studies like^{28,29} it is 28%, 9%. This difference in frequencies from our study is due to the reason that outcome of lumbar discectomy depends upon many factors like the accuracy of initial diagnosis, level of surgeon experience, permanent injury of nerve root from original disc herniation, inflammatory conditions which can vary from set up to set up throughout the world.

CONCLUSION

Lumbar radiculopathy due to prolapsed intervertebral disc is common entity presenting to neurosurgeons in day to day clinical practice. It affects lower levels of lumbar spine and young to middle age population. Lumbar discectomy provides immediate pain relief and psychological satisfaction if performed by experienced hands making it a safe and cost effective procedure.

Address for Correspondence:

Dr. Muhammad Ishfaq

Department of Neurosurgery

Govt. Lady Reading Hospital, Peshawar

E-mail: Ishfaqtk83@gmail.com

REFERENCES

1. Cypress B K. characteristics of physician visits for back symptoms: A national perspective. *Am J Public Health*, 1983; 73: 389-95.
2. Cunningham L S, Kelsey J L: Epidemiology of musculoskeletal impairments and associated disability. *Am J Public Health*, 1984; 74 (8): 574-9.
3. Frymoyer J W: Back pain and sciatica. *N Engl J Med*. 1988; 318 (7): 291-300.
4. Kelsey JL, Golden AL, Mundt DJ. Low back pain / prolapsed lumbar intervertebral disc. *Rheum Dis Clin North Am*. 1990; 6 (3): 699-716.
5. Yasir Shehzad, Ashraf Mehmood, Nadeem Akhtar, Mohammad Arif Malik. Leg pain relief after fenestration and microdiscectomy in patients having sciatica due to lumbar intervertebral disc prolapse. *JRMC*. 2012; 16 (2): 123-5.
6. Sabuncuolu H, Ozdogan S, Timurkaynak E. Spontaneous regression of extruded lumbar disc herniation: report of two illustrative case and review of the literature. *Turkish Neurosurgery*, 2008; 18 (4): 392-6.
7. Mystery M, Dipak A, Vishal R, Chaudhari LH, Thakkar A. Effectiveness of root block and radiofrequency in prolapsed intervertebral disc and lumbar canal stenosis. *Indian J. Sci. Res*. 2013; 4 (2): 205-9.
8. Masters S, Lind R: Musculoskeletal pain – presentations to general practice. *Aust Fam Physician*, 2010; 39 (5): 425-8.
9. Waddell G, Main CJ, Morris EW, Venner RM, Rae PS, Sharmy SH, et al. Normality and reliability in the clinical assessment of backache. *Can Fam Physician*, 1990; 36 (2): 1173–7.
10. Janardhana AP, Rajagopal, Rao S, Kamath A: Correlation between clinical features and magnetic resonance imaging findings in lumbar disc prolapse. *Indian J Orthop*. 2010; 44: 263-9.
11. Cannon DE, Dillingham TR, Miao H, Andary MT, Pezzin LE: Musculoskeletal disorders in referrals for suspected lumbosacral radiculopathy. *Am J Phys Med Rehabil*. 2007; 86: 957-61.
12. Vroomen PC, de Krom MC, Wilmink JT, Kester AD, Knottnerus JA. Diagnostic value of history and physical examination in patients suspected of lumbosacral nerve root compression. *J Neurol Neurosurg Psychiatry*, 2002; 72 (5): 630–4.
13. Gregory DS, Seto CK, Wortley GC, Shugarat CM. Acute lumbar disk pain: navigating evaluation and treatment choices. *Am Fam Physician*, 2008; 78 (7): 835-42.
14. Tanitame K, Tanitame N, Tani C, Ishikawa M, Takasu M, Date S, et al. Evaluation of lumbar nerve root compression using thin – slice thickness coronal magnetic resonance imaging: three – dimensional fat – suppressed multi-shot balanced non-steady – state free precession versus three – dimensional T₁ – weighted spoiled gradient – recalled echo. *Jpn J Radial*. 2011; 29 (9): 623-9.
15. Voorhies RM, Jiang X, Thomas N. Predicting outcome in the surgical treatment of lumbar radiculopathy using the Pain Drawing Score, McGill Short Form Pain Questionnaire, and risk factors including psychosocial issues and axial joint pain. *The Spine Journal*, 2007; 7 (5): 516–24.
16. Anderson SR. A rationale for the treatment algorithm of failed back surgery syndrome. *Curr Rev Pain*, 2000; 4 (5): 395-406.
17. Ross J S, Robertson J T, Frederickson RCA, et al.: Association between peridural scar and recurrent redi-

- cular pain after lumbar discectomy: Magnetic resonance evaluation. *Neurosurgery*, 1996; 38: 855-63.
18. Cytevala C, Fescqueta N, Thomasb E, Decoux E, Blotmanb F, Taourela P. Predictive Factors of Efficacy of Periradicular Corticosteroid Injections for Lumbar Radiculopathy. *American Neuroradia J*. 2005; 8 (3): 375-8.
 19. GL, Jaffray DC, Cassar PVN. Observations on the natural history of massive lumbar disc herniation. *Bone Joint J*. 2007; 9 (3): 324-7.
 20. Asch HL, Lewis PJ, Moreland DB, Egnatchik JG, Yu YJ, Clabeaux DE, et al. Prospective multiple outcomes study of outpatient lumbar microdiscectomy: should 75 to 80% success rates be the norm. *J Neurosurg*. 2002; 96 (1): 34-44.
 21. Yoshito K, Yukihiro M, Hisatake Y, Yoshihito S, Hiroshi N, Shojiro N, et al. Comparison of Surgical outcomes between macro discectomy and micro discectomy for lumbar disc herniation: A prospective randomized study with surgery performed by the same spine surgeon. *J Spinal Disord Tech*. 2006; 19 (5): 344-7.
 22. Majeed SA, Vikraman CS, Mathew VSAT. Comparison of outcomes between conventional lumbar fenestration discectomy and minimally invasive lumbar discectomy; an observational study with a minimum 2 – years follow up. *J Orhtop Surg Res*. 2013; 24: 8-34.
 23. Sasani M, Ozer AF, Oktenoglu T, Canbulat N, Sarioglu AC. Percutaneous endoscopic discectomy for far lateral lumbar disc herniations: prospective study and outcome of 66 patients. *Minim Invasive Neurosurg*. 2007; 50 (2): 91-7.
 24. Ong A, Anderson J, Roche J. A pilot study of the prevalence of lumbar disc degeneration in elite athletes with lower back pain at the Sydney 2000 Olympic Games. *Br J Sports Med*. 2003; 37: 263-6.
 25. Stadnik TW, Lee RR, Coen HL, et al. Annular tears and disk herniation: prevalence and contrast enhancement on MR images in the absence of low back pain or sciatica. *Neuroradiology*, 1998; 206: 49–55.
 26. Sebastian R, Martin K, Georgios G. An Extreme Lateral Access for the Surgery of Lumbar Disc Herniations Inside the Spinal Canal Using the Full-Endoscopic Uniportal Transforaminal Approach – Technique and Prospective Results of 463 Patients. *Spine*. 2005; 30 (22): 2570-8.
 27. Lew SM, Mehalic TF, Kristin L, Fagone RN. Transforaminal percutaneous endoscopic discectomy in the treatment of far – lateral and foraminal lumbar disc herniations. *J Neurosurg*. 2001; 94 (2): 216-20.
 28. Law J D, Lehman RAW, Kirsch W M, et al. Re- operation after lumbar intervertebral disc surgery. *J Neurosurg*. 1978; 48: 259-63.
 29. Deyo RA, Ciol MA, Cherkin DC, Loeser JD, Bigos SJ. Lumbar spinal fusion. A cohort study of complications, reoperations, and resource use in the Medicare population. *Spine*, 1993; 18 (11): 1463-70.
 30. Martin BI, Mirza SK, Comstock BA, Gray DT, Kreuter W, Deyo RA. Reoperation rates following lumbar spine surgery and the influence of spinal fusion procedures. *Spine*, 2007; 32 (3): 287-382.