

# Serum Hormone Levels of Prolactin and Prolactin Content of Nonfunctioning Pituitary Adenomas and Normal Pituitary Glands

SABA KHALID, KHALID MAHMOOD, M. ARSLAN

*Tariq Salahuddin*

*Department of Physiology and Cell Biology, University of Health Sciences, Lahore*

*Department of Neurosurgery, PGMI / Lahore General Hospital, Lahore*

## **ABSTRACT:**

**Objective and Study Design:** Clinically nonfunctioning human pituitary adenomas (NFPAs) constitute about 25-35% of pituitary tumours. Relatively few studies have been carried out to determine the cellular origin and biology of the NFPAs. The present study was undertaken to assess the effect of surgical removal of adenoma on peripheral prolactin (PRL) hormone. In addition, the pituitary PRL hormone has also been measured directly in the adenoma tissue following its surgical removal and in the normal pituitary glands.

**Material and Methods:** The present study is based on 19 patients (16 males and 3 females), 30-50 year of age, diagnosed for NFPAs on the basis of clinical and radiological evidence. An equal number of age matched healthy subjects were included as controls. Prolactin hormone (PRL) was determined in serum before and following trans-sphenoidal adenomectomy. The PRL content of the excised adenoma tissue was also measured in male patients. All hormone determinations were carried out using commercially available immunoassay kits (ELISA and IRMA) in duplicate.

**Results:** The mean serum PRL concentration in male patients before removal of the adenoma were significantly higher ( $P < 0.05$ ) than values obtained after surgical removal of the adenoma and those of control subjects. In 5 of these 16 patients (PA1, PA10, PA14, PA28, PA30) serum PRL concentrations were markedly above the normal limit of circulating PRL levels ( $> 17.0$  ng/ml), the levels being ~ 2-fold of the mean control levels. The PRL levels returned to normal range following ablation of adenoma in these patients. The individual and mean serum PRL levels in the remaining 11 (68.75%) patients were in normal range before and after surgery. The mean PRL concentration of the adenoma tissue in the 5 patients with higher circulating presurgical levels of the hormone was significantly greater ( $P < 0.05$ ) than those of the rest of the patients with NFPAs and of the control pituitary tissue. The presurgical mean serum PRL concentration were significantly higher in 2 of the 3 female patients included in this study as compared to the control values and exceeded the normal range of PRL levels (1.2-19.5 ng/ml) described for healthy women. Following removal of adenoma, normal serum levels were attained. In the remaining one patient (PA4) serum PRL concentration was within the normal range before and following surgical removal of the adenoma.

**Conclusions:** Taken together, the present data suggest that a significant proportion of NFPAs may actively synthesize and secrete pituitary hormones such as PRL, in amounts that may not be sufficient to produce any overt clinical signs of hormone hypersecretion. The study also indicates the need of monitoring of hormone profile of patients with NFPAs before and after surgery, on an individual basis, for efficient case management.

**Key words:** PRL-secreting adenoma, Pituitary content, Non-secreting adenomas.

## **INTRODUCTION**

Pituitary tumours are abnormal growths on the pituitary gland that may secrete excessive amounts of

hormones and also in some instances, restrict the pituitary gland resulting in lower peripheral levels of hor-

mone secretion. In most cases, pituitary tumours remain confined to pituitary gland and the associated tissues. Since these tumours do not spread to other parts of the body, therefore, the term adenomas is generally used to designate these growths.<sup>1,2</sup>

Pituitary adenomas are usually well demarcated and are separated from the adjacent compressed non-tumorous adenohypophysis by a pseudocapsule that consists of condensed reticulin fibres.<sup>2,3</sup> These adenomas may be classified according to their size, radiographic appearance, endocrine function, morphology and cytogenesis. Clinicians frequently classify pituitary adenomas on the basis of their size as determined by imaging studies. Those smaller than 1 cm are designated as microadenomas and larger than 1 cm are categorized as macroadenomas. Microadenomas are also classified as grade 0 or grade 1 tumours. Macroadenomas that may also cause diffuse sellar enlargement, and extensive sellar destruction and erosion, are classified as grade 2-4.<sup>2,4</sup>

Partial or complete hypopituitarism has also been demonstrated in patients with large clinically non-functioning tumours because of compression of the adjacent normal pituitary tissue. Visual symptoms are found in 60-70% of cases and may be in the form of visual blurring, a loss of temporal field in one or both eyes and loss of visual acuity. Headache is observed in about 40% of patients and is often non-specific dull ache over vertex that does not vary with position or the time of the day.<sup>5,6</sup> There may also be other symptoms including loss of libido in men, amenorrhea, sexual disinterest, presence of smooth pale skin, and chronic fatigue. These clinical findings are supported by peripheral hormone levels that indicate significant pituitary insufficiency.<sup>7</sup>

More than 20% of all pituitary adenomas fall in the nonfunctional category, the predominant types being the 'null cell' adenomas or gonadotrope adenomas and 'silent' corticotrope adenomas<sup>8</sup>. Recent advances in immunoassay and immunocytochemical techniques have allowed a more specific characterization of the secretory activity of the non-functional pituitary adenomas (NFPAs). These nonfunctioning tumours invariably contain cytoplasmic secretory granules, suggesting that they do produce specific hormones, biologically inactive precursors, or hormone fragments. Some of these hormonally silent tumours are revealed by immunohistochemistry to contain hormones, but appear to be incapable of discharging these hormones in sufficient quantities to disturb the endocrine equilibrium.<sup>9,10</sup>

The classification of pituitary adenomas on the basis of their endocrine activity has considerable practical importance for both the clinical endocrinologists and the neurosurgeons. Based on physical examination and measurements of blood hormone levels in basal and provoked states, pituitary tumours can be broadly distinguished as being either functioning or nonfunctioning.<sup>10,11</sup> The former category comprises the pituitary tumours that produce growth hormone (GH), prolactin (PRL), adrenocorticotrophic hormone (ACTH), and thyroid stimulating hormone (TSH), which generate the clinical phenotypes respectively, of acromegaly, amenorrhoea-galactorrhea syndrome in women, decreased libido and impotence in men, Cushing's disease and hyperthyroidism.<sup>11</sup> Some pituitary adenomas co-secrete more than one hormonal product, and are designated plurihormonal pituitary adenomas. Tumours that hypersecrete the gonadotrophic hormones (LH and FSH) and / or glycoprotein hormonal subunits, generally do not generate a clinically recognizable endocrine syndrome and are, therefore, generally classified as nonfunctioning.<sup>12,13</sup>

More than 20% of all pituitary adenomas fall in the nonfunctional category, the predominant types being the 'null cell' adenomas or gonadotrope adenomas and 'silent' corticotrope adenomas.<sup>12-14</sup> Recent advances in immunoassay and immunocytochemical techniques have allowed a more specific characterization of the secretory activity of the non-functional pituitary adenomas (NFPAs). These nonfunctioning tumours invariably contain cytoplasmic secretory granules, suggesting that they do produce specific hormones, biologically inactive precursors, or hormone fragments. Some of these hormonally silent tumours are revealed by immunohistochemistry to contain hormones, but appear to be incapable of discharging these hormones in sufficient quantities to disturb the endocrine equilibrium.<sup>15</sup> Molecular techniques (*in situ* hybridization and Northern blot analysis) have confirmed that many NFPAs although incapable of producing measurable hormone elevations in the blood, do indeed transcribe the genes for other anterior pituitary hormones primarily for glycoprotein hormones and less often for other adenohypophyseal hormones.<sup>15,16</sup> The nonfunctioning status of these endocrine-inactive tumours has been further challenged by a variety of *in vitro* techniques. A number of tissue culture studies have confirmed that clinically diagnosed NFPAs are not constantly hormonally inert and are capable of low-level hormone release and many of these retain

responsiveness to a variety of stimulatory and suppressive agents.<sup>15,16</sup>

## OBJECTIVE

Few studies have been carried out to systematically assess the effect of removal of nonfunctional pituitary adenoma on peripheral adeno-hypophyseal hormones and the correlation of the serum levels with the hormone content of the adenoma tissue. The present study was, therefore, undertaken to determine serum PRL concentration in patients before and following removal of pituitary adenomas diagnosed presurgically, as nonfunctional. In addition we have measured hormone content of the adenoma tissues for a possible correlation with serum levels of PRL hormone.

## MATERIALS AND METHODS

### Study population

The present study initially included 22 patients 18 men and 4 women, of 22-55 ( $44 \pm 2.3$ ) years of age with NFPAs. Three of these patients 2 men and 1 woman died during the follow-up period and were excluded from the study. All patients underwent pituitary tumour surgery. The adenoma was removed in 18 patients through transsphenoidal route whereas in one female patient (PA 16) trans-cranial approach was used. All cases were operated at the Department of Neurosurgery, Lahore General Hospital, Lahore.

Patients with NFPAs were diagnosed on the basis of the following criteria:

- a) Presence of a sellar mass with or without extra-sellar extension detected by magnetic resonance imaging (MRI) or high resolution computed tomographic (CT) scans.
- b) Absence of signs or symptoms of functioning pituitary adenomas (Patients presenting with acromegaly, Cushing's disease and hyperthyroidism were not included in the study).
- c) Patients presenting signs and symptoms of a sellar mass such as headache and visual problems.
- d) Histological confirmation by light microscopy of pituitary tumour in the excised adenoma tissue.

The study also included 22 sex and age matched healthy subjects that served as the control group with 22-55 years of age. Subjects included in the control group had no medical history of any chronic disease and endocrinopathies, and were not on current or past medication of steroids, antipsychotropic and other medications known to affect pituitary hormone secretion. The subjects fulfilling inclusion criteria were

enrolled in the study after obtaining his/her written informed consent. The study was approved by the Ethical Committee and the Advanced Studies and Research Board of the University of Health Sciences, Lahore.

### Sample collection

Blood samples from patients with pituitary adenomas were obtained prior to surgery and 2 months after removal of the pituitary adenoma. Following surgery, patients received 10 mg prednisolone daily for 6 weeks. Postsurgical serum samples were obtained 2 weeks after the prednisolone treatment was discontinued. Blood samples were also obtained from an equal number of age and sex matched control subjects for purpose of comparison. Five ml of blood sample were drawn from each patient and blood was centrifuged at 3,000 rpm for 10-15 minutes to separate serum and aliquoted in two portions and stored at  $-30^{\circ}\text{C}$  until analyzed.

The pituitary adenoma tissue was divided into two parts. One part was fixed in buffered formalin and processed for histological examination, whereas the other half was weighed and homogenized in ice-cold phosphate buffer saline (PBS), at a dilution of approximately 50 mg/ml. The samples were centrifuged for 30 min at 10000 rpm and the supernatant was frozen at  $-30^{\circ}\text{C}$ . Pituitary tissue was also obtained from three adult males at the post-mortem examination, pooled and processed identically as the adenoma tissue for extraction.

### Tissue biology

Following fixation, adenoma tissue was processed for histopathological examinations. Paraffin sections of the tissue were cut at a thickness of 3-5 $\mu\text{m}$  and stained routinely with hematoxylin and counterstained with eosin.

### Hormone determinations

Serum PRL were determined by ELISA in duplicate using standard procedures with commercially available assay kits (PRL: Monobind Inc, Costa Mesa, CA, USA) with an automated EIA analyzer (Coda, Bio-Rad Laboratories, Hercules, CA, USA). Hormone content of adenoma and pituitary tissue, was measured with a specific radiometric assay in the extract obtained, by commercially available IRMA kits (IRMA; Immunotek, Prague, Czech Republic), with an automated gamma counter (Perkin Elmer, Turku, Finland).

**Statistical Analysis**

The significance of differences among different groups was analyzed by one way analysis of variance {ANOVA} followed by Duncan’s multiple t-test. P value of <0.05 was considered statistically significant. All calculations were carried out with the SPSS version 12 (SPSS Inc, Chicago, IL, USA).

**RESULTS**

**Prolactin (PRL)**

**Males**

The mean serum PRL concentration in male patients before removal of the adenoma were significantly

**Table 1:** Mean ± SEM serum PRL levels and PRL content of adenoma tissue, in male patients with NFPA and normal subjects.

Group	Serum PRL (ng/ml)	Adenoma tissue PRL content (ng/g)
Control subjects (n= 16)	5.8 ± 0.4	
Patients with pituitary adenoma (n=16)	2029 ± 768	
Pre-surgical	12.8 ± 2.6	
Post-surgical	7.0 ± 0.7*	
Pooled pituitary tissue		12190

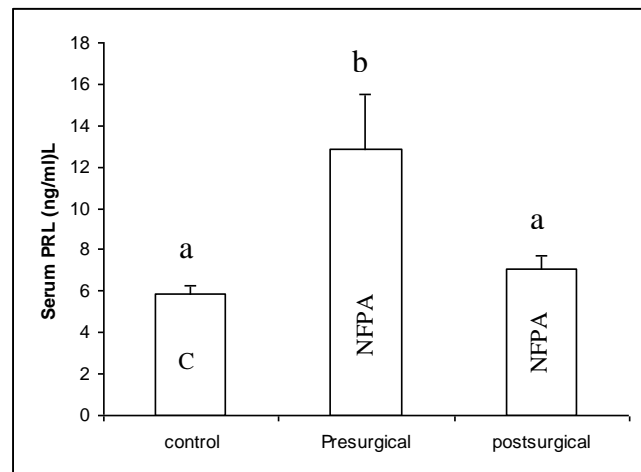
\*Significantly different from postsurgical and control value (P<0.05; ANOVA followed by Duncan’s t- test).

**Table 2:** Mean ± SEM serum PRL levels and PRL content of adenoma tissue, in male patients with NFPA and normal subjects.

Group	Serum PRL (ng/ml)	Adenoma tissue PRL content (ng/g)
<b>Males</b>		
Control Subjects (n=16)	5.8 ± 0.4	
Patients with pituitary adenoma		
(a) Subset I-with low or normal PRL levels (n=11)		748 ± 412
Presurgical	6.5 ± 1.2	
Postsurgical	7.0 ± 0.9	
(b) Subset II-with elevated PRL levels (n=05)		4846 ± 1805
Presurgical	26.6 ± 2.4*	
Postsurgical	7.0 ± 1.0	
Pooled pituitary tissue		12190

\*Significantly different from postsurgical and control value (P< 0.05; ANOVA followed by Duncan’s t- test).

higher (P<0.05) than values obtained after surgical removal of the adenoma and those of control subjects (Table 1 and Fig. 1). In 5 of these 16 patients (PA1, PA10, PA14, PA28, PA30) serum PRL concentrations were markedly above the normal limit of circulating PRL levels (>17.0 ng/ml), the levels being ~ 2-fold of the mean control levels as shown in Tables 2 and Fig. 2). The PRL levels returned to normal range following ablation of adenoma in these patients. The individual and mean serum PRL levels in the remaining 11 (68.75%) patients were in normal range before



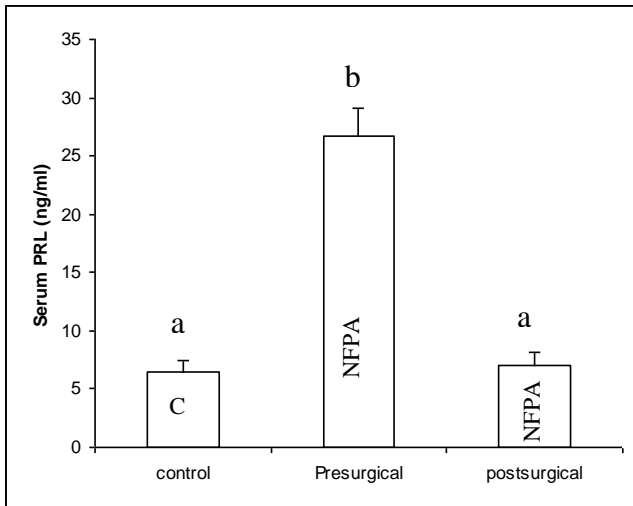
**Figure 1:** Mean ± SEM serum concentration of PRL (ng/ml) in 16 male patients with NFPA and age-matched control subjects. The values with different superscripts (a, b) are different from each other (P<0.05; ANOVA followed by Duncan’s t- test).

and after surgery (Tables 2, and Fig. 3). The mean PRL concentration of the adenoma tissue in the 5 patients with higher circulating presurgical levels of the hormone was significantly greater (P<0.05) than those of the rest of the patients with NFPA’s and of the control pituitary tissue.

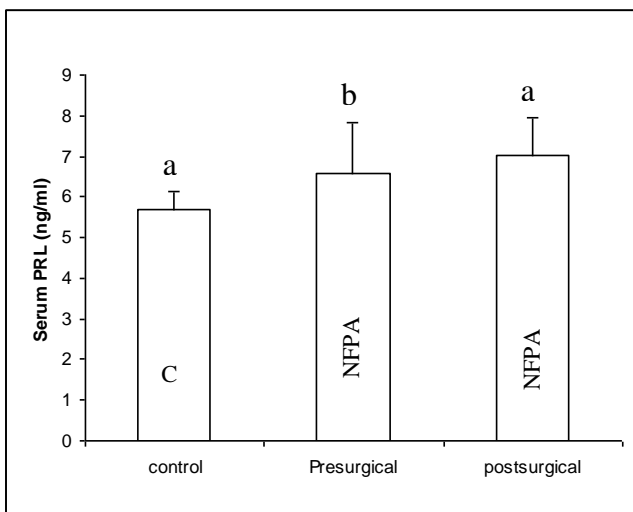
**Females**

The presurgical mean serum PRL concentration were significantly higher in 2 (PA 16, PA 19) of the 3 female patients included in this study as compared to the control val-

ues and exceeded the normal range of PRL levels (1.2-19.5 ng/ml) described for healthy women (Tables 4 and Fig. 5). Following removal of adenoma, normal serum levels were attained. In the remaining one patient (PA4) serum PRL concentration was within the normal range before and following surgical removal of the adenoma.



**Figure 2:** Mean  $\pm$  SEM serum concentration of PRL (ng/ml) in subset of 5 male patients with high pre-surgical serum PRL levels and age-matched control subjects. The values with different superscripts (a, b) are different from each other ( $P < 0.05$ ; ANOVA followed by Duncan's t-test).

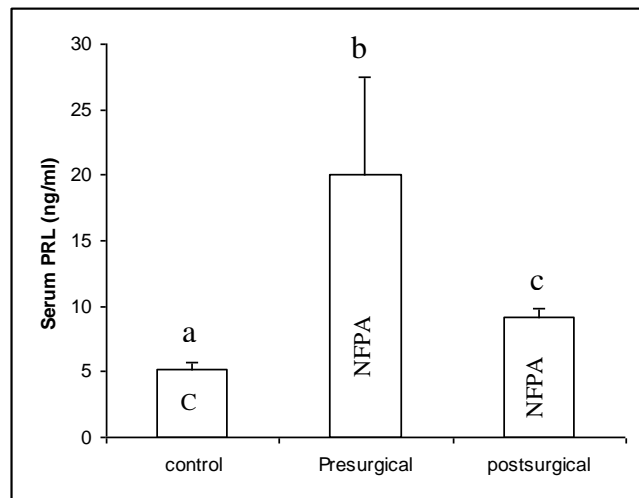


**Figure 3:** Mean  $\pm$  SEM serum concentration of PRL (ng/ml) in 11 male patients with NFPA and age-matched control subjects.

**Table 4:** Mean  $\pm$  SEM serum PRL levels and PRL content of adenoma tissue, in female patients with NFPA and normal subjects.

Group	Serum PRL (ng/ml)
<b>Females</b>	
Control Subjects (n=03)	5.1 $\pm$ 0.5
Patients with pituitary adenoma (n=03)	
Presurgical	20.0 $\pm$ 7.3*
Postsurgical	9.1 $\pm$ 0.6

\*Significantly different from postsurgical and control value ( $P < 0.05$ ; ANOVA followed by Duncan's t-test).



**Figure 5:** Mean  $\pm$  SEM serum concentration of PRL (ng/ml) in female patients with NFPA and age-matched control subjects. The values with different superscripts (a,b,c) are different from each other ( $P < 0.05$ ; ANOVA followed by Duncan's t-test).

## DISCUSSION

In the present study, we have attempted to assess the hormonal contribution of the pituitary adenomas diagnosed as nonfunctioning, by measuring pituitary hormones in serum before and after surgical removal of the tumour, and in the excised adenoma tissue. Previous literature indicates that NFPAs are morphologically heterogeneous and can be separated into two main categories based on immunohistochemical and electron microscopic appearances<sup>7</sup>. According to this classification one category of NFPAs 'null cell adenomas', includes tumours lacking characteristics of normal adenohypophyseal cells and possessing neither

morphological nor immunohistochemical markers indicating their cytotogenesis or direction of differentiation. The second group generally termed as 'silent adenomas', includes tumours exhibiting immunohistochemical and ultrastructural features of some of the recognizable adenohypophyseal cells but without any sign of hormone secretion. These 'silent' adenomas may possess adenohypophyseal cell types characteristic of normal adenohypophyseal tissue.<sup>7,11,12</sup> These adenomas have also been shown to express the messenger ribonucleic acid of the related hormone, indicating gene expression and synthesize one or more adenohypophyseal hormones as evidenced by immunocytochemistry.<sup>6,11</sup>

In some previous studies, NFPAs have been shown to secrete adenohypophysial hormones, most commonly PRL or GH.<sup>7,15</sup> Our study also demonstrates that presurgical serum PRL levels in 7 patients (37%) were significantly higher than those of control subjects and the levels returned to normal range following removal of the tumour. This elevation of PRL levels in these patients could also be attributed to hypothalamic pituitary impairment with large tumours. However, our suggestions that some of these adenomas may actively produce PRL is supported by the finding that the PRL content of the adenoma tissue in the subset of patients with supranormal PRL levels was significantly higher than those of the rest of the patients with NFPAs. The remaining patients with normal blood level of PRL also had low adenoma tissue PRL level.

The question why most of the NFPAs are clinically or biochemically silent, has not been resolved.<sup>4,12</sup> Some authors have insisted that silent adenomas may produce biologically inactive hormones, precursor proteins, or hormone fragments.<sup>6,12</sup> Others have suggested that the abnormalities may occur in exocytosis of hormone from the cell membrane so that despite normal biosynthesis, active secretion of the hormone does not take place.<sup>5,7,13</sup> Yamada et al<sup>5</sup> and Klibanski<sup>13</sup> are of the opinion that the amount of hormones discharged by the adenoma cells is lower than the normal range to produce any clinical findings, as only a few cells in the tumour are involved in hormone secretion.

## CONCLUSIONS

Taken together, the present data suggest that a significant proportion of NFPAs may actively synthesize and secrete pituitary hormones such as PRL, in amounts that may not be sufficient to produce any overt clinical

signs of hormone hypersecretion. The study also indicates the need of monitoring of hormone profile of patients with NFPAs before and after surgery, on an individual basis, for efficient case management.

*Correspondence Address:*

*Dr. Saba Khalid*

*Associate Professor*

*Head, Department of Physiology and Cell Biology*

*University of Health Sciences /*

*Lahore Medical & Dental College, Lahore*

*E-mail: sabakhalid@yahoo.co.uk*

## REFERENCES

1. Melmed S, Kleinberg D. Anterior Pituitary. In: Larsen PR, Kronenberg HM, Melmed S, Prolonsky KS (eds). Williams Textbook of Endocrinology 2003; PP 117-279. Saunders, Philadelphia, PA.
2. Thapar K, Kovacs K, Horvath E, Asa S. Classification and pathology of pituitary tumours. In: Wilkins R, Rengachary S (eds). Neurosurgery second edition, vol: 1; PP 1273-1283. McGraw-Hill companies, USA.
3. Chanson P, Brochier S. Non-functioning pituitary adenomas. J Endocrinol Invest 2005; 28: 93-99.
4. Ezzat S, Asa SL, Couldwell WT, Barr CE, Dodge WE, Vance ML et al. The prevalence of pituitary adenomas. Cancer 2004; 101: 613-619.
5. Yamada S, Kovacs K, Horvath E, Aiba T. Morphological study of clinically nonsecreting pituitary adenomas in patients under 40 years of age. J Neurosurg 1991; 75: 902-905.
6. Asa SL, Kovacs K. Clinically nonfunctioning human pituitary adenomas. J Neurol Sci 1992; 19: 228-235.
7. Kamitani H, Masuzawa H, Kanazawa I, Kubo T. The multihormonal character of pituitary adenomas: Immunoelectron microscopic studies. Neuropathology 1999; 19: 40-50.
8. Sanno N, Teramoto A, Osamura RY, Horvath E, Kovacs K, Lloyd RV, Scheithauer BW. Pathology of pituitary tumors. J Neurosurg Clin N Am 2003; 14: 25-39.
9. Katnelson L, Alexander JM, Klibanski A. Clinically nonfunctioning pituitary adenomas. J Clin Endocrinol Metab 1993; 76: 1089-1094.
10. Asa SL, Cheng Z, Ram yar L, Singer W, Kovacs K, Smyth HS et al. Human pituitary null cell adenomas and oncocytomas in vitro: effects of adenohypophysiotropic hormones and gonadal steroids on hormone secretion and tumour cell morphology. J Clin Endocrinol Metab 1992; 74: 1128-1134.
11. Horvath E, Kovacs K. Ultrastructural diagnosis of human pituitary adenomas. Microsc Res Tech. 1992; 20: 107-135.
12. Mahta A, Haghpanah V, Lashkari A, Heshmat R, Larijani B, Tavangar SM. Nonfunctioning pituitary ade-

- noma: immunohistochemical analysis of 85 cases. *Folia Neuropathol* 2007; 45: 72-77.
13. Klibanski A: Nonsecreting pituitary tumours. *Endocrinol Metab Clinic North Am* 1987; 16: 793-804.
  14. Black PM, Hsu DW, Klibanski A, Kliman B, Jameson JL, Ridgway EC, Hedley ET et al. Hormone production in clinically nonfunctioning pituitary adenomas. *J Neurosurgery* 1987; 66: 244-250.
  15. Kovacs K, Lloyd R, Horvath E, et al. Silent somatotroph adenomas of the human pituitary. A morphologic study of three cases including immunocytochemistry, electron microscopy, in vitro examination, and in situ hybridization. *Am J Pathol* 1989; 134: 345-353.
  16. Mukai K. Pituitary adenomas. Immunocytochemical study of 150 tumours with cliniconicopathologic correlation. *Cancer* 1983; 52: 648-653.