

## Management of Depressed Skull Fracture: A Study of 93 Cases

MUHAMMAD USMAN, MUMTAZ ALI

Department of Neurosurgery, Lady Reading Hospital, Peshawar

### ABSTRACT

**Objective:** To determine the correlation of skull fracture with dural tear in head injury patients presenting to a tertiary care hospital.

**Patients and Methods:** This study was carried out at Lady Reading Hospital Peshawar from January 2008 to December 2008. All patients who were operated for depressed skull fracture during this study period were included in the study. X-ray skull and CT scan brain were done for all patients; side and site of skull fracture were noted on imaging and during surgery. The incidence of dural tear associated with depressed skull fracture in various age groups and gender was noted. The results were analyzed using SPSS version 11.

**Results:** A total of 93 patients of depressed skull fracture were operated. There were 64 male and 29 female. Fall from the height was the main cause of trauma (61.3%). Most of the patients presented with moderate head injury. Dural injury was noted in 59.1% of the cases leading to neurodeficit in the form of hemiparesis/ hemiplegia in majority of cases. All patients were operated elevating the depressed fragments and dura repaired.

**Conclusion:** Dural injury is associated with morbidity in the form of hemiparesis / hemiplegia in patient having depressed skull fracture mainly at fronto-parietal region for which prompt surgical intervention and dural repair are the procedures of choice.

**Key Words:** Depressed skull fracture, head trauma, duroplasty.

### INTRODUCTION

Head injuries account for almost half of all deaths from trauma.<sup>1</sup> Approximately 2 million head injuries occur each year in the United States, producing a brain injury rate of 175 to 200 per 100,000 populations and causing as many as 56,000 deaths per year.<sup>2</sup>

The brain is surrounded by cerebrospinal fluid enclosed in meningeal covering and skull. Test results have shown that 10 times more force is required to fracture a cadaveric skull with overlying scalp than the one without. Although these layers have a protective role meningeal attachments to the interior of the skull may limit the movement of the brain transmitting shearing forces on the brain.<sup>3</sup>

Dural injury with associated underlying brain injury in patients with depressed skull fracture has been reported variously.<sup>4,5</sup> X-ray skull and CT scan head are valuable investigation tools for depressed skull fracture and associated brain injury.<sup>6</sup>

This study was carried out to determine the correlation of dural injury with depressed skull fracture in patients presenting to our unit.

### PATIENTS AND METHODS

This study was carried out at department of Neurosurgery government Lady Reading Hospital Peshawar from January 2008 to December 2008 on 93 consecutive surgically treated depressed skull fracture patients.

The following fractures were analyzed: age group, mechanism of injury, Glasgow coma scale, clinical and radiological findings, dural status preoperatively and finally the outcome. Standard antero-posterior and lateral X-rays were done in all cases. The X-ray findings were confirmed on CT scan of head.

The CT and preoperative findings were correlated with dural injury. The results were analyzed using SPSS version 11.

**RESULTS**

We operated a total of 93 patients of depressed skull fracture. The age range of the patients is as follow (Table 1).

Table 1:

Age	No of Cases	Percentage
< 1 Yr	1	1.07%
1 – 14	60	64.5%
15 – 45	27	29.03%
> 45	5	5.37%
Total Cases	93	100%

There were 64 (68.8%) male and 29 (31.2%) female patients.

Majority of the patients (55.9%) were from the urban while 44.1% patients were referred from northern hilly areas of the province.

Falls from height was the main cause of trauma (61.3%) followed by road traffic accidents (26.9%).

Physical assault causing depressed skull fracture was noted in 10.8% of the study population, 59.1% presented with moderate head injury (GCS Score of 9-12), 24.7% had mild head injury (GCS score of 13-15) and 16.1% had severe head injury (GCS Score of < 8), figure 1.

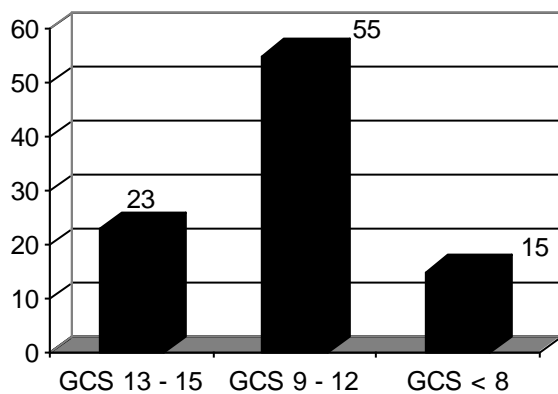


Figure 1:

Most cases (81.7%) showed no neurodefecit. Hemiparesis was observed in 14 (15.1%) and hemiplegia was noted in 3 (3.2%) patients.

Scalp laceration was present in most of the patients 90.3% while 9.7% of patients were having intact scalp.

Standard x-ray skull was obtained in all patients which showed fracture in 86 (92.5%) patients while 7 (7.5%) patients were having normal x-rays.

Right side was involved in 56 (60.2%) cases followed by left side in 37 (39.8%).

On CT scan of head with bone window fractal bone fracture was diagnosed in 34 (36.6%) cases followed by parietal bone 31 (33.3%). Other, in the order of decreasing frequencies included: combination of bones 18 (19.4%). Occipital 6(6.5%), temporal and vertex fracture each 2 (2.2%).

Pneumocephalus as an evidence of dural injury was observed in 35 (37.6%) on CT Brain, while majority of patients 58 (62.4%) showed no evidence of intracranial air accumulation. All patients underwent elevation of depressed fragments. Dura was found to be intact in 40.9%, deficient in 31.2% and torn in 28% of cases. Duroplasty was performed in 31 (33.3%), and repaired in 24 (25.8%) of cases. Mean hospital stay was 3 days.

**DISCUSSION**

Depressed skull fractures result from a high energy direct blow to a small surface area of the skull with a blunt object such as a baseball bat. Comminution of fragments starts from the point of maximum impact and spreads centrifugally. Most of the depressed fractures are over the fronto-parietal region because the bone is thin and the specific location is prone to an assailant’s attack. A free piece of bone should be depressed greater than the adjacent inner table of the skull to be of clinical significance and requiring elevation.<sup>3</sup>

The commonest age group in this study is the pediatric population which constituted 65.58% in agreement with previous studies done by Miller and Jannett in Glasgow and by Braakman in Rotterdam, we found that the pediatric population made up more than half of the study population.<sup>7-9</sup>

As in the present study vast majority of head injuries are experienced by young adult males ranging from 3 : 1 to as high as 11.1 : 1 in literature.<sup>10</sup> In our study male to female ratio was 3 : 1. This high vulnerability of male gender for all types of trauma can be attributed to the facts that in our society male have more freedom to work outdoor and engage in risk taking activities, making them more vulnerable to accidents and fall injuries.

Fall from the height was the main cause of trauma in our study (61.3%).

In a study alleged assault followed by Road Traffic Accidents (RTA) was the commonest cause of head trauma leading to depressed skull fractures.<sup>7</sup>

The clinical status of the patient concurrent neuro-  
rodeficit wound on scalp and dural injury are the main determinants of patient outcome. In our study majority of cases (59.1%) present with moderate head injury (GCS Score of 9-12), 18.3 having neurodeficit in the form of hemiparesis (15.1%) and hemiplegia (3.2%). This neurodeficit was noted in cases who were having dural injury per operatively. This is in agreement with an international study in which dural tear was associated with high morbidity and mortality.<sup>11</sup>

In Present study, frontal and parietal skull bone were involved in 36.6% and 33.3% of cases respectively, making a cumulative percent of 69.9%.

This is because the bones are more exposed to assault, falls and RTA, because these bones are thin and less protected by overlying self tissues. We found that the dural injury was also more severe in cases having fracture of frontal and parietal bones.

We performed duroplasty using a pericranial/temporalis fascia patch in 33.3% of cases while in those cases in which only a linear tear was found per-operatively (25.8%) we primarily repaired the dura.

Most of the patients showed good recovery and were discharged from the hospital on third post-operative day 92.5%.

## CONCLUSION

Dural injury is associated with morbidity in the form of hemiparesis/ hemiplegia in patient having depressed skull fracture mainly at fronto-parietal region for which prompt surgical intervention and dural repair are the procedures of choice.

*Address for Correspondence:*  
*Dr. Muhammad usman,*  
*Department of neurosurgery*  
*Govt. Lady Reading Hospital*  
*Peshawar, NWFP – Pakistan*  
*Cell No: 0333-4788921*

## REFERENCES

1. Khan IU, Nadeem M. There is high incidence of skull fracture associated with Extradural Hematoma in Patients with head injury. *Rawal Med J* 2008; 33: 228-230.
2. Kraus JF, MacArthur DL. Epidemiologic Aspects of Brain Injury. *Neurologic Clinics* 1996; 14 (2): 435-450
3. Qureshi N H, Harsh IV G. Skull Fracture. [Online] 2008. Available from <http://emedicine.medscape.com/article/248108-overview>
4. Oehmichen M, Auer RN, Konig HG. Forensic neuropathology and associated neurology. Google books 2009; page 478.
5. Ersahin Y, Mutluer S, Mirzai H, Palali I. Pediatric Depressed skull fractures: Analysis of 530 cases. *Child's neuro syst* 1996; 12: 323-331.
6. Khan AN, Turnbull I, MacDonald S. Skull, Fractures. 2007; [Online] Available from <http://emedicine.medscape.com/article/343764-overview>.
7. Kirolos R, Al-Haddad SA. A 5-year study of the outcome of surgically treated depressed skull fractures. *Ann R coll surg Engl* 2002; 84: 196-200.
8. Miller JD, Jennet B. Complications of depressed skull fractures. *Lancet* 1968; 2: 991.
9. Braakman R. Depressed skull fracture: data, treatment and follow up in 225 consecutive cases. *J Neurol Neurosurg Psychiatry* 1972; 32: 395-402.
10. Rajendra PB, MaHew TP, Agrawal A, Sab Harawal G. Characteristics of associated craniofacial trauma in patients with head injuries: An experience with 100 cases. *J emerg Trauma Shock*. 2009 May-Aug; 2 (2): 89-94.
11. Curry DJ, Frim DM. Delayed repair of open depressed skull fracture, pediatric neurosurgery 1999; 31: 294-7.