

## Effectiveness of Unilateral Approach for Bilateral Decompression in Lumbar Spinal Stenosis

IKRAM ALAM, WEFAQ ULLAH, MUHAMMAD IDRIS KHAN

*Mumtaz Ali*

*Department of Neurosurgery, Lady Reading Hospital, Peshawar*

### ABSTRACT

**Background:** Lumbar spinal stenosis is defined as “buttock or lower extremity pain, which may occur with or without low back pain, associated with diminished space available for the neural and vascular elements in the lumbar spine. Patients complain of neurogenic claudication that is compatible with a narrowing of the lumbar spinal canal. Conventional laminectomy is frequently associated with surgical failures, generally related to post-operative iatrogenic spinal instability. Other operative options that are less invasive, such as the bilateral laminotomy and, in particular, the unilateral laminotomy for bilateral decompression (ULBD), have been introduced during the past years.

**Objectives:** The objective of this study is to determine the effectiveness of unilateral approach for bilateral decompression in Lumbar spinal stenosis.

**Methods:** It was a Descriptive case series study conducted in the admitted patients of Lumbar spinal stenosis in the Department of Neurosurgery, Lady Reading Hospital, Peshawar, in six months duration. Total of 171 patients were enrolled in the study. Bilateral decompression through a unilateral approach was performed under general anesthesia by single expert neurosurgeon having a minimum of 5 years of experience. All the patients were followed up till 24 hours post operatively for the determination of effectiveness in terms of improvement in at least one grade of pain on visual analogue scale from baseline.

**Results:** In this study, 171 patients with Lumbar spinal stenosis were observed. Male to female ratio was 1.41:1. The study included age ranged from 40 to 78 years. Average age was 59.29 years  $\pm$  11.41 SD. Efficacy of unilateral approach for bilateral decompression in Lumbar spinal stenosis was found in 136 (79.53%).

**Conclusion:** Unilateral approach for bilateral decompression is the better option for the patients presenting with Lumbar spinal stenosis.

**Key Words:** Bilateral decompression, Lumbar spinal stenosis, Unilateral approach, Efficacy.

### INTRODUCTION

Pain radiating to lower extremities is a frequent complaint, especially in elderly people, and lumbar spinal stenosis is one of the underlying conditions. Lumbar spinal stenosis is defined as “buttock or lower extremity pain, which may occur with or without low back pain, associated with diminished space available for the neural and vascular elements in the lumbar spine”.<sup>1</sup> LSS due to degenerative changes start in the fifth and sixth decades of life. It is characterized by ligamentum

flavum hypertrophy, bulging of the intervertebral disc, and facet joint thickening with arthropathy, eventually leading to compression of the neural elements.<sup>2</sup>

Patients complain of neurogenic claudication (pain in the buttocks and lower extremities with or without low back pain provoked by walking or extended standing and relieved by rest and bending forward) that is compatible with a narrowing of the lumbar spinal canal.<sup>3</sup>

Because of the elderly age of the patients, LSS is

usually treated conservatively with medication, epidural steroid injections, lifestyle modification, and physiotherapy. Surgery is considered in those cases in which conservative treatment has failed to relieve pain and to improve function and typically consists of wide laminectomy.<sup>4</sup> The surgical aim of treatment for symptomatic lumbar canal stenosis is relief of symptoms by adequate neural decompression while preserving much of the anatomy and the biomechanical function of the lumbar spine.<sup>5</sup>

Conventional laminectomy is frequently associated with surgical failures, generally related to postoperative iatrogenic spinal instability.<sup>4</sup>

Other operative options that are less invasive, such as the bilateral laminotomy and, in particular, the unilateral laminotomy for bilateral decompression (ULBD), have been introduced during the past years.<sup>2</sup>

Bilateral decompression of lumbar spinal stenosis via a unilateral approach involves shorter operating times and less blood loss, less muscle dissection, fewer and less severe complications, and better mobility in the immediate postoperative period than open decompressive techniques.<sup>6</sup>

The unilateral approach preserves the facet joints and neural arch of the contralateral side, limits postoperative destabilization and protects the nervous structure against posterior scarring.<sup>5,7</sup>

The success rate of unilateral approach in cases of bilateral decompression mentioned by different studies is 68%,<sup>4</sup> and 85%,<sup>5,7</sup> 87%,<sup>4</sup> 88%,<sup>4</sup> 94%,<sup>5,7</sup>

The current study is designed to determine the effectiveness of unilateral approach for bilateral decompression of lumbar spinal stenosis. This study will generate local statistics about effectiveness of unilateral approach in our local population as the literature available showed controversial and differences in the effectiveness. The results of this study will be projected to other neurosurgeons and based upon results of this study we can make suggestions for necessary modifications in the routine management of patients with lumbar spinal stenosis.

## **MATERIAL AND METHODS**

A prospective study was performed in neurosurgery department lady reading hospital Peshawar from January 2014 to June 2014 (6 months). All patients with age 40 years and above who was having spinal stenosis with baseline pain moderate to severe on visual analogue scale were included in this study and all those patients who were having history of previous

back surgery, stenosis due to associated with other conditions like malignancy and spondylolisthesis were excluded from the study. All consecutive patients meeting the inclusion criteria with diagnosis of lumbar spinal stenosis i.e. MRI Lumbar spine showing trefoil appearance on axial views as a result of a bulging intervertebral disc ventrally, hypertrophied facet joints laterally and ligamentum flavum hypertrophy dorsally and having baseline pain grade of moderate or severe on visual analogue scale were enrolled in the study through outpatient department and were admitted to neurosurgery ward for further work up. All MRI were reported by a single expert radiologist who is fellow of CPSP.

The purpose and benefits of the study were explained to the patients and a written informed consent was obtained. All patients were subjected to detailed history followed by complete physical and neurological examinations and routine set of investigations were performed in all patients. The enrolled patients were put on the OT list for the next available OT day after performing anesthesia assessment through an expert anesthesiologist.

On the OT day bilateral decompression through a unilateral approach were performed under general anesthesia by single expert neurosurgeon having minimum of 5 years of experience. All the patients were followed up till 24 hours post operatively for the determination of effectiveness in terms of improvement in at least one grade of pain on visual analogue scale from baseline. All the above mentioned information including name, age, gender and address were recorded in a pre designed proforma. Strictly exclusion criteria were followed to control confounders and bias in the study results.

The data were entered, stored and analyzed in SPSS version 10. Mean  $\pm$  SD were calculated for quantitative variables like age and duration of symptoms. Frequencies and percentages were calculated for categorical variables like gender and effectiveness. Effectiveness was stratified among age, gender, duration of symptoms and pain at presentation to see the effect modification. All results were presented in the form of tables and graphs.

## **RESULTS**

In this study, 171 patients with Lumbar spinal stenosis were observed, in which 71 (41.52%) were female and 100 (58.48%) were male patients. Male to female ratio was 1.41:1 (Figure 1).

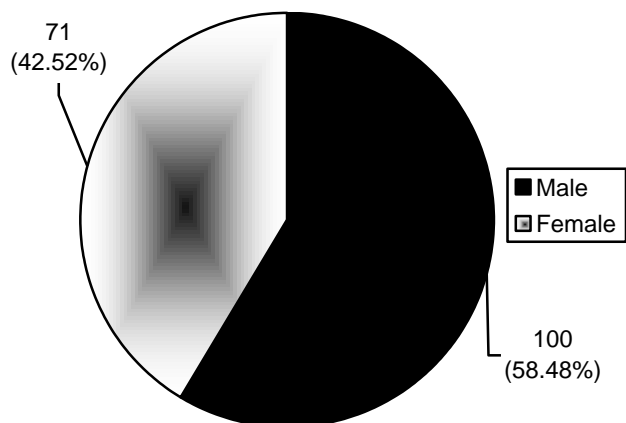


Figure 1: Gender Wise Distribution of the Patients.




Figure 2: Efficacy.

Patients age was divided in four categories, out of which most presented in age of 51 – 60 years which were 56 (32.7%) while 42 (24.6%) patients were in the age range of less than or equal to 50 years, 39 (22.8%) were of age range of 61 – 70 years and 34 (19.9%) patients have age more than 70 years. The study included age ranged from 40 to 78 years. Average age was 59.29 years ± 11.41 SD. (Table 1)

Table 1: Age Wise Distribution of the Patients.

	Frequency	Percent	Cumulative Percent
< = 50.00	42	24.6	24.6
51.00 – 60.00	56	32.7	57.3
61.00 – 70.00	39	22.8	80.1
71.00+	34	19.9	100.0
Total	171	100.0	

Efficacy of unilateral approach for bilateral decompression in Lumbar spinal stenosis was found in 136 (79.53%) while 35 (20.47%) patients show no efficacy (Figure 2).

Age wise distribution of efficacy shows that majority of the efficacy was in less than or equal to 50 years of age. i.e. 97.6%, age 51 – 60 years have 75% efficacy, patients having age 61 – 70 years shows 89.7% and age more than 70 years of age have very low efficacy 52.9% (Table 2).

Gender wise distribution of efficacy shows that

Table 2: Age Wise Distribution of Efficacy.

		Efficacy		Total
		Yes	No	
Age (in years)	< = 50.00	41	1	42
		97.6%	2.4%	100.0%
	51.00 – 60.00	42	14	56
		75.0%	25.0%	100.0%
61.00 – 70.00	35	4	39	
	89.7%	10.3%	100.0%	
71.00+	18	16	34	
	52.9%	47.1%	100.0%	
Total		136	35	171
		79.5%	20.5%	100.0%

gender have major role over equal efficacy. There were 95 (95%) male patients who showed efficacy while efficacy in female was observed in 41 (57.7%) patients (Table 3).

Symptoms wise distribution of efficacy shows that majority of the efficacy was not seen in patients having 41 and above weeks duration of symptoms which were in 16 (33.3%) patients, followed by 17.1% in less than or equal to 20 weeks duration of symptoms while in 21 – 40 weeks of duration of symptoms it was 5.6%. the average duration of symptoms was 22.7 ± 21.08 SD with rang of 3 to 61 weeks (Table 4).

**Table 3:** Gender Wise Distribution of Efficacy.

		Efficacy		Total
		Yes	No	
Gender	Male	95	5	100
		95.0%	5.0%	100.0%
	Female	41	30	71
		57.7%	42.3%	100.0%
Total		136	35	171
		79.5%	20.5%	100.0%

**Table 4:** Duration of Symptoms Wise Distribution of Efficacy.

		Efficacy		Total
		Yes	No	
Duration of symptoms (in weeks)	< = 20.00	87	18	105
		82.9%	17.1%	100.0%
	21.00 – 40.00	17	1	18
		94.4%	5.6%	100.0%
	41.00+	32	16	48
		66.7%	33.3%	100.0%
Total		136	35	171
		79.5%	20.5%	100.0%

## DISCUSSION

Several surgical techniques for lumbar spine decompression have been described over last few decades. The surgical aim of treatment for symptomatic lumbar canal stenosis is relief of symptoms by adequate neural decompression while preserving much of the anatomy and the biomechanical function of the lumbar spine. Traditional treatment of spinal stenosis has involved wide laminectomy and undercutting of the medial facet with foraminotomy. The frequent surgical failures have been attributed to local tissue trauma<sup>8,9</sup> and to postoperative spinal instability,<sup>10-15</sup> which has led to a dramatic increase in lumbar fusion surgery.<sup>16,17</sup> Turner's meta-analysis of 74 published studies of surgery

for lumbar spinal stenosis produced good to excellent results ranging from 26 to 100% (mean 64%).<sup>18</sup>

Although controversy still lies in the management of lumbar spinal stenosis, surgical decompression has been proven to be the safe and effective treatment option for patients suffering from the disabling symptoms of spinal stenosis.<sup>19-22</sup> However, due to age-related co-existing diseases, healthcare providers as well as patients and their family members are often concerned about surgery in the elderly group.<sup>23</sup> In this respect, applications of less invasive techniques are thought to be very important in the treatment of geriatric spinal stenosis.

We thought our results may be resulting from the only aged patient and the chronic co-morbidity of a systemic problem. A previous study demonstrated that the majority of patients, who underwent total laminectomy, respond well to laminectomy, but complication (22%) and late deterioration (10%) rates are not insignificant. In addition, radiological instability is common after decompression for degenerative lumbar spinal stenosis however, this correlates poorly with clinical outcome (9). The laminectomy with fusion for an osteoporotic patient carries the risk of operation-related problems as screw loosening, which may lead to the loss of correction and nonunion. Its rate ranged from 0.6 to 11% of the cases.<sup>24</sup> Most elderly patients, especially women, have osteoporosis and the prevalence increases with age. Osteoporosis is one of the most important parameters influencing the stability of the spine postoperatively.

There was no evidence of postoperative spinal instability in patients with osteoporosis in this study. In addition, a previous study demonstrated that appropriate surgical treatment for lumbar spinal stenosis may contribute to the prevention of physical inactivity-induced osteoporosis in elderly patients with neurogenic intermittent claudication caused by degenerative lumbar disease.<sup>25</sup>

Turner's meta-analysis of 74 published studies of surgery for lumbar spinal stenosis found good to excellent results ranging from 26 to 100% (mean 64%).<sup>26</sup> Many authors have challenged the traditional treatment of spinal stenosis in which wide laminectomy and partial or complete facetectomy was performed. Older techniques of laminectomy or unroofing of the spinal canal, while affording wide decompression, often resulted in destruction or insufficiency of the pars interarticularis or facet joints with resultant iatrogenic instability. From an extensive review of the literature, Turner et al<sup>26</sup> attempted a meta-analysis and

concluded that approximately 64% of surgically treated patients had a good outcome over a midterm follow-up period (3 – 6 years). In particular, spinal instability has been implicated as a cause of surgical failures,<sup>27-30</sup> because wide posterior decompression significantly alters spinal anatomy and biomechanics,<sup>30-32</sup> thus prompting many spine surgeons to perform fusion procedures to treat lumbar stenosis.<sup>33,34</sup>

The authors who performed unilateral laminotomy for bilateral decompression, demonstrated good results in 87% (26 of 30 patients)<sup>35</sup> at 9 months; 82% (18 of 22)<sup>36</sup> at 1 year; 88% (22 of 25)<sup>37</sup>, and 70% (in 28 of 40)<sup>38</sup> at 18 months; and 67,6% (in 23 of 34)<sup>39</sup> at 2 years; and 68% (in 15 of 22)<sup>36</sup> at 4 years in their studies. In fact, only a few patients really required additional lumbar instrumentation after surgical decompression because of progressive instability.<sup>25,35,38</sup> Most elderly patients, especially women, have osteoporosis and the prevalence increases with age. The laminectomy with fusion for an osteoporotic patient carries the risk of operation – related problems as screw loosening, which may lead to the loss of correction and non-union. Its rate ranged from 0.6 to 11% of the cases.<sup>40</sup> Considering that lumbar spinal stenosis often is a multi-segmental disease, stabilization procedures seemed to be also only a symptomatic and temporary treatment modality.

On the other hand extensive open decompression is associated with significant pain, prolonged hospitalization and recovery period, morbidity, and an increased incidence of medical complications. The most important event leading to the stress response is tissue trauma. Indeed, the greater the trauma, the greater the response.<sup>41</sup> Commonly used techniques of exposure for lumbar decompression that include elevation of the multifidus bilaterally with subsequent wide retraction have potentially serious consequences.

Mayer et al<sup>42</sup> demonstrated a decrease in paraspinal muscle strength with concomitant atrophy on postoperative computed tomography scans. See and Kraft<sup>43</sup> echoed these concerns in their observation of chronic denervation and electromyographic abnormalities of the paraspinal muscles 4 years after open surgery. Sihvonen et al<sup>44</sup> noted similar computed tomography and electromyographic abnormalities and correlated these with the postoperative failed back syndrome.

The described technique of microdecompression limits ipsilateral retraction to the level of the medial facet border. Contralaterally, no elevation or retraction of the paraspinal musculature is undertaken, thereby minimizing the risk of iatrogenic muscular trauma and

therefore prove to be an important tool in decreasing the risk of these undesirable sequelae.

Our intra and postoperative rate of complications was comparable to other surgical procedures,<sup>45-48</sup> and refutes the initial fear that dural sac and nerve roots were injured by using this unilateral approach. A single inadvertent dural tear occurred in the beginning of the series and was caused by too early resection of the ligamentum flavum before and adequate undermining of the spinous process had been achieved. The mean follow-up after 18 months demonstrated that all initial symptoms caused by direct compression or entrapment of neural structures such as paresis, sensory disturbances or neurogenic claudication were treated successfully. Similar to other experiences, low back pain a major complaint in patients with spinal stenosis was hard to influence.<sup>47,49-52</sup> Actually the majority of patients had clearly pain relief but only 28% were completely free of pain. The presence of postoperative low back pain is not unusual, since chronic low back pain is a multicausal and multiform syndrome. It is therefore unlikely that a single decompression procedure can be the global solution for this complex problem.<sup>50,53-55</sup>

Patients with radiologically proven spinal stenosis combined with intractable low back pain, but without neurological deficit and without neurogenic claudication form a common selected subgroup. However such patients were ruled out in this prospective study and were treated conservatively. In consideration of these arguments, we emphasize that a clear indication for the operative treatment in lumbar spinal stenosis is mandatory.

## CONCLUSION

Minimally invasive bilateral decompression of lumbar spinal stenosis from a unilateral approach can be successfully accomplished with reasonable operative time and acceptable morbidity. Unilateral approach for bilateral decompression has the advantages of avoiding postoperative spinal instability by preserving the contralateral facet joint and neural arch and substantial widening of the spinal canal. In addition, unilateral approach for lumbar spinal stenosis is a less invasive technique and leads to favorable results in elderly patients with co-morbid conditions.

*Address for Correspondence:*  
*Dr. Ikram Alam*

*Department of Neurosurgery, Lady Reading Hospital,  
Peshawar*

**REFERENCES**

1. Steurer J, Nydegger A, Held U, Brunner F, Hodler J, Porchet F et al. Lumb Sten: The lumbar spinal stenosis outcome study. *BMC Musculoskeletal Disorders*, 2010; 11: 254.
2. Hwang S, Rhim S, Roh S, Jeon S, Hyun S. Outcomes of Unilateral Approach for Bilateral Decompression of Lumbar Spinal Stenosis: Comparison between Younger and Geriatric Patients. *Kor J Spine*, 2008; 5 (2): 51-7.
3. Kalichman L, Cole R, Kim DH, Li L, Suri P, Guermazi A et al. Spinal stenosis prevalence and association with symptoms. The Framingham Study. *Spine J*. 2009; 9 (7): 545-50.
4. Costa F, Sassi M, Cardia A, Ortolina A, De Santis A, Luccarell G et al. *J Neurosurg Spine*, 2007; 7: 579-86.
5. Cavusoglu H, Turkmenoglu O, Kaya RA, Tuneer C, Colak I, Sahin Y et al. Efficacy of Unilateral Laminectomy for Bilateral Decompression in Lumbar Spinal Stenosis. *Turkish Neurosurgery*, 2007; 17 (2): 100-108.
6. Rahman M, Summers LE, Richter B, Mimran RI, Jacob RP. Comparison of Techniques for Decompressive Lumbar Laminectomy: the Minimally Invasive versus the “Classic” Open Approach. *Minim Invasive Neurosurg*. 2008; 51 (2): 100-105.
7. Oertel MF, Ryang YM, Korinth MC, Gilsbach JM, Rohde V. Long-term results of microsurgical treatment of lumbar spinal stenosis by unilateral laminotomy for bilateral decompression. *Neurosurgery*, 2007; 59 (6): 1264-9.
8. Airaksinen O, Herno A, Kaukanen E, Saari T, Sihvonen T, Suomalainen O. Density of lumbar muscles 4 years after decompressive spinal surgery. *Eur Spine J*. 1996; 5 (3): 193-7.
9. Weiner BK, Walker M, Brower RS, McCulloch JA. Microdecompression for lumbar spinal canal stenosis. *Spine*, 1999; 24 (21): 2268-72.
10. Fox MW, Onofrio BM, Hanssen AD. Clinical outcomes and radiological instability following decompressive lumbar laminectomy for degenerative spinal stenosis: a comparison of patients undergoing concomitant arthrodesis versus decompression alone. *J Neurosurg*. 1996; 85 (5): 793-802.
11. Johnsson KE, Willner S, Johnsson K. Postoperative instability after decompression for lumbar spinal stenosis. *Spine*, 1986; 11 (2): 107-10.
12. Kleeman TJ, Hiscoe AC, Berg EE. Patient outcomes after minimally destabilizing lumbar stenosis decompression: the “Port – Hole” technique. *Spine*, 2000; 25 (7): 865-70.
13. Nakai O, Ookawa A, Yamaura I. Long-term roentgenographic and functional changes in patients who were treated with wide fenestration for central lumbar stenosis. *J Bone Joint Surg Am*. 1991; 73 (8): 1184-91.
14. Tuite GF, Doran SE, Stern JD, McGillicuddy JE, Pappadopoulos SM, Lundquist CA et al. Outcome after laminectomy for lumbar spinal stenosis. Part II: Radiographic changes and clinical correlations. *J Neurosurg*. 1994; 81 (5): 707-15.
15. Weiner BK, Walker M, Brower RS, McCulloch JA. Microdecompression for lumbar spinal canal stenosis. *Spine*, 1999; 24 (21): 2268-72.
16. Deyo RA, Nachemson A, Mirza SK. Spinal – fusion surgery – the case for restraint. *N Engl J Med*. 2004; 350 (7): 722-6.
17. Lipson SJ. Spinal – fusion surgery-advances and concerns. *N Engl J Med*. 2004; 350 (7): 643-4.
18. Turner JA, Ersek M, Herron L, Deyo R. Surgery for lumbar spinal stenosis. Attempted meta-analysis of the literature. *Spine*, 1992; 17 (1): 1-8.
19. Fredman B, Arinzon Z, Zohar E, Shabat S, Jedeikin R, Fidelman ZG, et al. Observations on the safety and efficacy of surgical decompression for lumbar spinal stenosis in geriatric patients. *Eur Spine. J*. 2002; 11: 571-4.
20. Herno A, Airaksinen O, Saari T, Luukkonen M. Lumbar spinal stenosis : a matched-pair study of operated and non-operated patients. *Br J Neurosurg*. 1996; 10: 461-5.
21. Katz JN, Lipson SJ, Brick GW, Grobler LJ, Weinstein JN, Fossel AH, et al. Clinical correlates of patient satisfaction after laminectomy for degenerative lumbar spinal stenosis. *Spine*, 1995; 20: 1155-60.
22. Shabat S, Leitner Y, Nyska M, Berner Y, Fredman B, Gepstein R. Surgical treatment of lumbar spinal stenosis in patients aged 65 years and older. *Arch Gerontol Geriatr*. 2002; 35: 143-52.
23. Mariconda M, Zanforlino G, Celestino GA, Branca-leone S, Fava R, Minano C. Factors influencing the outcome of degenerative lumbar spinal stenosis. *J Spinal Disord*. 2000; 13: 131-7.
24. Okuyama K, Abe E, Suzuki T, Tamura Y, Chiba M, Sato K. Influence of bone mineral density on pedicle screw fixation: a study of pedicle screw fixation augmenting posterior lumbar interbody fusion in elderly patients. *Spine J*. 2001; 1: 402-7.
25. Iwamoto J, Takeda T. Effect of surgical treatment on physical activity and bone resorption in patients with neurogenic intermittent claudication. *J Orthop Sci*. 2001; 7: 84-90.
26. Turner JA, Ersek M, Herron L, Deyo R. Surgery for lumbar spinal stenosis. Attempted meta-analysis of the literature. *Spine*, 1992; 17 (1): 1-8.
27. Fox MW, Onofrio BM, Hanssen AD. Clinical outcomes and radiological instability following decompressive lumbar laminectomy for degenerative spinal stenosis: a comparison of patients undergoing concomitant arthrodesis versus decompression alone. *J Neurosurg*. 1996; 85 (5): 793-802.

28. Johnsson KE, Willner S, Johnsson K. Postoperative instability after decompression for lumbar spinal stenosis. *Spine*, 1986; 11 (2): 107–10.
29. Mullin BB, Rea GL, Irsik R, Catton M, Miner ME. The effect of postlaminectomy spinal instability on the outcome of lumbar spinal stenosis patients. *J Spinal Disord*. 1996; 9 (2): 107–16.
30. Tuite GF, Doran SE, Stern JD, McGillicuddy JE, Papadopoulos SM, Lundquist CA, et al. Outcome after laminectomy for lumbar spinal stenosis. Part II: Radiographic changes and clinical correlations. *J Neurosurg*. 1994; 81 (5): 707–15.
31. Detwiler PW, Spetzler CB, Taylor SB, Crawford NR, Porter RW, Sonntag VK. Biomechanical comparison of facet – sparing laminectomy and Christmas tree laminectomy. *J Neurosurg*. 2003; 99 (2): 214–20.
32. Quint U, Wilke HJ, Loer F, Claes L. Laminectomy and functional impairment of the lumbar spine: the importance of muscle forces in flexible and rigid instrumented stabilization – a biomechanical study in vitro. *Eur Spine J*. 1998; 7 (3): 229–38.
33. Katz JN, Lipson SJ, Lew RA, Grobler LJ, Weinstein JN, Brick GW, et al. Lumbar laminectomy alone or with instrumented or noninstrumented arthrodesis in degenerative lumbar spinal stenosis. Patient selection, costs, and surgical outcomes. *Spine*, 1997; 22 (10): 1123–31.
34. Korovessis P, Papazisis Z, Koureas G, Lambiris E. Rigid, semirigid versus dynamic instrumentation for degenerative lumbar spinal stenosis: a correlative radiological and clinical analysis of short-term results. *Spine*, 2004; 29 (7): 735–42.
35. Weiner BK, Walker M, Brower RS, McCulloch JA. Microdecompression for lumbar spinal canal stenosis. *Spine*, 1999; 24 (21): 2268–72.
36. Mariconda M, Fava R, Gatto A, Longo C, Milano C. Unilateral laminectomy for bilateral decompression of lumbar spinal stenosis: a prospective comparative study with conservatively treated patients. *J Spinal Disord Tech*. 2002; 15 (1): 39–46.
37. Spetzler U, Bertalanffy H, Reinges MH, Gilsbach JM. Unilateral laminotomy for bilateral decompression of lumbar spinal stenosis. Part II: Clinical experiences. *Acta Neurochir*. 1997; 139 (5): 397–403.
38. Thome C, Zevgaridis D, Leheta O, Bazner H, Pockler-Schoniger C, Wöhrle J, et al. Outcome after less – invasive decompression of lumbar spinal stenosis: a randomized comparison of unilateral laminotomy, bilateral laminotomy, and laminectomy. *J Neurosurg Spine*, 2005; 3 (2): 129–41.
39. Ji YC, Kim YB, Hwang SN, Park SW, Kwon JT, Min BK. Efficacy of Unilateral Laminectomy for Bilateral Decompression in Elderly Lumbar Spinal Stenosis. *J Korean Neurosurg Soc*. 2005; 37: 410-5.
40. Okuyama K, Abe E, Suzuki T, Tamura Y, Chiba M, Sato K. Influence of bone mineral density on pedicle screw fixation: a study of pedicle screw fixation augmenting posterior lumbar interbody fusion in elderly patients. *Spine J*. 2001; 1 (6): 402-7.
41. Hurri H, Slati P, Soini J, Tallroth K, Alaranta H, Laine T, et al. Lumbar spinal stenosis: assessment of long-term outcome 12 years after operative and conservative management. *J Spin Disor*. 1998; 11 (2): 110–5.
42. Mayer TG, Vanharanta H, Gatchel RJ, Mooney V, Barnes D, Judge L, et al. Comparison of CT scan muscle measurements and isokinetic trunk strength in postoperative patients. *Spine*, 1989; 14 (1): 33–6.
43. See DH, Kraft GH. Electromyography in paraspinal muscles following surgery for root compression. *Arch Phys Med Rehabil*. 1975; 56 (2): 80–3.
44. Sihvonen T, Herno A, Paljarva L, Airaksinen O, Patainen J, Tapaninaho A. Local denervation atrophy of paraspinal muscles in postoperative failed back syndrome. *Spine*, 1993; 18 (5): 575–81.
45. Markwalder TM. Surgical management of neurogenic claudication in 100 patients with lumbar spinal stenosis due to degenerative spondylolisthesis. *Acta Neurochir*. 1993; 120: 136-42.
46. Pappas CTE, Sonntag VKH. Lumbar stenosis in the elderly. *Neurosurg Quart*. 1994: 102-12.
47. diPiero CG, Helm GA, Shaffrey CI, Chaddock JB, Henson SL, Malik JM et al. treatment of lumbar spinal stenosis by extensive unilateral decompression and contralateral autologous bone fusion: operative technique and results. *J Neurosurg*. 1996; 84: 166-73.
48. Verbiest H. Results of surgical treatment of idiopathic development stenosis of the lumbar vertebral canal. A review of twenty – seven years experience. *J Bone Joint Surg*. 1977; 59: 181-8.
49. Ganz JC. Lumbar spinal stenosis: postoperative results in terms of preoperative posture-related pain. *J Neurosurg*. 1990; 72: 71-4.
50. Hall S, Bartleson JD, Onofrio BM. Lumbar spinal stenosis. Clinical features, diagnostic procedures and results of surgical treatment in 68 patients. *Ann Intern Med*. 1985; 103: 271-5.
51. Herno A, Airaksinen O, Saari T. Long term results of surgical treatment of lumbar stenosis. *Spine*, 1993; 18: 1471-4.
52. Herron LD, Mangelsdorf C. Lumbar spinal stenosis: results of surgical treatment. *J Spinal Disord*. 1991; 4: 26-33.
53. Caputy AJ, Luessenhop AJ. Long term evaluation of decompressive surgery for degenerative lumbar stenosis. *J Neurosurg*. 1992; 77: 669-76.
54. Nachemson AL. Instability of the lumbar spine. Pathology, treatment and clinical evaluation *Neurosurg Clin N Am*. 1991; 2 (4): 785-90.
55. verbiest H. Lumbar spine stenosis. In: Youmans JR eds. *Neurological surgery*. Saunders, Philadelphia. 1990: 2805-55.

**AUTHORS DATA**

<b>Name</b>	<b>Post</b>	<b>Institution</b>	<b>E-mail</b>
Dr. Ikram Alam		Department of Neurosurgery, Lady Reading Hospital, Peshawar	
Dr. Wafaq Ullah			
Dr. Muhammad Idris Khan			
Dr. Mumtaz Ali			