

Case Report

Endoscopic Fenestration of an Intra-ventricular Arachnoid Cyst in a Young Male – A Rare Entity

Muhammad Assad Javed¹, Niaz Ahmad Khan², Ain-us-Saba³

¹ Department of Neurosurgery, Akbar Niazi Teaching Hospital, ²Pakistan Institute of Medical Sciences,

³Department of Oral and Maxillofacial Surgery, Islamabad Dental Hospital, Islamabad, Pakistan

ABSTRACT

Introduction: Among intracranial space-occupying lesions, arachnoid cysts compromise 1% only. Abnormal collection of cerebrospinal fluid occurs in these types of cysts leading to pressure symptoms. Developmental abnormalities of cerebrospinal structures in early fetal life lead to the primary type of arachnoid cysts, while the second type of arachnoid cyst is formed after some neurological insult like head injury, tumor, meningitis, or brain surgery. In 60 – 90% of cases, the primary type predominates and presents with pressure symptoms before the age of 20 years. The adjudged incidence is 1.4% in adults, the least frequent being intraventricular location.

Clinical Case: A 23-year-old male presented with a long-standing left-sided cranial vault headache, right-sided focal seizures, and progressive right- hemiparesis. Neurological evaluation revealed upper motor neuron signs on the right side of the body. A computerized axial tomography raised the suspicion of an arachnoid cyst for which magnetic resonance imaging was done which revealed a large intraventricular cyst of lateral ventricles causing mass effect over the ipsilateral hemisphere and mild obstructive hydrocephalous. Surgical intervention was required as per symptomology (intractable headache, seizures, and hemiparesis) and large cyst size.

Conclusion: Cerebrospinal fluid accumulation in the brain's arachnoid layer causes non-cancerous arachnoid cysts. Larger cysts may push on brain tissue and cause neurological difficulties. MRI may diagnose arachnoid cysts, and treatment options include cystoperitoneal shunt, craniotomy, and neuro-endoscopic fenestration, the least invasive. Cyst size and location determine therapy. In this example, endoscopic treatment reduced symptoms and consequences.

Keywords: Arachnoid cyst, Lateral Ventricles, Endoscopic third ventriculostomy/Fenestration.

Corresponding Author: Muhammad Assad Javed
Department of Neurosurgery, Akbar Niazi Teaching Hospital
Islamabad, Pakistan
Email: asad.amc@gmail.com

Date of Acceptance: 25-03-2023
Date of Online Publishing: 31-03-2023
Date of Print: 31-03-2023

DOI: 10.36552/pjns.v27i1.781

Date of Submission: 4-11-2022
Date of Revision: 20-03-2023

INTRODUCTION

Arachnoid cysts are fluid-filled sacs, mostly collections of abnormal amounts of cerebrospinal fluid. These are located between the brain/spinal cord and the arachnoid membrane. The cysts which are congenital (present at birth) are called primary arachnoid cysts, due to developmental abnormality in the early weeks of gestation. Secondary arachnoid cysts are usually not common, and these are secondary to head injury, tumors, meningitis, or complication of some brain surgery.¹

Generally, incidental findings on imaging and identified before 20 years, from 60-90% of cases are below 16%.² The estimated prevalence is 1.4% in adults and 2.6% in children.³ Frequent sites in adults comprise the Sylvian fissure (34 – 45%), retro cerebellar fissure (20 – 33%), and convexity of cerebral hemispheres (14 – 20%), the least frequent being intraventricular (< 1.0%).⁴

Most of the cysts are asymptomatic requiring close observation with follow-up imaging to monitor cyst size. Surgical intervention is indicated in symptomatic patients, in those with increasing cyst size, and in those with secondary effects/complications. Recent advancements in endoscopic procedures led to better outcomes and fewer procedure-associated complications.

CLINICAL CASE

A 23-year-old gentleman, no previous co-morbid; Presented with a long-standing history of left-sided cranial vault headache, right focal seizures, and right-hemiparesis.

On neurological examination, the patient is alert, conscious, and oriented with no cranial nerve palsy. However upper motor neuron signs on the right side of the body without sensory or cerebellar deficits. Power was 4/5 on right with a positive cortical drift sign and right upgoing planter. Plain computed tomography of the skull was done initially. To ascertain the above-mentioned findings, magnetic resonance imaging

with Diffusion-weighted image (DWI) and Apparent Diffusion Coefficient (ADC) was performed to differentiate an arachnoid cyst from the dermoid cyst. The arachnoid cyst appears white on DWI, whereas the dermoid cyst appears black. In our case, MRI revealed a large intraventricular arachnoid cyst with a mass effect in the left parietal region with mild

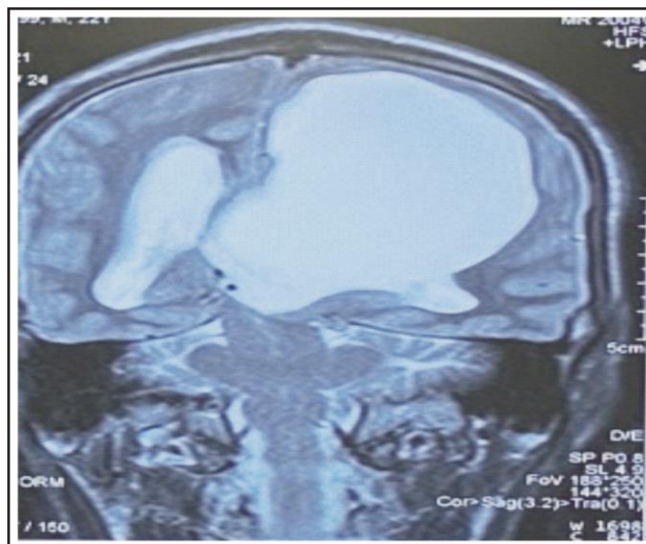


Figure 1: MRI Coronal Cuts Showing Left Parietal Large AC (scan included with patient consent).

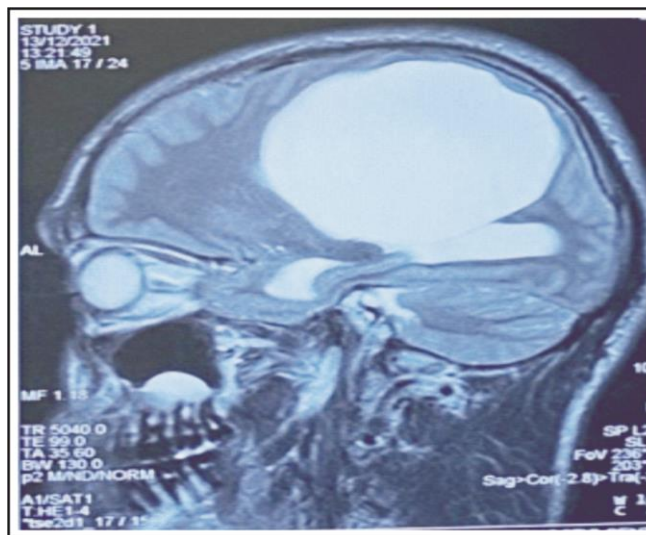


Figure 2: MRI Sagittal Cuts Showing Thin Cyst Wall Separating Cyst from Temporal Horn (scan included with patient consent).

ventriculomegaly.

As the patient was symptomatic having intractable headaches, seizures, and hemiparesis surgical intervention was indicated. We performed endoscopic cystoventricular fenestration with THELOTTA system with bipolar cauterization and Fogarty catheter into the temporal horn of the lateral ventricle as a procedure because of a better outcome and

lesser complications. The patient was discharged in satisfactory condition with improved power and neuro deficit. Follow-up MRI images showed a progressive decrease in cyst size, the stoma was functional and the CSF flow was intact with symptomatic relief, consent was taken from the patient for publication of MRI scans.

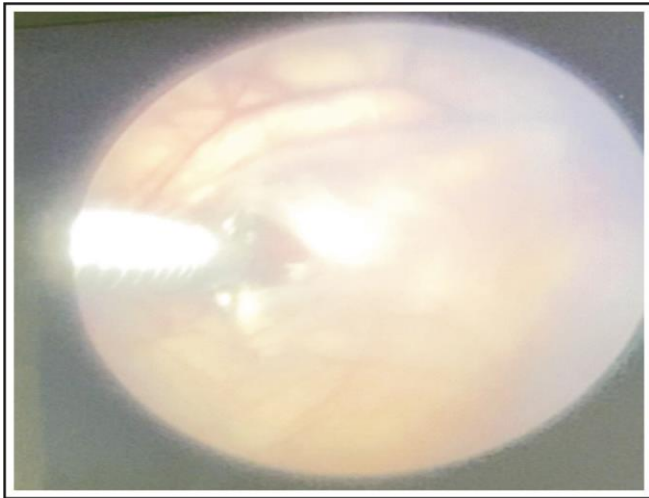


Figure 4: Endoscopic View of Fenestration of Cyst into Temporal Horn (picture included with patient consent).

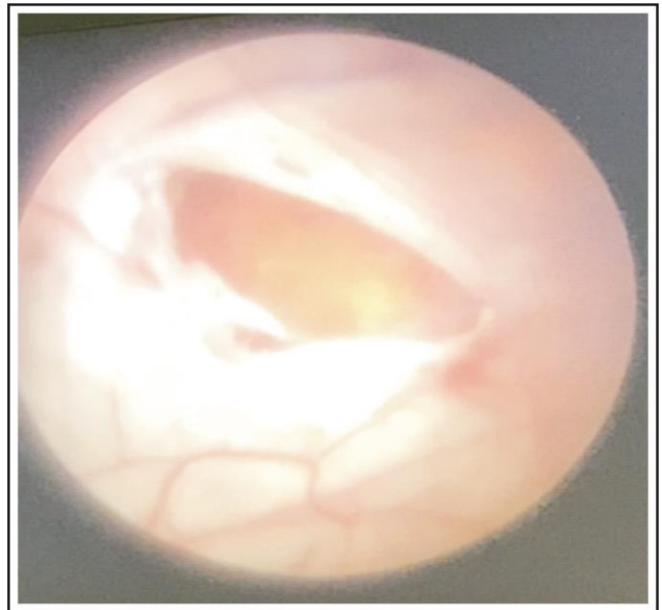


Figure 5: Endoscopic View of Stoma between Cyst and Temporal Horn (picture included with patient consent).

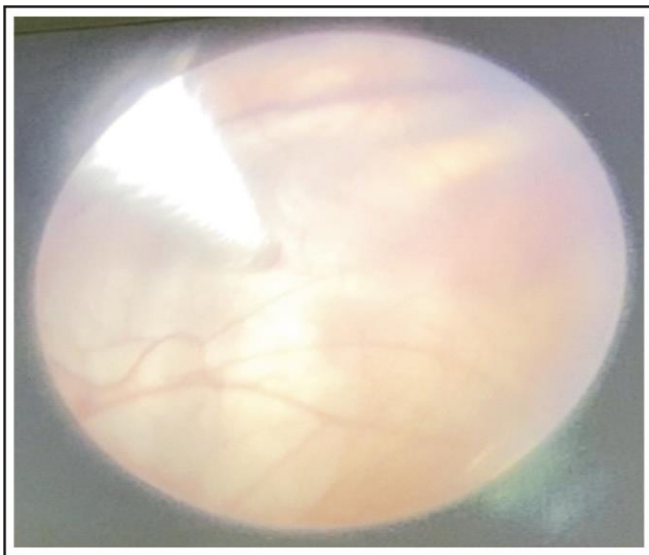


Figure 3: Endoscopic View of Fenestration of Cyst into Temporal Horn (picture included with patient consent).

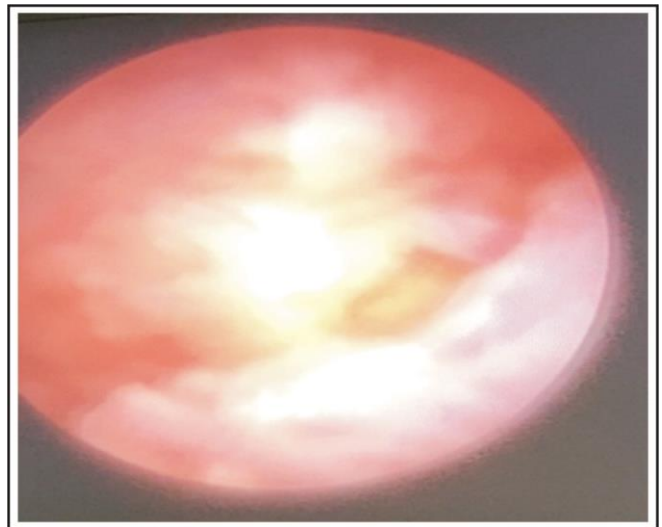

Figure 6: Endoscopic View of Choroid Plexus in Temporal Horn of Lateral Ventricle (picture included with patient consent).

DISCUSSION

The arachnoid cysts are benign. This type of cyst has an arachnoid cell wall filled with cerebrospinal fluid in excessive amounts.⁵ There are two established theories about the origin of primary cysts. First is the arachnoid splitting theory, suggesting the break apart of the arachnoid layer. Which is gradually filled with CSF leading to cyst formation. The second theory is the 'subarachnoid cyst theory' in which agenesis of the temporal lobe is the main causative event.⁷ Within the ventricles there is no physiological presence of arachnoids explained by *Yates and Enzmann*, the origin of CSF in ventricular cysts is from vascular mesenchyme. The mechanism is that the cyst invaginates the surrounding tissue of the brain from where it gets its covering from the glial tissue.⁸ According to *Nakase et al.*, its origin is from the arachnoid layer and its surrounding mesenchyme (vascular) layer through a choroidal fissure.⁹ The signs and symptoms of arachnoid cysts are different according to their location and size. Small cysts are usually asymptomatic and only require observation and no surgery. However, larger cysts can have neurological symptoms due to the compression effect on neurovascular structures. In 66% of cases, the patient presents with Headaches.¹⁰⁻¹¹ The patient usually has other symptoms like dizziness, nausea, vomiting, mental status, and mood changes. Other severe symptoms may include ataxia, seizures, and hearing loss.¹² In 1970, arachnoid cysts were suspected when patients presented symptoms. The only way to diagnose it was by the presence of a space-occupying lesion, which was confirmed with a cerebral angiography or pneumoencephalogram.¹³ The current advanced techniques like computed tomography and magnetic resonance imaging (MRI) are the most widely used methods for diagnosis. Cerebral Angiography can detect the presence of the cyst and its complications, but the only limitation of this technique is that the image cannot be modified with the use of a contrast medium. MRI

technique is better as it leads to a definitive diagnosis. It is a tool for the evaluation of arachnoid cysts, to delimit them concerning the surrounding structures.¹⁴⁻¹⁵ There are three procedures for its treatment such as cystoperitoneal shunt, craniotomy, and neuro-endoscopic fenestration. The shunt procedure is simple but may acquire complications like infection, shunt blockage, low intracranial pressure, and intracranial hemorrhage. The second one needs a larger incision to be made and the risks of surgery. The third procedure is the least invasive and therefore better one as it causes fewer serious complications. It has limitations as in the case of large cysts there is difficulty in delimiting these and, in the case of vascular lesions, the loss of clear vision.¹⁶ In neuro-endoscopy, imaging techniques are used to identify an area adjoining the cystic wall and ventricular ependyma. This in-between area is used to drain the cyst. One-centimeter area of the cystic wall is opened to prevent the closure of the stroma.¹⁸ This is debatable and more research is required to prove the worth of the fenestration technique through the endoscope. Jung Won Choi et al, indicated that this technique leads to more surgical complications.¹⁷ But other studies suggest that neuro-endoscopic shunt is a better technique than craniotomy and shunting, with fewer surgical complications.¹⁹⁻²⁰ While it was indicated by other observations that endoscopic procedure is successful in 71 – 81% of cases.¹⁹ In cases associated with larger spaces like hydrocephalus, the endoscopic approach is more practical as well as successful. The location of the arachnoid cyst is crucial for the better selection of the technique to approach it. Better outcomes of neuro endoscopic procedures are found to be when the cyst is supra-seller. The microsurgery procedure is adopted in cysts located in the middle fossa as compared to endoscopic surgery.²¹ We adopted the endoscopic approach in our case due to lesser pre-op/post-op complications and better outcomes. The Post-op

patient was vitally and clinically stable with improvement in his symptoms.

CONCLUSION

Arachnoid cysts are non-cancerous and are caused by an excess of cerebrospinal fluid accumulating in the arachnoid layer of the brain. Symptoms can vary depending on the size and location of the cyst, with larger cysts potentially causing neurological issues due to pressure on brain tissue. Advanced imaging techniques such as MRI are useful in diagnosing arachnoid cysts, and treatment options include cystoperitoneal shunt, craniotomy, and neuro-endoscopic fenestration, with the last being the least invasive. The treatment method used depends on the size and location of the cyst. In the presented case, the endoscopic approach was chosen, resulting in improved symptoms and fewer complications. Further research is necessary to determine the effectiveness of the neuro-endoscopic fenestration technique compared to other treatments.

REFERENCES

1. Arachnoid cysts. National Institute of Neurological Disorders and Stroke. U.S. Department of Health and Human Services; Feb 2023.
2. Hall S, Smedley A, Rae S, Mathad N, Waters R, Chakraborty A, Sparrow O, Tsitouras V. Clinical and radiological outcomes following surgical treatment for intra-cranial arachnoid cysts. *Clinical Neurology and Neurosurgery*, 2019; 177: 42-6.
3. Mustansir F, Bashir S, Darbar A. Management of Arachnoid Cysts: A Comprehensive Review. *Cureus*, 2018; 10 (4).
4. Panigrahi M, Patel C, Chandrasekhar YB, Vooturi S. Endoscopic Management of Lateral Ventricle Arachnoid Cysts—Case Series with Proposed Classification. *World Neurosurgery*, 2022; 164: 106-13.
5. Alexander Muacevic and John R Adler. Management of Arachnoid Cysts: A Comprehensive Review. *Cureus*. 2018; 10 (4): e2458.
6. Jafrani R, Raskin JS, Kaufman A, Lam S. Intracranial arachnoid cysts: Pediatric neurosurgery update. *Surgical Neurology International*, 2019; 10. PMID: PMC6383341.
7. Starkman SP, Brown TC, Linell EA: Cerebral arachnoid cyst. *J Neuropathol Exp Neurol*. 1958; 17: 484500.
8. Yates A, Enzman D. An intraventricular arachnoid cyst. *J Comp Assist Tomogr*. 1979; 3: 697700.
9. Nakase H, Hisanaga M, Hashimoto S, Imanishi M, Utsumi S. Intraventricular arachnoid cyst. Report of two cases. *J Neurosurg*. 1988; 68: 482-6.
10. Carbone J, Sadasivan AP. Intracranial arachnoid cysts: Review of natural history and proposed treatment algorithm. *Surgical Neurology International*, 2021: 12.
11. Mustansir F, Bashir S, Darbar A. Management of arachnoid cysts: a comprehensive review. *Cureus*, 2018; 10 (4).
12. Weber F. The prevalence of intracranial arachnoid cysts. In *Arachnoid Cysts*, 2018 Jan 1: (pp. 95-100).
13. Franco LJ, Chaparro FS, Méndez NB, Ucedo OM. Quistearacnoideo intraventricular asintomático: reporte de un caso. *Anales de la Facultad de Ciencias Médicas (Asunción)*, 2020; 53 (3): 173-6.
14. Karnazes AC, Kei J, Le MV. Image Diagnosis: Arachnoid Cyst. *The Permanente Journal*, 2015; 19 (2).
15. Logan C, Asadi H, Kok HK, Looby S, O'Hare A, Thornton J, et al. Arachnoid cysts – common and uncommon clinical presentations and radiological features. *J Neuroimaging Psychiatry Neurol*. 2016; 1 (2): 79-84.
16. Qin B, Gao L, Hu J, Wang L, Chen G. Intracerebral hematoma after endoscopic fenestration of an arachnoid cyst. *Medicine (Baltimore)*, 2018; 97 (44).
17. Stricter indications are recommended for fenestration surgery in intracranial arachnoid cysts of children. Choi JW, Lee JY, Phi JH, Kim SK, Wang KC. *Childs Nerv Sys*. 2015; 31: 77-86.
18. Mustansir F, Bashir S, Darbar A. Management of arachnoid cysts: a comprehensive review. *Cureus*, 2018 Apr. 10; 10 (4).
19. Lee YH, Kwon YS, Yang KH. Multiloculated hydrocephalus: Open craniotomy or endoscopy?

- Journal of Korean Neurosurgical Society, 2017; 60 (3): 301-5.
20. André A, Zérah M, Roujeau T, Brunelle F, Blauwblomme T, Puget S, Bourgeois M, Sainte-Rose C, Ville Y, Di Rocco F. Suprasellar arachnoid cysts: toward a new simple classification based on prognosis and treatment modality. *Neurosurgery*, 2016; 78 (3): 370-80.
21. Azab WA, Almanabri M, Yosef W. Endoscopic treatment of middle fossa arachnoid cysts. *Acta Neurochirurgica*. 2017; 159: 2313-7.

Additional Information

Disclosures: Authors report no conflict of interest.

Ethical Review Board Approval: The study conformed to the ethical review board requirements.

Human Subjects: Consent was obtained by all patients/participants in this study.

Conflicts of Interest: In compliance with the ICMJE uniform disclosure form, all authors declare the following:

Financial Relationships: All authors have declared that they have no financial relationships at present or within the previous three years with any organizations that might have an interest in the submitted work.

Other Relationships: All authors have declared that there are no other relationships or activities that could appear to have influenced the submitted work.

AUTHORS CONTRIBUTIONS

Sr.#	Author's Full Name	Intellectual Contribution to Paper in Terms of:
1.	Muhammad Asad Javed	1. Study design, data collection, calculations, and methodology.
2.	Niaz Ahmed Khan	2. Paper writing, Literature review, and referencing.
3.	Ain Us Saba	4. Analysis of data and interpretation of results.
4.	Muhammad Asad Javed	6. Editing and quality insurer.