

The Clinical Presentation and Management of Brain Abscess

SARFARAZ KHAN, MUHAMMAD ANWAR, SHAHID NAWAZ

Department of Neurosurgery, Lahore General Hospital, Lahore
and Khyber Teaching Hospital, Peshawar

ABSTRACT

Introduction: It has been reported to account for 1 – 2% and up to 8% of all intracranial space-occupying lesions in patients in developed and developing countries respectively. Bacteria can invade the brain by direct spread or through hematogenous seedling. Delayed surgical drainage has high morbidity and mortality. The diagnosis of a brain abscess is made with clinical features and investigations.

Objective: To determine the frequency of clinical presentations, causative pathogens and their antibiotic sensitivity in patients with brain abscess.

Results: The mean SD for age was 22.90 ± 14.0 years, the age range from 3 – 45 years. Male to female ratio was 3:1. The most common signs and symptoms of brain abscess were headache 32 (80%). The common predisposing factor for the formation of brain abscess was ear discharge which is 8 (20%) patients.

Conclusion: It is concluded that the awareness of predisposing factors, early recognition of clinical features and understanding of the prevalent microbial profile is imperative for better management of children and adults with brain abscess.

Keywords: Brain abscess, Etiological factors, Clinical features, Burr hole aspiration, Frontal brain abscess.

INTRODUCTION

Brain abscess is defined as a purulent infection of brain parenchyma that acts as mass lesion.¹ It can also be defined as a localized suppurative process within the brain parenchyma caused by a wide variety of bacteria, fungi and parasites. It has been reported to account for 1 – 2% and up to 8% of all intracranial space – occupying lesions in patients in developed and developing countries respectively.²

Although the western literature shows that brain abscess is an uncommon intracranial infection, rare and serious life threatening infection especially in children^{3,4,5} but still it is common in Pakistan and other developing countries.⁶ It is caused by intracranial inflammation with subsequent abscess formation. In at least 15% of cases the source of the infection is unknown (cryptogenic). Infection may enter the intracranial compartment directly or indirectly. About one third of these patients are suffering from chronic otitis media and referred from ENT department.⁷ Brain abs-

cess can arise as a complication of a variety of generalized infections, immunocompromized state, coronary heart disease (CHD) e.g. valvular defects, fallot's tetralogy, trauma or surgery. Bacteria can invade the brain by direct spread or through haematogenous seedling.⁸ It is a serious infection with poor outcome if diagnosed late. Delayed surgical drainage has high morbidity and mortality.⁹

Brain abscess is a mass of immune cells, pus and other material due to a bacterial or fungal infection. It commonly occur when bacteria or fungi infect part of the brain. Inflammation develops in response. Infected brain cells, white blood cells, and live dead microorganisms collect in a limited area of the brain. This area becomes enclosed by a membrane that forms around it and creates a mass.¹⁰ Bacterial abscess may be misdiagnosed as inflammation caused by other granulomatous diseases or even as necrotic tumors.¹¹

The diagnosis of a brain abscess is made with clinical features and investigations. The symptoms may be

sudden or gradual onset including headache, vomiting, fits, fever, focal deficit, cranial nerve palsies and in some cases papilloedema may be positive. During the physical examination clinician should obtain a complete medical history, family history, past medical history, socioeconomic history etc. Examination of ear for ear discharge, any evidence of sinusitis or cardiac murmur is sought out. Diagnostic tests will be performed to confirm the diagnosis of brain abscess like blood count, urine, X-ray, computed tomography scan (CT scan) and magnetic resonance imaging (MRI).¹²

In most of the cases computed tomography scan (CT scan) brain (plain and contrast) is the investigation of choice for the diagnosis of brain abscess. In doubtful cases MRI brain is the best investigation for differentiating it from other ring enhancing lesion like glioma, metastasis, resolving intracerebral haematoma, infarct, arachnoid cyst and hydatid cyst etc.

Treatment of brain abscess is still a subject of controversy.¹³ Despite advances in surgical techniques in the management of the brain abscess, long—term antibiotics are very crucial to eliminate the infection.¹⁴ The surgical procedure includes craniotomy with complete or partial excision of abscess wall^{15,16} burr hole aspiration of pus with or without insertion of a drain, stereotactic aspiration, ultrasound – guided aspiration, endoscopic aspiration and stereotactic endoscopic aspiration are different therapeutic approaches. Among all above procedures antibiotics either alone and as adjuvant to surgical procedure also given.¹⁷

AIMS AND OBJECTIVES

To determine the clinical presentations and causative pathogens including anaerobes along with their antibiotic sensitivity in patients with brain abscess.

MATERIAL AND METHODS

This case series study include 40 patients who admitted in the Department of Neurosurgery at Lahore General Hospital W.E.F 5/6/2009 to 5/12/2009 (6 months duration).

All patients were examined and investigated routinely to confirm their diagnosis. A thorough physical examination was done at the time of admission. The demographic information's were recorded. All admitted patients were followed up from the admission time to discharge. All the procedures were carried out under local anaesthesia or general anaesthesia. Postoperative follow up varies from a minimum of one month to one

year. The predisposing factor, clinical presentation and culture were obtained in pre designed proforma.

Amoebic brain abscess (toxoplasma) and Tuberculous brain abscess patients were excluded as they act confounders and make the study results biased.

Ethical Consideration

The study was considered after approval by the Ethical Committee of PGMI, Written informed consent were taken from all patients/relative after explaining to them the objective of the study.

RESULTS

Age Incidence

Total 40 patients of brain abscess were divided in five age groups. Out of 40 patients most of the patients 12 (30%) were in age group between 1 – 10 years, 11 (27.5%) were between 11 – 20 year, and 6 (15%) patients were between 21 – 30 years. Only 7 (17.5%) patients were between 31 – 40 years while 4 (10%) patients were > 40 years of age. The mean age was 22.90 ± 14.0 year.

Sex Incidence

There were 30 (75%) male and 10 (25%) female patients. Thus the male to female ratio was 3:1.

Clinical Features

Predisposing factors were ear discharge head injuries followed by congenital heart disease (Fig. 1).

Following were the signs and symptoms, at the time of admission in the hospital. Headache was the most common symptom, it was found in 32 (80%) of patients. The most common sign was papilloedema in 29 (72.5%) cases (Table 1).

Pathogens

Temporal brain abscess and parietal brain abscesses were more common and account for 26 (65%) in our series. Posterior fossa was third common site 7(17.5%). Frontal brain abscess was in 6 (15%) and less commonly brain abscess was presented in multiple sites only in 1 (2.5%) patient.

In this series of 40 patients, the culture of pus taken from brain abscess cavity was done for both aerobic and anaerobic organisms. The cultures sensitivity results showed in, growth obtained in 18 (45%) and most of the

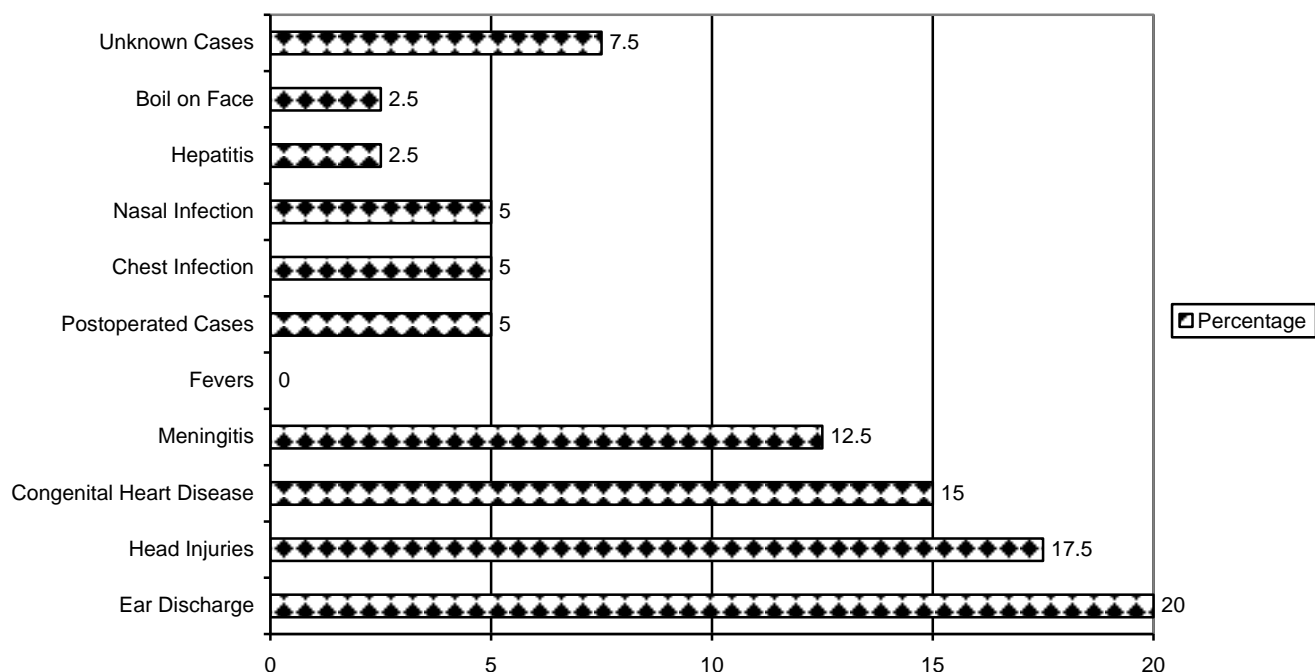


Fig. 1: Frequency of Predisposing Factor for Development of Brain Abscess (n = 40).

Table 1: Clinical Symptoms and Signs of Patients.

Symptoms and Signs	No. of Patients	Percentage
Headache	32	80.0
Papilloedema	29	72.5
Vomiting	28	70.0
Deterioration of conscious level	20	50.0
Hemiparesis	22	55.0
Neck rigidity	19	47.5
Fever	17	42.5
Convulsions	16	40.0
Discharging bone	6	15.0
Cynosis	6	15.0
Clubbing	6	15.0
Disturbed vision	4	10.0
Diplopia	4	10.0
Hemiplegia	2	5.0
Ataxia	2	5.0
Dysphasia	1	2.5
Vertigo	1	2.5

patients had no growth 22 (55%).

Staphylococcus saccharolyticus was the most common pathogens in 6 (15%) patients, staph aureus was 3 (7.5%), actinomyces pyogenes was 2 (5%), bacteroids fragilis in 2 (5%), streptococcus milleri in 2 (5%) and pseudomonas, klebsilla and staph albeus in 1 (2.5%), 1 (2.5%) respectively. No growth obtained in 22 (55%) of patients (Table 2).

Complications

There were various complications of brain abscess. Recurrence was observed in 5 (12.5%) patients. All patients were treated initially with aspiration method. There was hydrocephalus in 4 (10%) of patients. Mortality was in 2 (5%) patients. Five (12.5%) patients developed postoperative epilepsy and other complications.

The mean SD for stay in the hospital was 21.5 ± 13.83 days. The minimum duration of hospitalization was 2 days and maximum hospital stay was 50 days. Out of 40 patients 17 (42.5%) patients were discharged from the hospital after the treatment of brain abscess between 2 – 20 days. Seventeen (42.5%)

Table 2: Frequency of Aerobic and Anaerobic Pathogens of Brain Abscess ($n = 40$).

Pathogens	No. of Patients	Percentage
Anaerobic Pathogens		
Staphylococcus saccharolyticus	6	15.0
Actinomices pyogenes	2	5.0
Bacteroids fragilis	2	5.0
Streptococcus milleri	2	5.0
Aerobic Pathogens		
Staph aureus	3	7.5
Pseudomonas	1	2.5
Klebsilla	1	2.5
Staph albeus	1	2.5
No growth	22	55.0
Total	40	100.0

patients were discharged between 21 – 40 days. Only 2 (5%) patients were discharged more than 40 days.

DISCUSSION

The mean age varies, according to the inclusion criteria of various studies. A study done by Khattak that the mean age was 29.2 ± 2.3 years and age range was 3 – 65 years.¹⁸ A study done by Kutlay¹⁴ the age range was between 18 and 71 years, with a mean of 43.9 years. Another study conducted by Bhand¹⁶ the mean age was 18 years (range 05 months to 55 years). In our study the majority of 72% patients were in the first three decades of life with a mean \pm SD age 22.90 ± 14.0 which is comparable with other studies.

In the present study 30 patients (75%) were male, while 10 patients (25%) were female, with male to female ratio of 3:1. In a study carried out by Khattak there were 31 (64.59%) male patients and 17 (35.41%) were females with male to female ratio was 1.82:1.¹⁸ A study conducted by Bhand¹⁶ out of 82 patients, there were 58 were males and 24 were female, thus male to female ratio 2.4:1.

The symptoms and signs may develop slowly, over a period of 2 weeks, before they worsen to such an extent that the person needs to be admitted to the hospital or they may develop suddenly. The symptoms and

signs of a brain abscess vary depending on the part of the brain affected. A study carried out by Qasim the most common signs and symptoms were headache in 87% patients.¹⁹

In a study reported by Chun 123 cases with brain abscesses; fever, headache, altered consciousness, and hemiparesis were the most common manifestations, occurring in 58%, 55%, 50%, and 44% respectively. The presence of focal neurological findings (e.g. hemiparesis, hemisensory deficits, and aphasia) depends on the location of the abscess, and these signs were seen in approximately 63% (78/123) of cases, while 37% (45/123) had no localized signs. The presence of septic shock significantly influenced the outcome of patients. However, the presence of fever, headache, seizure, and focal neurological signs showed no statistical significance on the prognosis. The interval between onset of symptom and signs and diagnosis was of no statistical significance in this study as in a previous study.²⁰

In our study there is a long list of signs and symptoms. On presentation, patient's major symptom was headache in 80% patients. Other common symptom papilloedema and vomiting in this study. The other symptoms and signs including hemipresis (55%), deterioration of conscious level (50%), fever (42.5%), convulsions (40%), discharging bone (15%), papilloedema was the commonest sign 72% cases, cyanosis (15%), clubbing (15%), neck rigidity (47%), disturbed vision (10%), diplopia (10%) and hemiplegia (5%) which are comparable with other national and international studies. In a study reported by Zeidman the most symptoms were not due to the infection, but due to the size and location of a space – occupying lesion within the brain, and the virulence of the infecting microorganism.²¹ On the basis of the history available in the medical records, the most common clinical symptoms was headache of patients ($n = 27$; 50%) other symptoms were fever (40%) and vomiting (40%).²²

In different studies reported by various authors the patients with congenital heart disease (with a right – to – left shunt) are at risk for developing a brain abscess.²³⁻²⁶ In another study carried out by Goodkin Between 1945 and 1980, congenital heart disease and sinus or otitic infections accounted for nearly three quarters (74%; 95% confidence interval).²²

The heart disease accounts for 12.8–69.4% of all cases of brain abscesses with identified risk factors in several series, with the incidence being higher in children.²⁷ In most series of patients from developed countries, heart disease is the most commonly identified risk factor for development of brain abscess in immuno-

competent patients. The incidence of brain abscess in patients with cyanotic heart disease has been reported to range between 5 and 18.7%.²⁸ In patients with cyanotic heart disease, there is a right – to – left shunt of venous blood in the heart, bypassing the pulmonary circulation. Thus, bacteria in the bloodstream are not filtered through the pulmonary circulation, where they would normally be removed by phagocytosis. Patients with cyanotic heart disease could have low – perfusion areas in the brain due to chronic severe hypoxemia and metabolic acidosis as well as increased viscosity of blood due to secondary polycythemia. These low – perfusion areas commonly occur in the junction of gray and white matter, and they are prone to seeding by microorganisms that may be present in the bloodstream.²⁹ The hematogenous mode of spread accounts for the subcortical location as well as the multiple number of abscesses often encountered in these patients.²⁵ In comparison of other studies, the present study shown the most common predisposing factors for the development of brain abscess were ear discharge 8 (20%), second common was head injury 7 (17.5%), third common factor was congenital heart disease 6 (15%), and meningitis 5 (12.5%).

The routine investigations for a suspected case of brain abscess include examination of complete blood count, urine complete examination, x-rays skull and chest, computed tomography (CT) of brain plain and contrast and magnetic resonance imaging (MRI) of brain plain and contrast. Blood tests were carried out to check for the presence of infection. A high level of white blood cells in your blood indicates the presence of a serious infection. Old diagnostic procedures like ventriculography, pneumoencephalography and EGG were not done in our study for the diagnosis of brain abscess. Computed tomography of scan was done in some patients, it was helpful for diagnostic tool. Magnetic resonance imaging is a very good and extremely accurate method for the diagnosis of brain abscess. It obtained with diffusion weighting may be more sensitive in the differentiation of an abscess from other cystic brain lesions as well as in detection of the cerebritis stage, it may not be useful in an acutely ill patient and we do not recommend routine MR imaging for diagnosis in patients with a suspected brain abscess. In children with an open anterior fontanelle, an ultrasonogram can be used to diagnose an abscess.³⁰

Computed tomography and conventional magnetic resonance (MR) imaging are the main noninvasive modalities used to diagnose brain abscess. However, these modalities have limitations because the imaging

features of brain abscess are nonspecific and may stimulate those of cystic ring – enhancing mass lesions of varying etiologies. Proton MR spectroscopy complements conventional MR imaging by enabling better lesion characterization^{31,32} Proton MR spectroscopy is being used to differentiate brain abscess from glioblastoma multiforme. More recently, this examination has been used successfully to discriminate tuberculous from pyogenic abscesses.³³

The definitive microbiological diagnosis is made by submission of the pus from the abscess for testing with aerobic and anaerobic cultures. Fungal and tuberculous diseases can also present as a brain abscess, pus should be submitted for both acid – fast bacilli and fungal cultures.³⁴ In our study pus culture was positive in 18 (45%) of patients and mainly gram positive bacteria were isolated 22 (55%) had negative culture because most of the patients already on antibiotics. Pus culture was done in all 40 patients, the organisms isolated in our study were staphylococcus saccharolyticus 6(15%), staph aureus 3 (7.5%), actinomyces pyogenes, 2 (5%) bacteroids fragilis 2 (5%), streptococcus milleri 2 (5%) respectively.

In a study done by Atiq, *Streptococcus milleri* was the most common organism isolated from the abscess in patients with cyanotic heart disease in one series.²³ *Staphylococcus*, other *Streptococcus* spp, and *Haemophilus* have also been isolated.²⁸ In our study the staphylococcus saccharolyticus was the most common pathogens 6 (15%) and second common pathogens was staph aureus 3 (7.5%) which is comparable with other studies.

The pus immediately after being aspirated was cultured in media (BACTEC NR 730 media 16A and 17A; Becton Dickinson, Sparks, Md) to isolate the aerobic and anaerobic bacteria. The inoculated media were incubated at 37°C, and growths were monitored by using the BACTEC NR 730 system every day for 7 days. The media with positive growth values were sub-cultured on appropriate solid media and incubated both aerobically and anaerobically at 37°C. Anaerobic incubation in jars filled with a gas mixture (N₂ 80% – 90%, CO₂ 5% – 10%, H₂ 5% – 10%) was performed by using the Anoxomat system (Mart Microbiology BV, Lichtenvoorde, the Netherlands). All bacterial isolates were identified after standard biochemical tests were performed. In addition to culture sampling, Gram stains of all pus samples were routinely performed. In our study the result of culture and sensitivity growth was obtained in 45% patients and no growth found in 55% of patients because the most of the patients were already on anti-

biotics.

There are variable findings with regard to the most common bacterial pathogens responsible for brain abscess formation; however, to some extent, the variation in bacterial pathogens present in brain abscesses depends on the predisposing causes.³⁵ Thus, it is imperative to develop alternative techniques for the quick detection of anaerobes.

In a study done by Chun the treatment of brain abscess requires a combination of antimicrobials, surgical intervention, and eradication of primary infected foci. In Taiwan, initial empirical antibiotics with third – generation cephalosporins in combination with metronidazole, should be considered for the majority of abscesses cases resulting from infection with Gram – negative bacilli and streptococcal species. Different therapeutic regimens show no significant statistical differences in prognosis in other reports,²⁰ and were also of no statistical significance in this study.

In a study carried out by Chun the brain abscesses are commonly located in the parietal, frontal, or temporal lobes and multiple brain abscesses are usually the result of metastatic spread from remote primary foci, accounting for 6% to 22% of cases.²⁰

One of study carried out by Bhand burr hole aspiration was done in only 38% of the cases while excision of the capsule along with aspiration was carried out in 62% of the cases.¹⁶ The recommended duration of parenteral antibiotic therapy is 6 – 8 weeks following aspiration. In our study most of the patients 24 (60%) patients were treated burr hole aspiration which is comparable with national and international studies.

In a study carried out by Yadav¹² hospital stay ranged from 7 to 12 days with an average of 8.2 days. In our study the mostly patients hospitalized between 2 – 20 days for management of brain abscess which is comparable other national and international studies.

Since the beginning of neurosurgery, abscess of the brain has been recognized as a particularly lethal lesion. Even with the new surgical techniques and antibiotics, the mortality rate and the residual neurological deficits remain high. The main cause of mortality in most series was the rupture of brain abscess cavity into the ventricles due to delay in repeating aspiration and increase in the surrounding edema leading to abrupt herniation reported by Qasim.²² The mortality rate has decreased by nearly one third from that found in the pre-CT era.¹⁹ In another study done by Bhand¹⁶ over all mortality was 22% in this series; causes of death were septicemia, ventriculitis and pneumonia. In comparison with the present study there is mortality rate of 5% which is

comparable with other national and international studies.

CONCLUSION

- It is concluded that the awareness of predisposing factors, early recognition of clinical features and understanding of the prevalent microbial profile is imperative for better management of children and adults with brain abscess.
- The common predisposing factors, signs and symptoms were headache, congenital heart disease, ear discharge, fever, head injuries and fits.
- Particular attention should be given to the early recognition of etiological sources and proper prophylactic approach should be adopted to prevent development of brain abscess.
- MRI has now been extensively evaluated in the diagnosis of brain abscess and when available may be the imaging modality of choice. MRI in general is more sensitive than CT scan in detecting the very early changes of cerebritis, the extent of cerebral edema, the spread of inflammation into the sub-arachnoid space and ventricular system.
- The burr hole aspiration, stereotactic aspiration, neuronavigation guided excision, craniotomy and excision appears to be a safe and effective methods of surgical treatment of brain abscess. There is direct visualization of abscess cavity, completeness of aspiration can be assessed, and perioperative bleeding should be controlled.
- The earlier detection of brain abscess may reduce morbidity and mortality.
- The overall mortality was 5% in our study.

Address for Correspondence:
Dr. Sarfaraz Khattak
Room No. 14, Doctor Hostel
Lahore General Hospital, Lahore
Email: sarfarazkhattak@yahoo.com
Cell No; 0333-9714001

REFERENCES

1. Youman JR. Cranial and intracranial infections. In: Neurosurgical Surgery. Vol. 7th 3rd ed. WB Saunders, Philadelphia 2004: 3323-40.
2. Rengachary SS, Wilkin. Infections, Neurosurgery. Vol. 3, 2nd ed. McGraw Hill Book Company, New York 1996; 1928-56.

3. Kao KI, Wu KG, Chen CJ, Wu JJ, Tang RB, Chang KP, Wong TT. Brain abscesses in children: analysis of 20 cases presenting at a medical center. *J Microbiol Immunol Infect* 2008; 41: 403-7.
4. Mylonas AI, Tzerbos FH, Mihalaki M, Rologis D, Boutsikakis I. *J Craniomaxillofac Surg* 2007; 35: 63-7.
5. Brook I. Microbiology and management of brain abscess in children. *J Pediatric Neurol* 2004; 2: 125-30.
6. Anwar M. A study of etiology and management of brain abscess. Thesis (Punjab University) 1996: 1-186.
7. Ilyas M. Management of intracerebral abscess. *Pak J Neurol Surg* 2002; 6: 66-72.
8. Mole N, Diaz-Brito V, Chamadoira C, Gomes I, Amorim A. Multiple brain abscesses – a rare complication of bronchiectasis. *Rev Port Pneumol* 2009; 15: 319-24.
9. Clinical features and outcome of cerebral abscess in congenital heart disease. *J Ayub Med Coll Abbottabad* 2006; 18: 21-4.
10. Lee LA. Brain abscess. Columbia University Medical Center, New York 2007: 1-4.
11. Morais LT, Zanardi VA, Faria AV. Magnetic resonance spectroscopy in the diagnosis and etiological definition of brain bacterial abscess. *Arq Neuropsiquiatr* 2007; 65: 1144-8.
12. Yadav YR, Sinha M, Neha, Parihar NV. Endoscopic management of brain abscesses. *Neurology India*. 2008; 56: 13-6.
13. Charlottesville VA. Neurological disorders; University of Virginia Health System 2008.
14. Kutlay M, Colak A, Yildiz S, Demircan N, Akin ON. Stereotactic aspiration and antibiotic treatment combined with hyperbaric oxygen therapy in the management of bacterial brain abscesses. *Neurosurgery*. 2008; 62: (Suppl 2): 540-6.
15. Ozkaya S, Bezircioglu H, Sucu HK, Ozdemir I. Combined approach for otogenic brain abscess. *Neurol Med Chir* 2005; 45: 82-6.
16. Bhand AA. Brain abscess diagnosis and management. *J Coll Physicians Surg Pak* 2004; 14: 407-10.
17. Rosenblum S, Lopes MB, Tsanaclis AM. Neuropathology of acquired immune deficiency syndrome (AIDS). Analysis of 22 Brazilian cases. *J Neurol Sci* 1986; 76: 187-98.
18. Khattak A, Rehman R, Anayatullah, Alam W. Etiological factors of brain abscess. *J Med Sci* 2010; 18: 194-96.
19. Qasim M, Naeem ur Razaq M, Saddiqe M, Ilyas M, Khattak A. Management of supratentorial brain abscess. *IPMI* 2010; 24: 91-94.
20. Chun CH, Johnson JD, Hofstetter M, Raff MJ. Brain abscess: a study of 45 consecutive cases. *Medicine (Baltimore)* 1996; 65: 415-31.
21. Zeidman SM, Geisler FH, Olivi A. Intraventricular rupture of a purulent brain abscess: Case report. *Neurosurgery* 1995; 36: 189-93.
22. Goodkin HP, Harper MB, Pomeroy SL. Intracerebral abscess in children: historical trends at children's hospital Boston. *Pediatrics* 2004; 113: 1765-9.
23. Atiq M, Ahmed US, Allana SS, Chishti KN. Brain abscess in children. *Indian J Pediatr* 2006; 73: 401-404.
24. Bernardini GL: Diagnosis and management of brain abscess and subdural empyema. *Curr Neurol Neurosci Rep* 2004; 4: 448-456.
25. Ghafoor T, Amin MU: Multiple brain abscesses in a child with congenital cyanotic heart disease. *J Pak Med Assoc* 2006; 56: 603-605.
26. Lumbiganon P, Chaikitpinoy A: Antibiotics for brain abscesses in people with cyanotic congenital heart disease. *Cochrane Database Syst Rev* 3: CD004469, 2007.
27. Malik S, Joshi SM, Kandoth PW, Vengsarkar US. Experience with brain abscesses. *Indian Pediatr* 1994; 31: 661-66.
28. Takeshita M, Kagawa M, Yonetani H, Izawa M, Yato S, Nakanishi T. Risk factors for brain abscess in patients with congenital cyanotic heart disease. *Neurol Med Chir (Tokyo)* 1992; 32: 667-70.
29. Takeshita M, Kagawa M, Yato S, Izawa M, Onda H, Takakura K. Current treatment of brain abscess in patients with congenital cyanotic heart disease. *Neurosurgery* 1997; 41: 1270-79.
30. Bernardini G. Diagnosis and management of brain abscess and subdural empyema. *Curr Neurol Neurosci Rep* 2004; 4: 448-56.
31. Poptani H, Gupta RK, Jain VK, Roy R, Pandey R. Cystic intracranial mass lesions: possible role of in vivo MR spectroscopy in its differential diagnosis. *Magn Reson Imaging* 1995; 13: 1019-29.
32. de Louvois J. Bacteriological examination of pus from abscess of the central nervous system. *J Clin Pathol* 1998; 33: 66-71.
33. Dev R, Gupta RK, Poptani H, Roy R, Sharma S, Husain M. Role of in vivo proton magnetic resonance spectroscopy in the diagnosis and management of brain abscesses. *Neurosurgery* 1998; 42: 37-43.
34. Mohindra S, Mohindra S, Gupta R, Bakshi J, Gupta SK. Rhinocerebral mucormycosis: the disease spectrum in 27 patients. *Mycoses* 2007; 50: 290-96.
35. de Louvois J. Bacteriological examination of pus from abscesses of the central nervous system. *J Clin Pathol* 1999; 33: 66-71.